

Augmentation of Nasal Tip Projection Using the Inferior Turbinate

Review of Technique and Evaluation of Long-term Success

Michael E. Jones, MD; Richard W. Westreich, MD; William Lawson, MD, DDS

Objectives: To introduce the use of inferior turbinate bone as an alternative autograft for augmentation of nasal tip projection and to assess maintenance of nasal tip projection, bone remodeling, graft shaping, and ease of harvesting.

Methods: Thirteen consecutive patients in need of increased nasal tip projection underwent closed rhinoplasty during a prospective nonrandomized study in a university teaching hospital setting. An autologous demucosalized inferior turbinate bone graft was used as a columellar strut. Measurements of nasal tip projection were obtained using the Goode ratio. Photodocumentation and lateral soft tissue radiographs were obtained before surgery and between 30 and 38 months after surgery.

Results: In all patients, the results were as follows: (1) the inferior turbinate bone graft was easily harvested

and molded into the appropriate-sized columellar strut; (2) the immediate postoperative nasal tip projection, as measured by the Goode ratio and visual assessment, was increased; and (3) the tip projections were maintained at the 30-month follow-up examination. Paired *t* tests revealed a statistically significant difference ($P = .001$ and $P = .009$) between preoperative and both immediate and long-term measurements. Comparison of immediate postoperative radiographs with those taken 2 years later demonstrated no remarkable change in appearance of the graft.

Conclusions: The inferior turbinate bone is a viable graft for augmenting nasal tip projection. Moreover, it maintains tip projection and needs little to no remodeling. The graft is easy to harvest, prepare, and place and can be used without requiring a second operative site.

Arch Facial Plast Surg. 2008;10(1):34-37

IN MANY PTOTIC, SENILE, ETHNIC, and revision noses, columellar strut grafting is required to achieve the desired projection and rotation because of an underlying deficiency of medial crural support. Although in most primary rhinoplasties, a columellar graft is fashioned from autologous septal cartilage, there are cases in which either the septal cartilage is intrinsically weak or the quadrangular plate that is available for harvest and grafting is insufficient. This is especially true in revision cases and in cases involving ethnic noses, in which dorsal augmentation and onlay tip grafts are often simultaneously desired. In these circumstances, many surgeons will harvest additional autologous material from the auricle, rib, calvarium, or iliac crest,¹⁻⁷ while others will turn to alloplastic materials, including but not limited to expanded polytetrafluoroethylene, high-density polyethylene, and silicone.⁸⁻¹¹

The inferior turbinate offers an intranasal alternative to these options. In many ethnic noses, because of predominant airflow through the inferior meatus, concurrent inferior turbinate reduction surgery is indicated for functional airway correction. The inferior turbinate lies within the operative field and obviates the need for a second operative graft harvesting site. The inferior turbinate can be reduced with limited added patient morbidity and, when fashioned and placed properly, can provide patients with excellent long-term nasal tip support. We describe our experience with the inferior turbinate bone graft (ITBG) as well as long-term follow-up of its aesthetic benefits.

TECHNIQUE

GRAFT HARVEST AND PREPARATION

Inferior partial turbinectomy is performed in standard fashion, following de-

Author Affiliations:
Departments of Otolaryngology, Columbia-Presbyterian Medical Center, New York City, New York (Dr Jones), State University of New York, Downstate Medical Center, Brooklyn (Dr Westreich), and Mount Sinai Hospital, New York City (Dr Lawson).

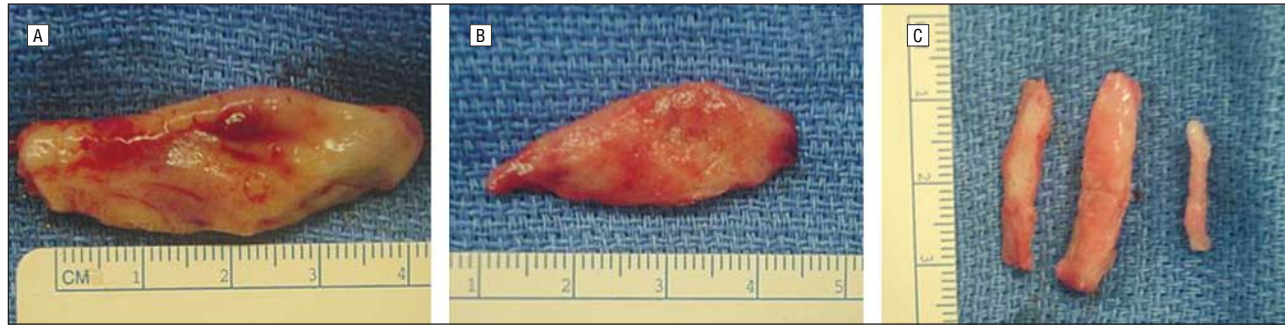

Figure 1. Preparation of inferior turbinate bone graft. A, Inferior turbinate after turbinectomy. B, Inferior turbinate after mucosa removal. C, Multiple grafts obtained from the inferior turbinate. Shaping is done with a Mayo scissor.

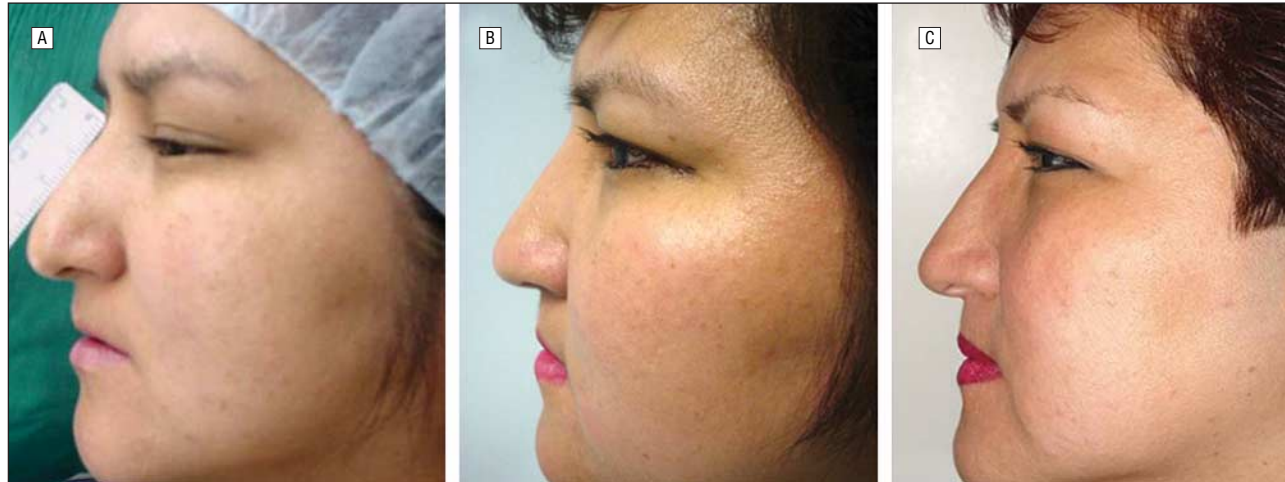


Figure 2. Photographs taken of a patient before surgery (A) and at 14 days (B) and 30 months (C) after surgery.

congestion with 0.05% neosynephrine. After careful infracture with a freer elevator, a right-angled scissor is used to resect the anterior head or two-thirds of the turbinate, including bone and soft tissue (**Figure 1A**). After careful extraction from the nose, the soft tissue covering the turbinate bone is removed using iris scissors or a No. 15 blade, taking care to avoid trauma to the turbinate bone (Figure 1B and C). The size of the implant will vary depending on the patient's degree of bony inferior turbinate hypertrophy. The graft is then shaped using a Mayo scissor. Hemostasis of the cut end of the turbinate is achieved using suction electrocautery.

PLACEMENT

Placement of the graft can be done either endonasally or using an open approach. If an endonasal approach is used, it is important for the surgeon to carry the marginal incision almost to the medial crural footplate and then to dissect the lower lateral cartilage free along its length. This allows direct placement of the strut, which will not bend significantly, and minimizes the risk of fracturing the implant. The marginal and transfixion sutures are closed with 4-0 chromic gut. The nose is then taped and cast in standard fashion. A stabilizing suture can be placed in a septal-columellar fashion. Because driving a needle through the implant risks fracture, we prefer placing the suture just posterior to the implant in the membranous septum.

PATIENT ANALYSIS

Thirteen consecutive patients in need of increased nasal tip projection underwent closed rhinoplasty with the placement of a demucosalized ITBG as a columellar strut. Photodocumentation and measurements of nasal tip projection using the Goode ratio¹² were obtained. Photographs were taken before surgery, several weeks after surgery, and 30 to 38 months after surgery (**Figure 2** and **Figure 3**). Also, lateral soft tissue radiographs were obtained 1 to 2 weeks after surgery and at the long-term follow-up visit (**Figure 4**).

RESULTS

Thirteen consecutive patients underwent closed rhinoplasty with the placement of an ITBG as a columellar strut. In all patients, nasal tip projection increased as assessed by the Goode ratio (**Table**). This change was visually confirmed by photodocumentation. Clinical evaluation after long-term follow-up demonstrated that all patients maintained their projection. Paired *t* tests showed that statistically significant ($P=.001$ and $P=.009$) increases from preoperative measurements persisted at the immediate and long-term follow-up visits. Lateral radiographs demonstrated the persistence of the osseous graft without change in size, shape, or po-

sition (Figure 4). There was no evidence of graft rejection or extrusion in any patient. No grafts required removal, and there were no hemorrhagic intranasal complications.

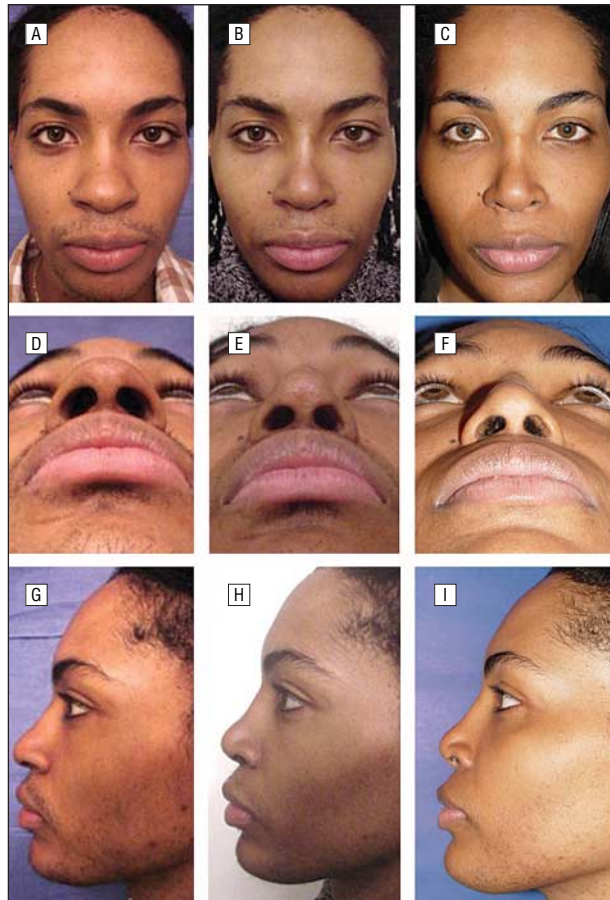


Figure 3. Photographs of a patient with a previous Silastic strut, which was revised with an inferior turbinate bone graft. The previous graft is visible and deviated (A). The patient is shown in frontal view at 14 days (B) and 36 months (C) after revision rhinoplasty with placement of an inferior turbinate bone graft. Base views are shown in D through F; lateral views, in G through I.

COMMENT

Patients who have undergone previous rhinoplasty or submucous septal resection and those who require extensive onlay grafting may not have sufficient material for creating an adequate columellar strut. These clinical scenarios often require alternative harvest locations, such as the ears or rib. This creates another operative site, additional patient preparation, increased operative time, and the potential for increased morbidity (auricular deformity, pneumothorax) at the donor site. Alloplastic material avoids several of these issues, at the expense of a higher complication rate when compared with autografts.

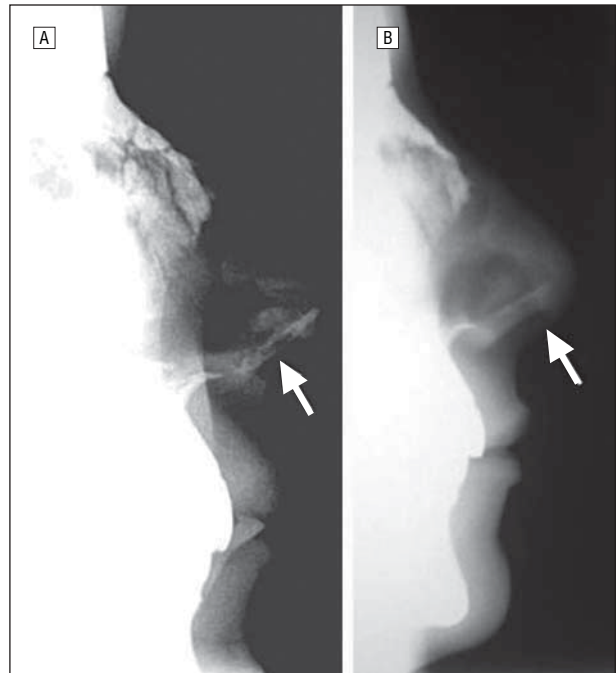


Figure 4. Lateral radiographs of patient in Figure 3 shown at 3 weeks (A) and 30 months (B) after surgery. The arrows indicate the presence of an osseous strut.

Table. Preoperative and Postoperative Goode Ratio Measurements

Patient No.	Procedure	Preoperative Goode Ratio	Postoperative Goode Ratio ^a	Long-term Goode Ratio ^b	Follow-up, mo
1	Primary rhinoplasty	0.5	0.66	0.65	38
2	Primary rhinoplasty	0.55	0.72	0.7	37
3	Revision rhinoplasty	0.45	0.65	0.6	37
4	Primary rhinoplasty	0.58	0.62	0.62	36
5	Revision rhinoplasty	0.83	0.66	0.62	36
6	Primary rhinoplasty	0.5	0.62	0.6	34
7	Revision rhinoplasty	0.5	0.6	0.58	34
8	Primary rhinoplasty	0.5	0.63	0.6	34
9	Primary rhinoplasty	0.53	0.66	0.6	33
10	Primary rhinoplasty	0.5	0.6	0.59	33
11	Primary rhinoplasty	0.45	0.6	0.58	31
12	Primary rhinoplasty	0.55	0.66	0.64	31
13	Primary rhinoplasty	0.55	0.66	0.65	30

^a $P = .001$ (paired t test).

^b $P = .009$ (paired t test).

We describe a new method for augmenting the nasal tip using autologous demucosalized inferior turbinate as a columellar strut. The ITBG has both short- and long-term advantages compared with nonseptal autologous cartilage grafts or allografts. Harvest and preparation of the ITBG require skill in turbinectomy and soft tissue techniques, which most surgeons can easily master. Placement of the graft requires little or no additional dissection. No additional operative sites or patient preparation is required. At long-term follow-up visits, we found that projection was maintained in its increased position. Lateral radiographs demonstrated survival of the implant, with no observable change.

Although there was minimal morbidity associated with the use of this graft, we report several potential disadvantages:

- Increased intraoperative and postoperative bleeding may occur from the turbinectomy, although none of our patients had any postoperative hemorrhages. Formal packing (3 × 18-inch petroleum-impregnated gauze) was used in all patients for a minimum of 48 hours.
- An osseous graft carries an increased potential for fracture, but this adverse outcome was easily avoided with careful handling and the use of a Mayo scissor for shaping.
- Harvesting of the graft can increase operative time approximately 10 minutes, which is less time than is required for harvesting auricular or costal cartilage.

During the initial perioperative period, mild increases in nasal tip stiffness were noted. However, the increases were not appreciably different from the routine changes that are seen with the use of any material as a columellar strut, and they were acceptable to our patients. No significant palpable abnormalities were noted on long-term evaluation. Patients had no subjective nasal complaints relative to the turbinectomy, nor was there any objective evidence of nasal crusting or drying.

In conclusion, the purpose of this study was to introduce the use of the interior turbinate bone as an alternative autologous graft in the augmentation of nasal tip projection. During the study, we demonstrated that the demucosalized inferior turbinate bone is a viable graft for augmentation of nasal tip projection. The ITBG maintains tip projection and requires little remodeling. It is

easy to harvest, shape, and inset, with no need for additional preparation, external incision, or additional operative site.

Accepted for Publication: June 1, 2007.

Correspondence: Richard W. Westreich, MD, Department of Otolaryngology, State University of New York, Downstate Medical Center, 144 Clinton St, Brooklyn, NY 11201 (doctor@newyorknose.com).

Author Contributions: *Study concept and design:* Jones and Lawson. *Acquisition of data:* Jones. *Analysis and interpretation of data:* Jones and Lawson. *Drafting of the manuscript:* Jones, Westreich, and Lawson. *Critical revision of the manuscript for important intellectual content:* Jones, Westreich, and Lawson. *Administrative, technical, and material support:* Jones and Westreich. *Study supervision:* Jones and Lawson.

Financial Disclosure: None reported.

REFERENCES

1. Sheen JH. Achieving more nasal tip projection by the use of a small autogenous vomer or septal cartilage graft: a preliminary report. *Plast Reconstr Surg.* 1975; 56(1):35-40.
2. Romo T III, Jablonski RD. Nasal reconstruction using split calvarial grafts. *Otolaryngol Head Neck Surg.* 1992;107(5):622-630.
3. Kim DW, Shah AR, Toriumi DM. Concentric and eccentric carved costal cartilage: a comparison of warping. *Arch Facial Plast Surg.* 2006;8(1):42-46.
4. Sarukawa S, Sugawara Y, Harii K. Cephalometric long-term follow-up of nasal augmentation using iliac bone graft. *J Craniomaxillofac Surg.* 2004;32(4):233-235.
5. Daniel RK. Rhinoplasty and rib grafts: evolving a flexible technique. *Plast Reconstr Surg.* 1994;94(5):597-611.
6. Pastorek NJ, Bustillo A, Murphy MR, Becker DG. The extended columellar strut-tip graft. *Arch Facial Plast Surg.* 2005;7(3):176-184.
7. Burm JS. Reconstruction of the nasal tip including the columella and soft triangle using a mastoid composite graft. *J Plast Reconstr Aesthet Surg.* 2006; 59(3):253-256.
8. Ham J, Miller PJ. Expanded polytetrafluoroethylene implants in rhinoplasty: literature review, operative techniques, and outcome. *Facial Plast Surg.* 2003; 19(4):331-339.
9. Lawson W, Reino AJ, Seidman D. The silicone columellar strut. *Plast Reconstr Surg.* 1996;97(5):938-943.
10. Ahn J, Honrado C, Horn C. Combined silicone and cartilage implants: augmentation rhinoplasty in Asian patients. *Arch Facial Plast Surg.* 2004;6(2):120-123.
11. Romo T III, Litner JA, Sclafani AP. Management of the severe bulbous nasal tip using porous polyethylene alloimplants. *Facial Plast Surg.* 2003;19(4):341-348.
12. McGraw-Wall B. Facial analysis. In: Bailly BJ, ed. *Head and Neck Surgery—Otolaryngology.* Philadelphia, PA: Lippincott Williams & Wilkins; 1993:2070-2083.