

Effect of Midfacial Asymmetry on Nasal Axis Deviation

Indications for Use of the Subalar Graft

Francisca Yao, MD; William Lawson, MD, DDS; Richard W. Westreich, MD

Objective: To test the hypothesis that midfacial asymmetry specifically relevant to nasal tip deviation will be reflected in the measured soft-tissue attachments of the ala to the face.

Design: Retrospective photographic analysis of 35 consecutive patients seeking functional or aesthetic nasal surgery regardless of cause.

Results: Nasal axis had a significant correlation with the alar-facial angle on base view photographs ($P < .001$) ir-

respective of cause (traumatic vs congenital). However, there was no significant correlation between alar facial angle on anteroposterior view (frontal) with nasal axis and no correlation between frontal and basal angles.

Conclusion: Soft-tissue analysis demonstrates a relationship between nasal axis deviation and lower midfacial asymmetry or hypoplasia.

Arch Facial Plast Surg. 2009;11(3):157-164

FACIAL SYMMETRY HAS TRADITIONALLY been equated with facial aesthetics, and this ideal continues today despite changing standards of beauty. The crooked, twisted, or deviated nose is a common reason for patients seeking aesthetic correction, which demonstrates the importance of the nose in facial aesthetics. Besides the obvious functional implications, the social stigma may be of concern to patients because they can be perceived as “brawlers” or “victims.” A recent study by Chatrath et al^{11(p186)} showed a correlation between the “objective measures of nasal asymmetry and subjective perception of the face as symmetric.” With a central position on the face, the nose is a key determinant of symmetry, and any deviation can cause a disturbance in facial harmony.

For patients seeking aesthetic correction of their nose, a surgeon’s awareness of facial analysis aids in the development of realistic surgical goals. Relative proportions and measurements of facial structures have been defined and are often used as guidelines for the surgical procedure. Although most of these measurements reflect ideal frontal and profile relationships, they are not always the primary focus in correcting the deviated nose.

Currently, the data regarding midfacial asymmetry in otherwise healthy individuals is scarce. Since asymmetry is often mentioned in the clinical setting, it

would seem reasonable to further quantify specific aspects germane to nasal development. Of particular interest is the contribution of facial asymmetry to nasal deviation, or the nasal axis.

The nose is a 3-dimensional structure composed of 3 basic regions: the upper rigid bony third, the middle semi-rigid cartilaginous third, and the lower mobile cartilaginous third. Subdivision and analysis of each area is critical in defining a surgical plan in the deviated nose. In the most basic sense, each region has paired lateral walls lying on a supporting foundation as well as a central structure (bony septum, cartilaginous septum, and columella/caudal septum) that is primarily responsible for maintaining stability of that region. This creates 3 distinct triangular units with a central bar.

In examining facial asymmetry and nasal deviation, it is apparent that the maxilla is the essential foundation of the entire nose. The maxilla supports all 3 regions of the nose through either a rigid abutment or intervening fibrous or fibrofatty tissue. The anterior projection of the frontal process of the maxilla provides lateral support for the nasal bones and upper lateral cartilages. The anterior maxillary wall and soft tissues underlying the alae provide the same lateral stabilization for the tip. Asymmetry in the maxilla may adversely affect the support of the nasal superstructure. Through the interconnections of the upper, middle, and lower

Author Affiliations:

Department of Otolaryngology, State University of New York, Downstate Medical Center, Brooklyn (Drs Yao and Westreich); and Department of Otolaryngology, Mount Sinai Medical Center, New York, New York (Dr Lawson).

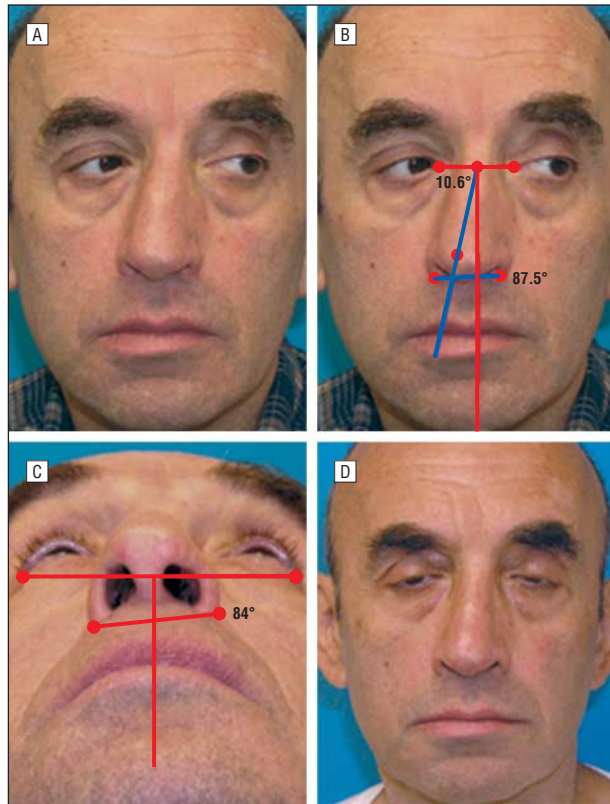


Figure 1. Persistent nasal axis deviation in a patient with previous septoplasty and no history of trauma. He had purely functional concerns without concern for cosmesis and declined formal tip surgery. Revision septoplasty, open reduction of the nasal bones with left perforating double lateral osteotomies, left midvault crushed cartilage onlay graft, and bilateral turbinoplasties were performed. The patient was functionally improved, but persistent external deviation is seen. A, B, and C, Preoperative views. D, Postoperative view.

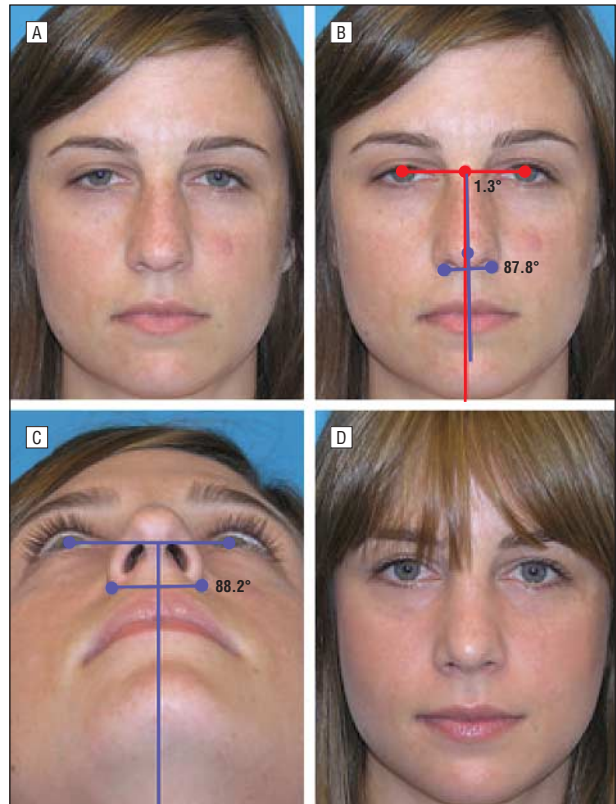


Figure 2. Representative measurements in a nontraumatic case without significant facial asymmetry before (A, B, and C) and after (D) combined functional and cosmetic endonasal rhinoplasty.

thirds, deviations may then be secondarily transmitted to adjacent regions.

Facial asymmetry may be manifest in any or all of 3 planes: vertical, horizontal, or anteroposterior. If all 3 planes are decreased volumetrically, then true hypoplasia is present, as seen in patients with cleft lip deformities, where predictable nasal deformities are seen. Variations on this theme may be present in patients with nasal deviation due to asymmetric maxillary development that falls short of true hypoplasia.

Anecdotal experience with patients who declined formal tip surgery and sought functional correction alone, where adequate nasal bone and septal correction still resulted in an improved but persistent nasal axis deviation, was the impetus for this study (**Figure 1**). We believe that deficiency in the projection of the maxilla has an effect on nasal tip deviation, which will be reflected in an overall linear angulation of the nose in relation to the face. We also believe that an uncorrected platform deficiency may be the primary cause of persistent postoperative nasal tip deviation, which secondarily pulls a mobilized septum off axis, resulting in persistent deformities after otherwise successful surgery. Establishing the specific relationships and defining particular angles that can be predictably used in preoperative assessment will provide a better understanding of nasal deviation and its

potential cause and have implications for correcting the deviated nose.

METHODS

We conducted a retrospective photographic analysis of 35 consecutive patients seeking functional or aesthetic nasal surgery. The patient population included both traumatic and nontraumatic nasal deformities. Patients younger than 18 years were excluded from the study. Preoperative photographs of the face and nose in standard anteroposterior and base views were independently reviewed by 2 of us (F.Y. and R.W.W.).

Using computer software (Adobe Photoshop 7.0; Adobe Inc, San Jose, California), the following anthropometric measurements were obtained by each author reviewing the photographs: alar-facial angle, frontal (AFF); nasal axis (NA); and alar-facial angle, base (AFB). Photographs were assessed for appropriate orientation and clarity. Photographs were then aligned on both horizontal and base views with the interpupillary line used as the horizontal meridian. Various soft-tissue landmarks were marked, including the alar attachment to the face, the nasal tip defining point, and the vertical midpoint of the face, which was defined by measuring interpupillary distance in pixels and marking the midpoint at the glabella.

The AFF was defined on anteroposterior images as the angle created by a vertical line transecting a line connecting the right and left alar attachments. The NA was also defined on anteroposterior images as the angle created between a vertical meridian starting at the midpoint of the interpupillary line and a line connecting that point with the nasal tip defining point. Finally, on base view, a line connecting the alar attachments to the face was transected by a vertical line, creating the AFB

Table 1. Descriptive Statistics and Interrater Reliability for Measurements in 35 Patients

Variable	Degrees			Interrater Reliability	
	Minimum	Maximum	Mean (SD)	Spearman Rank Correlation	Interclass Correlation
Deviation	-12.0	11.4	-1.1 (5.5)	$r = 0.99, P < .001$	$r = 0.99, P < .001$
AFB	85.5	93.0	89.7 (1.9)	$r = 0.83, P < .001$	$r = 0.85, P < .001$
AFF	78.5	96.3	90.4 (3.3)	$r = 0.83, P < .001$	$r = 0.91, P < .001$

Abbreviations: AFB, alar-facial angle, base; AFF, alar-facial angle, frontal.

(**Figure 2**). All measurements were collected on a standardized collection sheet, and relationships were analyzed by SPSS statistical software (SPSS Inc, Chicago, Illinois).² The 2 sets of data were also compared for reliability.

RESULTS

Table 1 contains statistical information for the analyzed data. The 2 independent sets of data were found to have excellent interrater reliability. Mean NA had a significant correlation with mean AFB (Spearman rank correlation, $r = 0.63, P < .001$), but there was no significant correlation between mean NA and AFF ($r = 0.01, P = .95$) or between AFB and AFF ($r = 0.09, P = .61$). In addition, after adjusting the relationship between the mean axis and AFB for cause of the deviation (traumatic vs non-traumatic), there was no significant relationship. Scatterplot analysis demonstrated an increase in linear correlation if NA deviation exceeded 5° . Sample size limitations precluded formal statistical analysis of this finding. This result was obtained by means of subjective visual assessment of increased linear configuration to the data scatterplot (**Figure 3**).

COMMENT

Correction of the congenitally or traumatically deviated nose requires a surgical plan distinct from and often more aggressive than that for standard aesthetic rhinoplasty. Discrepancies in nasal bone length, dorsal septal plate deformities, traumatic upper lateral cartilage avulsion, upper lateral cartilage malformation or alteration, and nasal tip deformities and asymmetries may all contribute to the NA deviation. This asymmetry of the nasal structures represents an inherent surgical challenge from both a functional and a cosmetic viewpoint. Many techniques have been described in correcting these deformities, including but not limited to perforating double lateral osteotomies, transverse nasal root osteotomies, high septal osteotomy, septal crossbar grafts, spreader grafts, upper lateral cartilage onlay grafts, extracorporeal septoplasty, and asymmetric nasal tip modifications with or without cartilage division and camouflage grafts.³⁻⁷ The anatomic challenges and techniques are not limited to those listed herein, and, as demonstrated in this study, midface asymmetry or hypoplasia should be considered in patients with NA deviation.

Conventional teaching in rhinoplasty has centered on cleft lip nasal deformities, in which a predictable nasal

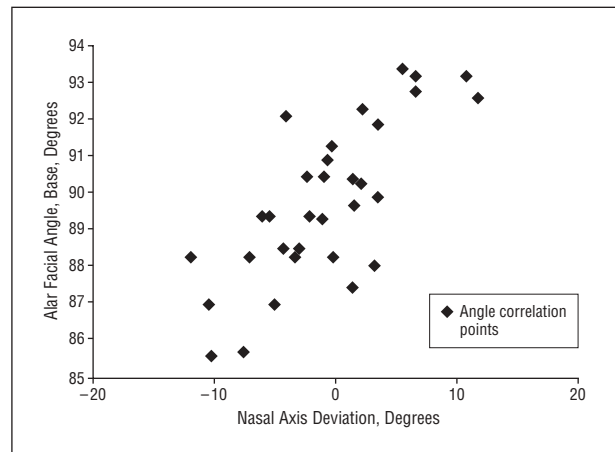


Figure 3. Scatterplot showing the relationship between the alar facial angle base and the nasal axis. Subjective visual assessment indicates an apparent increase in linear association, as there is more than 5° of axis deviation from midline.

architecture is seen. In this circumstance, true maxillary hypoplasia results in posterior, inferior, and lateral deflection of the ala's attachment to the face. Patients without cleft lip but with visibly significant facial asymmetry have often been treated by extrapolating this concept. However, our data demonstrate no significant correlation between NA and AFF. Therefore, we are able to show that patients with NA deviation and clinically perceptible facial asymmetry do not follow a specific pattern: the vertical displacement of the ala is just as likely to be superior as it is to be inferior.

Nasolabial fold depth has classically been used to screen for facial asymmetry. However, on the basis of the study findings, we do not recommend using frontal views as a means to diagnose facial asymmetry relevant to the deviated nose. Rather, the base views should be closely inspected and considered when a surgical plan is formulated.

It is intriguing that this relationship between maxillary deficiency and nasal tip deviation holds true in both the congenitally and traumatically deviated noses. We saw no differences in the association of NA deviation and AFB when stratified by patient history. This finding led us to question patients more thoroughly about their actual pre-injury appearance, often uncovering a history of previous nasal deviation. It is likely that many individuals have traumatic accentuation of a preexisting deformity, which is now noticed as continued inspection of the nose occurs after the injury. In addition, many patients relate an

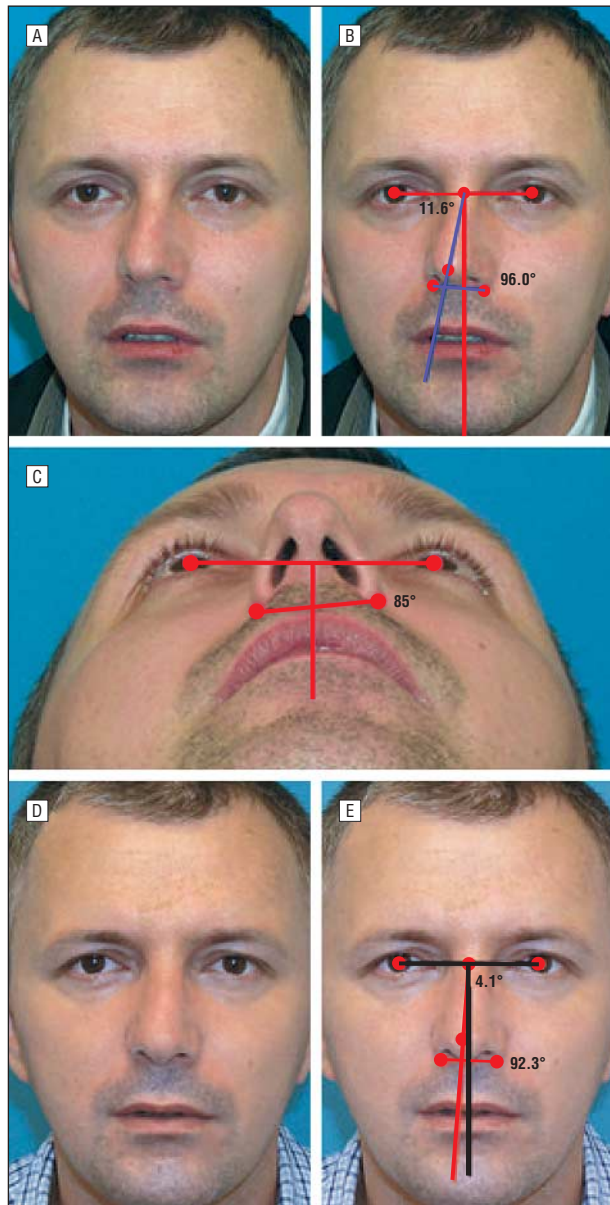


Figure 4. Nontraumatic congenital nasal deviation. The patient had no significant cosmetic concerns besides a desire for frontal straightening and did not want formal tip surgery. Functional endonasal rhinoplasty was performed with open reduction of the nasal bones with left perforating double lateral osteotomy, linear septoplasty correction, upper lateral cartilage separation, left crushed cartilage onlay graft, inferior turbinoplasties, and a right subalar graft. A, B, and C, Preoperative views. D and E, The postoperative result, which the patient found cosmetically and functionally acceptable.

injury having occurred many years earlier. It is conceivable that trauma sustained during childhood may cause developmental asymmetries due to growth center alterations, producing a form that is structurally analogous to congenitally deviated noses.

Our collective experience demonstrates that patients with acute trauma and known fractures often have more complete correction and require less surgical maneuvering to straighten the nose. The base view analysis has helped to guide us in determining the likely degree and scope of pre-injury NA deviation, which has helped to identify patients at risk for persistent postoperative NA shifts. Patients with longstanding traumatic deformities and congenital devia-

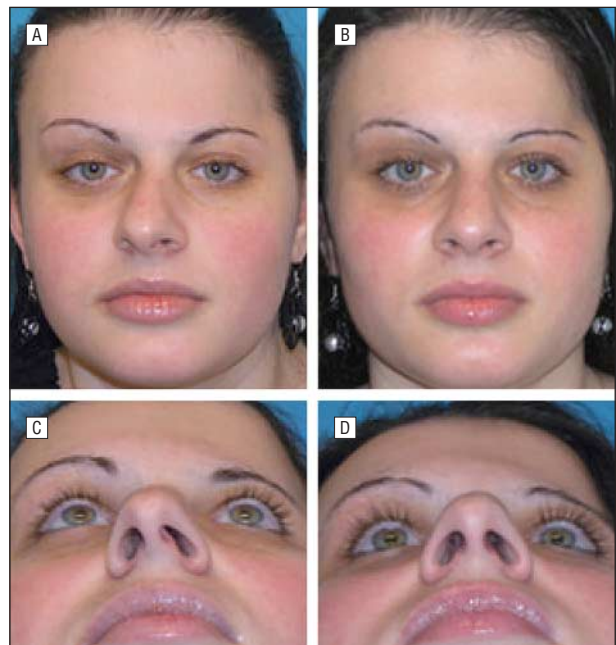


Figure 5. Traumatic nasal deviation with documented fracture. On further questioning, the patient admitted to a preinjury deviation of likely congenital cause. The patient had no significant cosmetic concerns besides a desire for frontal straightening and did not want formal tip surgery. Functional endonasal rhinoplasty was performed with open reduction of the nasal bones with a left perforating double lateral osteotomy, linear and caudal septoplasty, upper lateral cartilage separation, left crushed cartilage onlay graft, inferior turbinoplasties, and right subalar graft. A and C, Preoperative views. B and D, The postoperative result, which the patient found cosmetically and functionally acceptable.

tions should be counseled on the higher rate of persistent deformities, the need for additional foundation grafts, and the potential for revision surgery, given the underlying cartilage, bone, and soft-tissue asymmetries.

We found that angulation of the alar-facial attachment from the base view is highly correlated with NA deviation. We believe this to be most clinically significant in nasal deviations greater than 5° from the vertical facial axis. Dimensional analysis of the nasal tip can be performed by assuming the base is an equilateral triangle that rotationally moves around the higher frontal process. One can then extrapolate measurements along the arc of rotation by using the following equation:

$$\text{Displacement (Millimeters)/Degree} = 2\pi r/360,$$

where r represents the nasal sidewall. If $r = 20$ mm (1.5-cm columellar height), then for every 0.35-mm posterior displacement of the ala, there is 1° of nasal degree axis drift. As this deficiency increases to 5° (1.75-mm foundation displacement), it becomes less plausible to compensate with asymmetric dome binding alone. If $r = 30$ mm, it takes 0.52 mm of posterior alar displacement to produce 1° of axis shift. At $r = 15$ mm, it takes only 0.25 mm of displacement to produce 1° of axis shift. Therefore, as projection decreases, the tip will be rotationally affected by a maxillary deficiency more easily.

In patients seeking functional correction alone, we have begun using subcutaneous alar filler grafts when midfacial asymmetry is a concern in conjunction with nasal bone and septal corrections. Many of these patients will

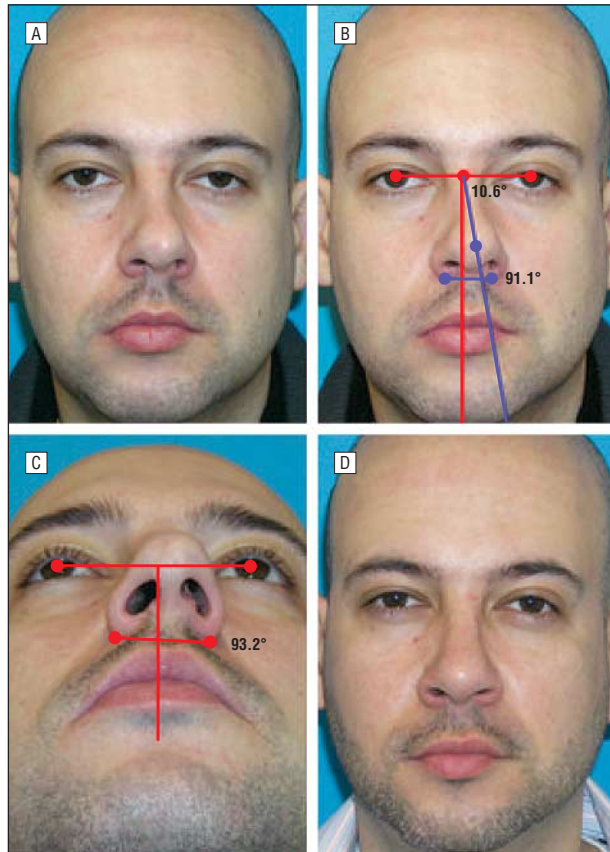


Figure 6. Nontraumatic congenital nasal deviation. The patient had cosmetic concerns, mostly a desire for complete frontal straightening, and accepted formal tip surgery. Preoperative analysis suggested a linear septal dislocation to the left. However, intraoperatively it was noted that the anterior nasal spine and maxillary crest were in the center of the left nasal cavity floor. Base view (C) demonstrates the caudal septum in the left nasal cavity on top of the anterior nasal spine. The septum was left long and placed along the right side of the maxillary crest and spine. Functional and cosmetic endonasal rhinoplasty was performed with complete osteotomies of the nasal bones, translocation septoplasty, upper lateral cartilage separation, right crushed cartilage onlay graft, inferior turbinoplasties, asymmetric double dome binding with incorporated columellar strut, and a left subalar graft. A, B, and C, Preoperative views. D, The postoperative result, which the patient found cosmetically and functionally acceptable.

defer formal tip correction in the absence of secondary cosmetic concerns. The increased use of this graft has provided improvements in the overall NA correction, which is reflected in the ultimate functional result (**Figure 4** and **Figure 5**). Complete cosmetic correction in developmentally deviated noses requires formal tip correction with or without the addition of a subalar graft (**Figure 6**). The use of this graft will diminish the amount of compensation required to medialize an asymmetric tip, increasing predictability during postoperative healing.

Several questions can be raised by this study. One is the use of the interpupillary meridian as a horizontal standard. Because midfacial hypoplasia may also cause orbital dystopia, this may introduce error into the measurements. However, given the lack of other practical soft-tissue points, we believed that this was the most reliable method for standardization. In addition, patients with orbital dystopia often naturally compensate with head tilting. Therefore, the analysis of NA using this approach approximates a patient's natural position in which he or she will be perceived by others.

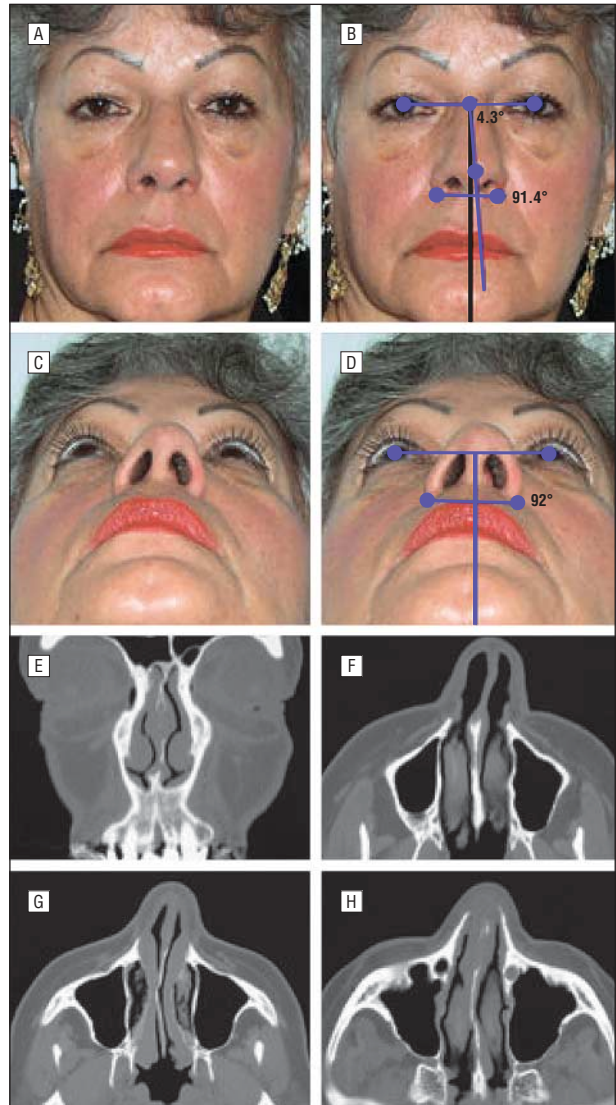


Figure 7. Congenital and traumatic nasal deviation with left-sided midfacial hypoplasia. The patient was seen 4 days after nasal trauma (A-D). Her base view examination suggested that substantial nasal deviation had been present before the injury, which she admitted. Computed tomographic scans (E-H) performed in the emergency department demonstrated left midfacial hypoplasia in the lower maxilla and maxillary crest deviation. The nasal pyramid above approximates an isosceles triangle, which is at 90° to the underlying facial platform.

Perhaps the most intriguing question is the one concerning cause and effect. Because soft-tissue points were used for this analysis, these findings may indicate secondary long-term alterations to the alar-facial soft tissues rather than a primary bony or soft-tissue maxillary deficiency. This question deserves further investigation, including the use of precise imaging modalities (**Figure 7**). However, whether soft-tissue or bony abnormalities are the underlying cause, the effect is the same: a platform deficiency on the side of nasal tip deviation.

SUBALAR GRAFTING TECHNIQUE

The vestibular incision and subcutaneous tissue underlying the ala and medial nasolabial fold is injected with 1% lidocaine hydrochloride. This injection will approxi-

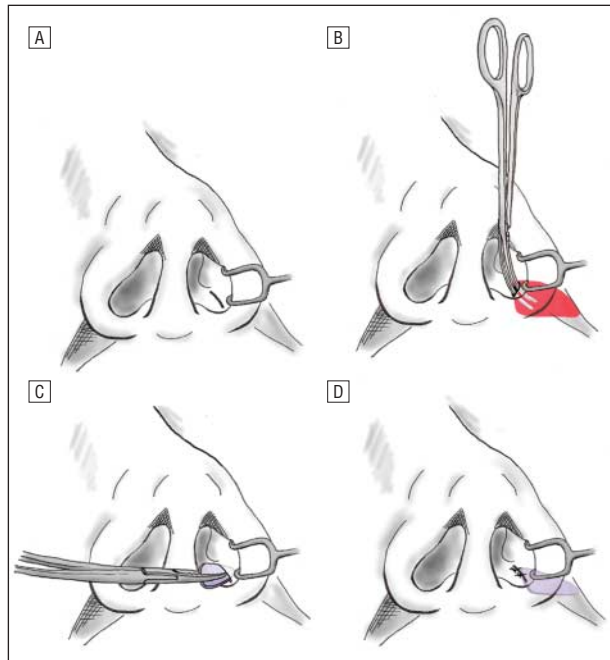


Figure 8. Schematic diagram showing the relevant steps of placing a subalar graft. The graft is placed on the side of maxillary deficiency to help medialize the overlying tip suprastructure (A-D). The graft should lie below the ala, fading into the upper nasolabial fold, and can be laminated for more severe deficiencies.

mate the correction achieved with later placement of the graft.

A triangular piece of uncrushed cartilage measuring approximately 1 cm on all sides is prepared in accordance with the calculated values of rotational displacement: a 1-mm-thick graft will correct 3 to 4 mm of axis displacement. Laminated grafts may be used for more significant axis displacement. The extra thickness is more critical in the region of the graft that will lie underneath the ala medially.

A horizontal incision is made in the vestibule of the nose by means of a scalpel or cutting cautery that mirrors the orientation of the alar crease. Upper lateral scissors or curved Stevens scissors are used in a spreading manner to dissect subcutaneously into the medial nasolabial fold, creating a slightly oversized triangular pocket with its base underlying the ala and its apex in the region of the fold. Scissors should not be closed completely during this dissection to avoid injury to the angular artery in this region. The graft is placed into the pocket after osteotomies have been done with a clamp, and the incision is closed with 1 or 2 interrupted chromic sutures (**Figure 8** and **Figure 9**). After the surgeon has become familiar with the technique, the total operative time is less than 5 minutes for preparation and placement of the graft.

FOUNDATION RHINOPLASTY

The findings from this study, in conjunction with previous publications on osteotomy techniques,⁸ cartilage biomechanics,⁹ and nasal tip support,¹⁰ have led us to conclude that septal correction and equalization of the nose's foundation is the first and most critical step in straight-

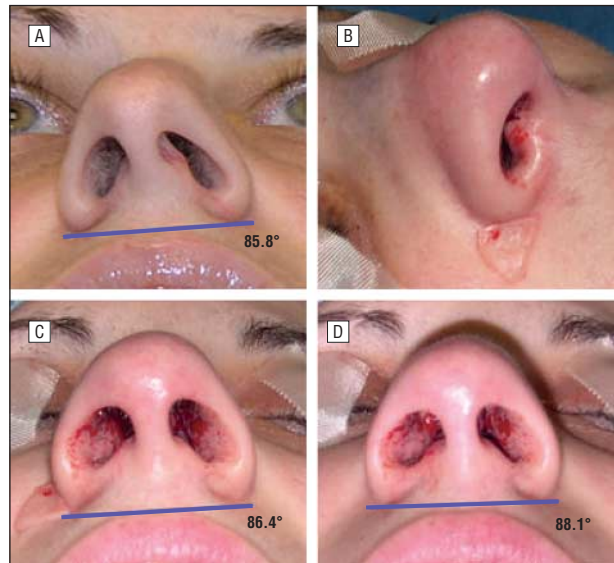


Figure 9. Functional rhinoplasty in a traumatically deviated nose using a subalar grafting technique with base views and measurements in the patient shown in Figure 5. Preoperative base view (A) shows 5° of deviation and caudal septal dislocation. A single 1.2-mm-thick septal cartilage graft is fashioned for placement into a subcutaneous pocket underneath the right ala (B). Correction after caudal septoplasty (C) is only partial (85.8°-86.4°), which is reflected in persistent nasal tip deviation. After placement of the subalar graft (D), the nasofacial angle is now corrected to 88.1°. A 2-mm left retrograde cephalic trim corrected a preoperative lateral crural asymmetry. Frontal examination of the patient showed acceptable straightening without the need for more invasive tip corrective procedures.

ening the deviated nose. Recent trends in rhinoplasty have focused on grafting the overlying suprastructure into a straight configuration. Closer attention to areas providing foundation support to the nose may help to minimize the number and size of grafts required to produce a straight internal and external nose.

Simultaneous correction of all segments (upper, middle, and lower thirds) is critical because secondary deviations may occur from adjacent deviated structures. Each segment has a central main support element (bony septum, cartilaginous septum, and columella) and stands on a rigid maxillary foundation making up the lateral platform for the nose in each individual region. Developmental deficiencies of the maxillary foundation will have a profound influence on the overall angulation of the nose (see Figure 6 and Figure 7).

Lateral displacement can be caused by several factors: distortion of the central support beam, length discrepancies of the sidewalls, and projection asymmetries involving the maxilla. The frontal process of the maxilla is critical for buttressing the upper and middle thirds. The lower third rests on the anteromedial wall of the maxilla and the soft tissues underlying the medial nasolabial fold and ala. Previously, our group defined a method for bony vault correction in the deviated nose and showed how length discrepancies in the nasal bones could be corrected by means of unilateral perforating, double lateral osteotomies.⁸ This method effectively reduces the height of the frontal process of the maxilla and medializes the platform for nasal bone attachment on the side away from the direction of deviation. If the entire nose deviates toward the side of midfacial hypoplasia or projection de-

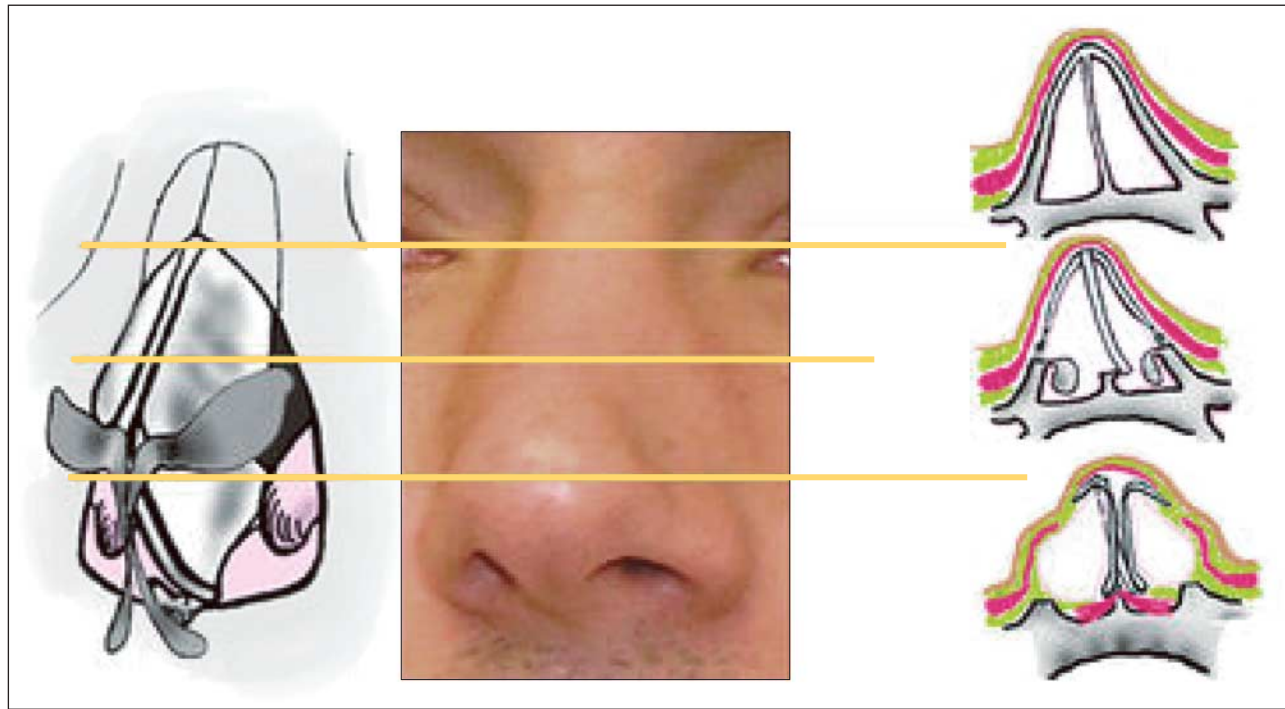


Figure 10. Cross-sectional schematic diagram of the upper, middle, and lower thirds of the nose in the setting of right maxillary deficiency. The effect of a retractive medial maxilla is seen throughout the different regions of the nose. Despite relatively equal development of the nasal suprastructure, a significant linear external deviation is seen in all areas of the nose.

iciency, this would further strengthen the anatomic basis for this approach.

Ultimately, the nose derives its stability through rigid or semi-rigid structures: nasal bones, maxilla, and nasal septum. All other structures derive their stability through a rigid abutment with 1 or more of the foregoing structures. Foundation asymmetries may cause lateral displacement of nasal structures during development. Reduction rhinoplasty may increase the relevance of a preoperative maxillary asymmetry because a greater impact of rotational displacement will be seen with reduced anterior projection of the tip and dorsum. This phenomenon may be at least partially responsible for deviations that occur after an uneventful rhinoplasty. The central support structure, most notably the nasal septum, is critical for maintaining projection for the lower two-thirds of the nose, and the nasal tip cartilages derive support from association with a midline caudal septum. The cantilever model for nasal tip biomechanics explains why displacement of the caudal septum can have profound implications for nasal position, projection, and rotation.

Compensating for facial asymmetry and ensuring a midline nasal septum is the central focus of foundation rhinoplasty. This allows more aggressive endonasal repositioning maneuvers such as violation of the L-strut principle (swinging door techniques, fan septoplasty, and linear corrections incorporating complete bone-cartilaginous dislocation involving the rhinion), upper lateral cartilage separation from the dorsal septum without reconstitution using permanent sutures, complete transfixion incisions down to the anterior nasal spine, and complete osteotomies without elevating the incidence of unwanted postoperative nasal collapse. This more

Table 2. Surgical Plan Based on Goal and Cause

Surgical Goal	Cause of Deviation	Surgical Plan
Functional	Developmental, old trauma	Subalar graft, ORIF of nasal bones, septoplasty, contralateral middle vault spreader or onlay graft
Cosmetic	Traumatic, acute	Osteotomies, septoplasty
	Developmental, old trauma	Asymmetric double dome binding ± alar graft, ORIF of nasal bones, septoplasty, contralateral middle vault spreader or onlay graft
	Traumatic, acute	ORIF of nasal bones, septoplasty, ± contralateral middle vault spreader or onlay graft, dome binding for cosmesis only

Abbreviation: ORIF, open reduction and internal fixation.

aggressive approach in repairing the twisted nose helps to prevent unwanted postoperative deviations.

CONCLUSIONS

This analysis attempts to explain why nasal tip deviation occurs in patients with severe NA deviations from various causes. Our objective is to help surgeons plan more comprehensive corrective procedures, from both a functional and a cosmetic viewpoint, and alert them to the value of careful inspection of routine base views to determine the need for additional subcutaneous alar grafting procedures. We plan additional investigations into the subjective perception of facial asymmetry and will analyze a cohort of postoperative patients who have undergone correction by means of this treatment algorithm.

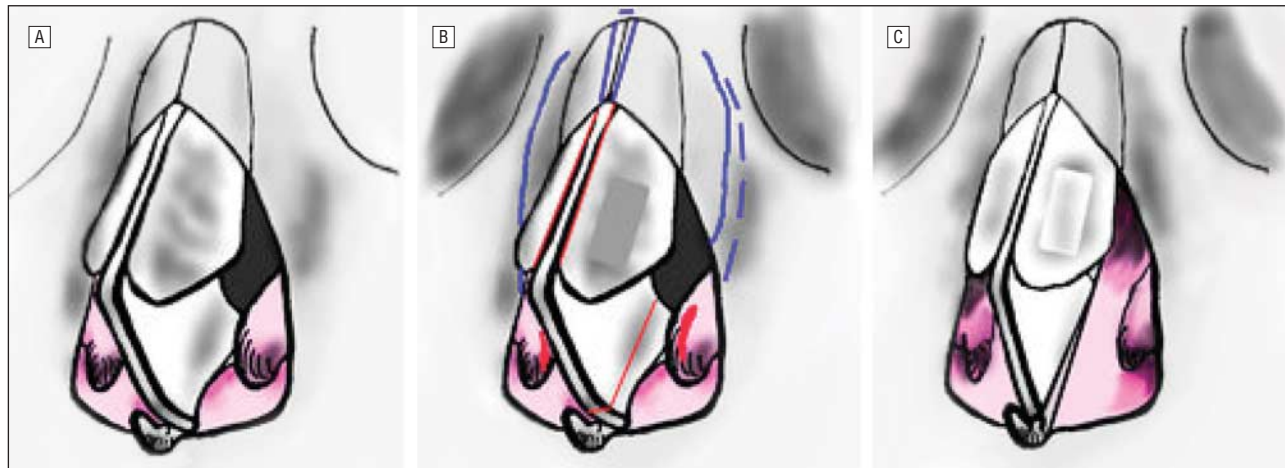


Figure 11. General surgical plan for correcting linear upper and middle nasal deviations. The upper third is corrected by a medial, lateral, and perforating double lateral osteotomy technique (A). A nasofrontal osteotomy may be required if bony profile reduction is not performed to mobilize the central attachment at the nasofrontal suture line (B). A linear septoplasty technique with caudal repositioning, upper lateral cartilage separation, and a left cartilage onlay or spreader graft creates internal and external correction to the middle third (C). Caudal septal medialization is critical in maintaining tip projection and correction of external tip deviation.

On the basis of the results of this investigation, we recommend the use of subalar filler grafts on the side of nasal tip deviation in patients with NA deviations greater than 5° in whom the alar-facial angle on base view lies off of the horizontal axis of the pupillary line. This can be used alone or in conjunction with other tip modification maneuvers.

In patients with midfacial asymmetry, the most common configuration is linear NA deviation toward the side of deficiency with contralateral septal dislocation, contralateral upper lateral cartilage deficiency, lower lateral cartilage asymmetry, and nasal bone length discrepancy (**Figure 10**). A general approach to the patient's anatomy and the potential surgical plan is shown in **Table 2** and **Figure 11**.

In patients with congenital deviations who are seeking complete aesthetic restoration, we recommend asymmetric dome binding techniques with or without subalar grafts. The decision to graft should be based on the preoperative asymmetry and the perceived correction after tip modification. In patients with true recent traumatic deformities, dome modification is optional and based on the surgeon's preoperative assessment of lower lateral cartilage asymmetry.

In purely functional cases, we prefer to use an ipsilateral subalar filler graft of uncrushed cartilage (see **Figure 8** and **Figure 9**). This graft may be laminated in accordance with the 0.3-mm/degree of deviation formula. Our experience with these grafts demonstrates that they will help to further correct the NA deviation to a point that is functionally and aesthetically acceptable to the patient and the surgeon. Secondary benefits of nasolabial fold equalization and improvement of vertical alar displacement may also be achieved.

Accepted for Publication: August 28, 2008.

Correspondence: Francisca Yao, MD, Department of Otolaryngology, State University of New York, Down-

state Medical Center, 450 Clarkson Ave, Brooklyn, NY 11203.

Author Contributions: *Study concept and design:* Lawson and Westreich. *Acquisition of data:* Yao and Westreich. *Analysis and interpretation of data:* Yao and Westreich. *Drafting of the manuscript:* Yao and Lawson. *Critical revision of the manuscript for important intellectual content:* Lawson and Westreich. *Administrative, technical, and material support:* Yao, Lawson, and Westreich. *Study supervision:* Westreich.

Financial Disclosure: None reported.

Additional Information: The term *subalar graft* was originated by Norman Pastorek, MD. His technique uses a subperiosteal placement rather than the subcutaneous one used herein.

REFERENCES

1. Chatrath P, De Cordova J, Reza Nouraei SA, Ahmed J, Saleh HA. Objective assessment of facial asymmetry in rhinoplasty patients. *Arch Facial Plast Surg.* 2007; 9(3):184-187.
2. SPSS. *11.5 Brief Guide.* Upper Saddle River, NJ: Prentice Hall Inc; 2002.
3. Jameson JJ, Perry AD, Ritter EF. High septal osteotomy in rhinoplasty for the deviated nose. *Ann Plast Surg.* 2006;56(1):40-45.
4. Bocchieri A. Evolution of the septal crossbar graft technique. *Facial Plast Surg.* 2006;22(4):255-265.
5. Most SP. Anterior septal reconstruction outcomes after a modified extracorporeal septoplasty technique. *Arch Facial Plast Surg.* 2006;8(3):202-207.
6. Byrd HS, Salomon J, Flood J. Correction of the crooked nose. *Plast Reconstr Surg.* 1998;102(6):2148-2157.
7. Vuyk HD. A review of practical guidelines for correction of the deviated, asymmetric nose. *Rhinology.* 2000;38(2):72-78.
8. Westreich RW, Lawson W. Perforating double lateral osteotomy. *Arch Facial Plast Surg.* 2005;7(4):257-260.
9. Westreich RW, Courtland HW, Nasser P, Jepsen K, Lawson W. Defining nasal cartilage elasticity: biomechanical testing of the tripod theory based on a cantilevered model. *Arch Facial Plast Surg.* 2007;9(4):264-270.
10. Westreich RW, Lawson W. The tripod theory of nasal tip support revisited: the cantilevered spring model. *Arch Facial Plast Surg.* 2008;10(3):170-179.

This article has been cited by:

1. Jong Sook Yi, Yong Ju Jang. 2015. Frequency and Characteristics of Facial Asymmetry in Patients With Deviated Noses. *JAMA Facial Plastic Surgery* 17:4, 265-269. [[Abstract](#)] [[Full Text](#)] [[PDF](#)] [[PDF Plus](#)]
2. Karan Dhir, William Lawson, William J. Binder. 2013. Zonal Analysis of Facial Asymmetry and Its Clinical Significance in Facial Plastic Surgery. *JAMA Facial Plastic Surgery* 15:2, 110-112. [[Abstract](#)] [[Full Text](#)] [[PDF](#)] [[PDF Plus](#)]