

Capsulorrhaphy for Revisionary Breast Surgery

Paul E. Chasan, MD; and Cameron S. Francis, BS

BACKGROUND: Despite more than 3 million breast implant surgeries performed to date, the common sequela of implant malposition is a problem to which little attention has been paid in the literature. It can be treated predictably and relatively simply with capsulorrhaphy and mirror-image capsulotomy. Additionally, capsulorrhaphy can be used to reduce the size of the implant pocket when changing to a smaller implant.

METHODS: Several capsulorrhaphy techniques have emerged that allow a more precise result with less effort. In almost all cases of implant malposition, a mirror-image capsulotomy was performed to decrease the tension on the capsulorrhaphy repair. Silicone gel-filled implants were placed in all cases.

RESULTS: Seventy-five patients underwent capsulorrhaphy for implant malposition or implant size reduction between May 2002 and March 2006. Of these patients, just under half (49%) had an accompanying mastopexy. Excision of capsular tissue and prolonged taping of the breasts were found not to be necessary. Average follow-up was 21 months; no complications were reported.

CONCLUSIONS: The current technique of capsulorrhaphy and mirror-image capsulotomy has demonstrated satisfactory improvement in implant malposition, without the need for excision of capsular tissue or prolonged taping. Patients did report that their postoperative discomfort was greater than anticipated. (*Aesthetic Surg J* 2008;28:•••)

More than 3 million breast augmentations have been performed in the United States to date. Implant malposition can be a common occurrence after breast implant surgery, yet there is little attention paid to addressing this problem in the literature. In addition to correction of malposition, there are a significant number of patients who wish to have their implants changed to a smaller size while retaining superior-pole fullness. By placing a smaller implant into an existing larger pocket, projection and superior fullness are diminished and lateral displacement occurs on recumbency. Since our last publication on this subject,¹ several modifications were made to make the procedure more predictable and easier to perform. Capsulorrhaphy remains an effective method to recontour the shape and size of the breast implant pocket, resulting in a better shape and appearance of the breast.

Methods

Examination of a patient seen for revisionary breast surgery requires three additional assessments beyond those that are standard for primary augmentation. First, the patient is examined and photographed in the supine position to evaluate lateral displacement and asymmetry. Second, the relationship of the areola to breast mound is assessed during simulation of capsulorrhaphy by digital pressure, because this relationship may change dramatically after capsulorrhaphy. Such cases may necessitate

areolar repositioning. For example, a lateral capsulorrhaphy with a medial capsulotomy can create a relative lateral displacement of the areola, whereas an inferior capsulorrhaphy with a superior capsulotomy can result in relative inferior positioning of the areola requiring a mastopexy. Finally, it is important to clarify the plane (subglandular or subpectoral) in which the implant lies to determine whether pocket repositioning will be required during the surgery. Generally, the current indications for pocket repositioning from subglandular to subpectoral are wrinkling (especially medially) and recurrent capsular contracture.

Immediately before surgery the patient is marked in the sitting position. Simulation of the capsulorrhaphy is performed digitally and marked with the patient in both the sitting and supine positions. In almost all cases of implant malposition, a mirror-image capsulotomy will be performed to decrease the tension on the capsulorrhaphy repair (Figure 1). General anesthesia is preferred. The inferior periareolar incision is usually the approach of choice. Once the implant has been removed, the mirror-image capsulotomy is performed. With a balloting technique, digital pressure is applied to the outside of the breast where the simulated capsulorrhaphy marks were made. The chest wall and corresponding capsule are lightly scored with electrocautery. A long (at least 9-inch) needle holder is used to place several interrupted 2-0 Ethibond sutures (polybutylate-coated polyester; Ethicon, Somerville, NJ), each approximately 1.5 cm apart. Sutures are placed through the capsule and muscular tissue. This is done without the use of chest wall

Dr. Chasan is in private practice in La Jolla, CA, and Assistant Clinical Professor at the University of California, San Diego. Mr. Francis is a medical student, the University of California, San Diego, La Jolla, CA.

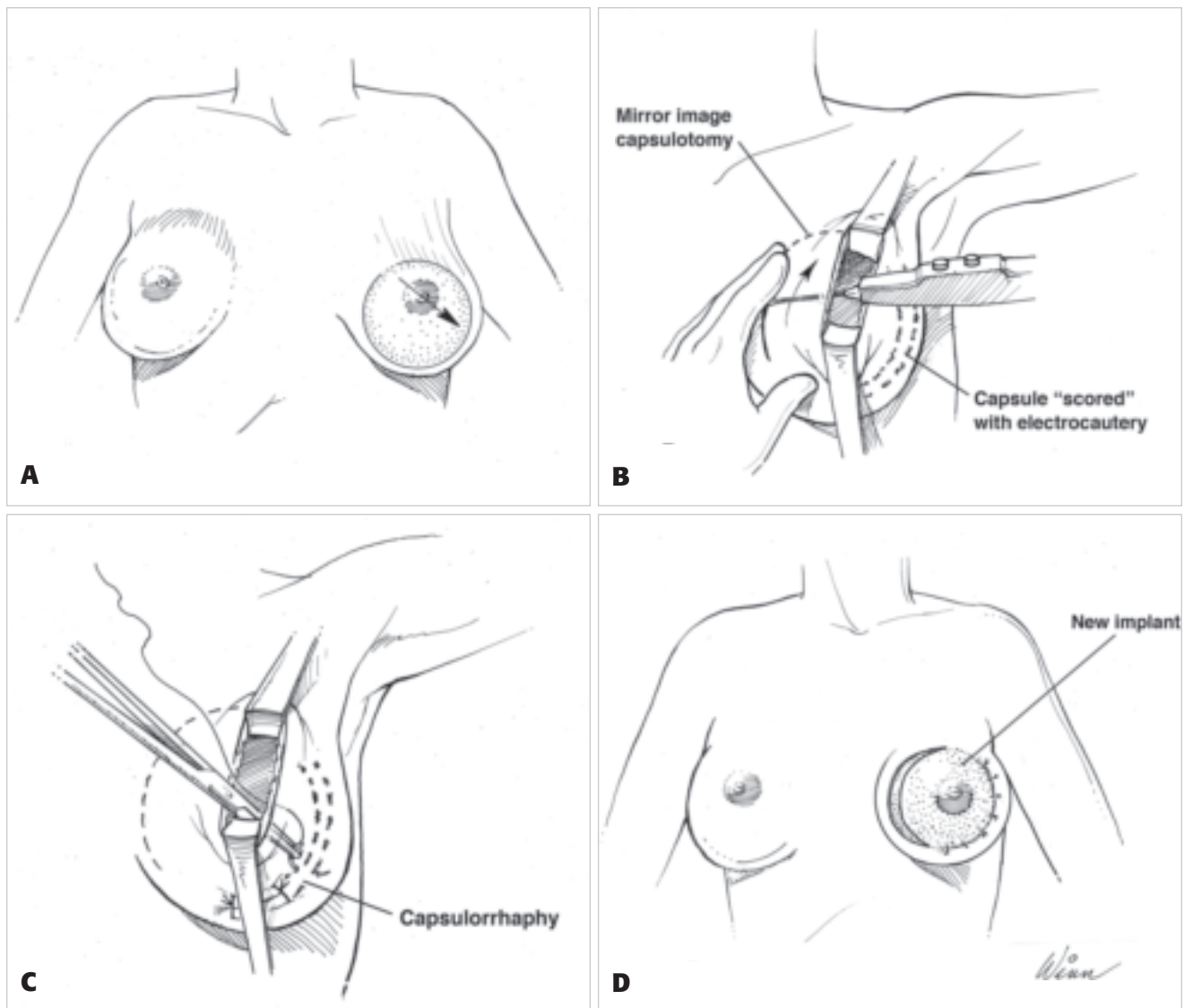


Figure 1. **A**, Note inferolateral displacement "malposition" of the implant. **B**, **C**, Inferolateral capsulorrhaphy and superomedial "mirror-image" capsulotomy. **D**, The implant is now repositioned in the correct anatomic location.

components in all cases except that of medial capsulorrhaphy, for which it is necessary to incorporate periosteum into the repair. A sizer is then placed, and the result is evaluated with the patient in both the supine and sitting positions. Modifications of the sutures can be performed at this stage.

After satisfactory capsulorrhaphy repair with a sizer, the capsulorrhaphy is reinforced with a running 2-0 Ethibond suture. The final implant is then placed. Silicone implants were used in all patients. It is believed by the authors that in performing revisionary surgery a silicone gel-filled implant will produce less palpability and wrinkling with better compressibility, yielding an overall superior result. During approximately 20% of inferolateral capsulorrhaphies, a significant bulge forms in the upper-outer quadrant of the breast. This bulge corresponds to the axillary tail of the breast and is treated with a pilot incision 1 to 2 cm away from the capsulorrhaphy repair at the center of the bulge, followed by excision of a small amount of breast tissue (20-50 g).

Recurrent symmastia is treated with capsulorrhaphy and an adjustable fill implant, which is filled over the course of 3 to 4 weeks. A silicone implant is then used 3 to 4 months later.

The incision is closed in three layers and dressed with gauze and Tegaderm (3M Health Care, St. Paul, MN). The area of capsulorrhaphy is reinforced with foam tape. This is left in place for 1 to 3 days. The patient is then wrapped in a 6-inch Ace Bandage (BD Medical, Franklin Lakes, NJ) overnight, and then placed in an underwire brassiere to be worn day and night for the next 3 to 4 weeks. For patients with symmastia, the Thongbra (Thongbra, Inc., Lyndell, PA) is used. Light implant stretching exercises are started 2 weeks after surgery, with an emphasis on stretching toward the area of capsulotomy.

Results

Seventy-five patients underwent a capsulorrhaphy procedure preformed by the primary author between May 2002 and March 2006 (Figures 2 to 9). Four of these

AQ1

AQ2

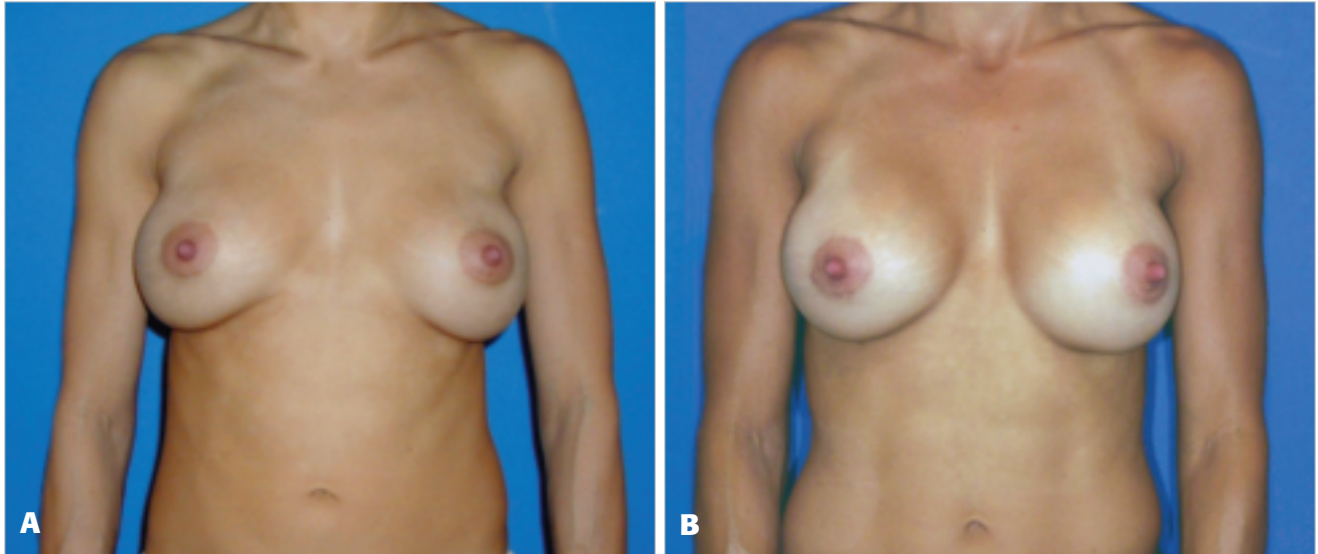


Figure 2. A, Preoperative view of a 36-year-old woman who underwent transaxillary breast augmentation 14 months previously with 290-cc saline solution-filled implants complicated by capsular contracture and lateral malposition of the breasts. **B,** Postoperative view 30 months after bilateral lateral capsulorrhaphy with medial (mirror-image) capsulotomy, and implant exchange to 350 cc, smooth, round McGhan style 20 silicone implants.

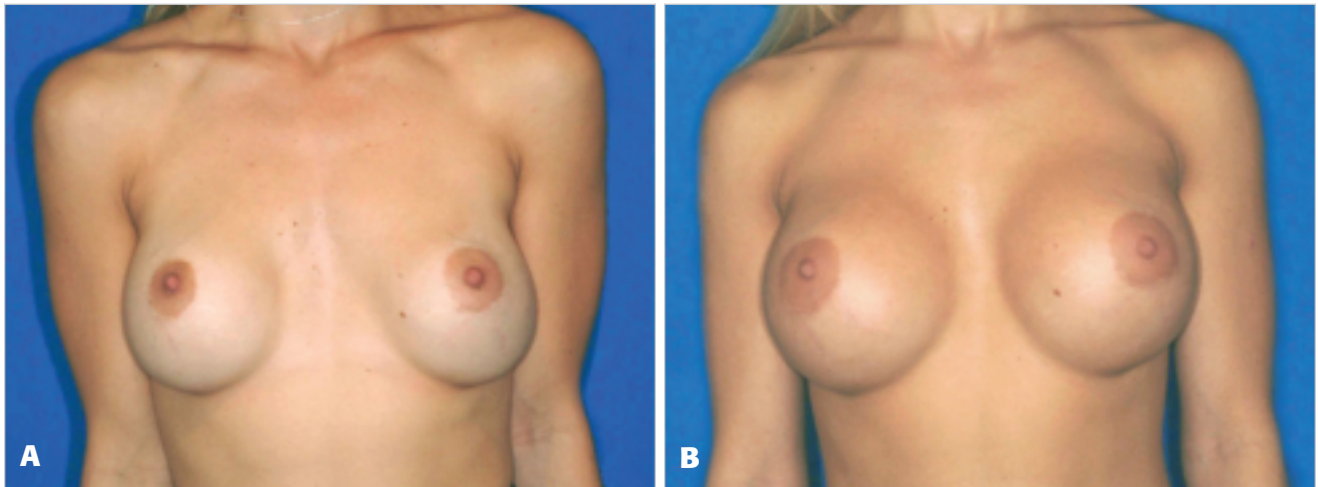


Figure 3. A, Preoperative view of a 25-year-old woman who 2 years previously underwent periareolar breast augmentation with 275-cc saline implants. The patient had wide-spread breasts with inferolateral malposition of the left breast. **B,** Postoperative view 17 months after left inferolateral capsulorrhaphy and bilateral medial capsulotomy, with implant exchange to 550-cc smooth, round McGhan style 45 high profile silicone implants.

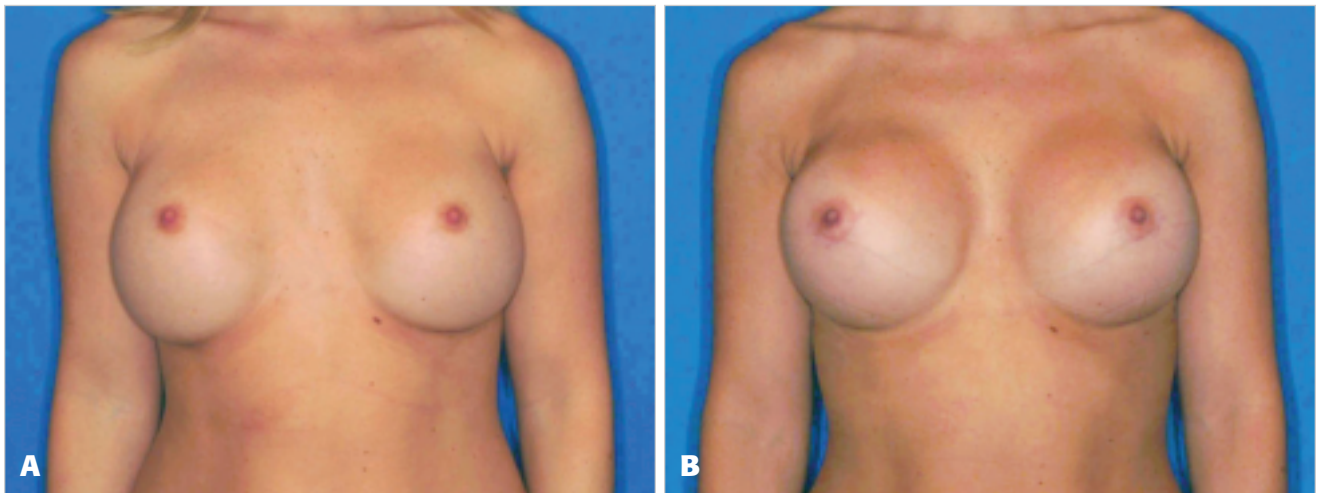


Figure 4. A, Preoperative view of a 27-year-old woman who underwent transaxillary breast augmentation 7 years previously with 420 cc and 425 cc saline implants in the right and left breast, respectively. The patient desired more roundness medially. **B,** Postoperative view 6 months after right inferolateral and left lateral capsulorrhaphy with medial capsulotomy, and implant exchange to 500-cc McGhan style 45 high-profile silicone implants.

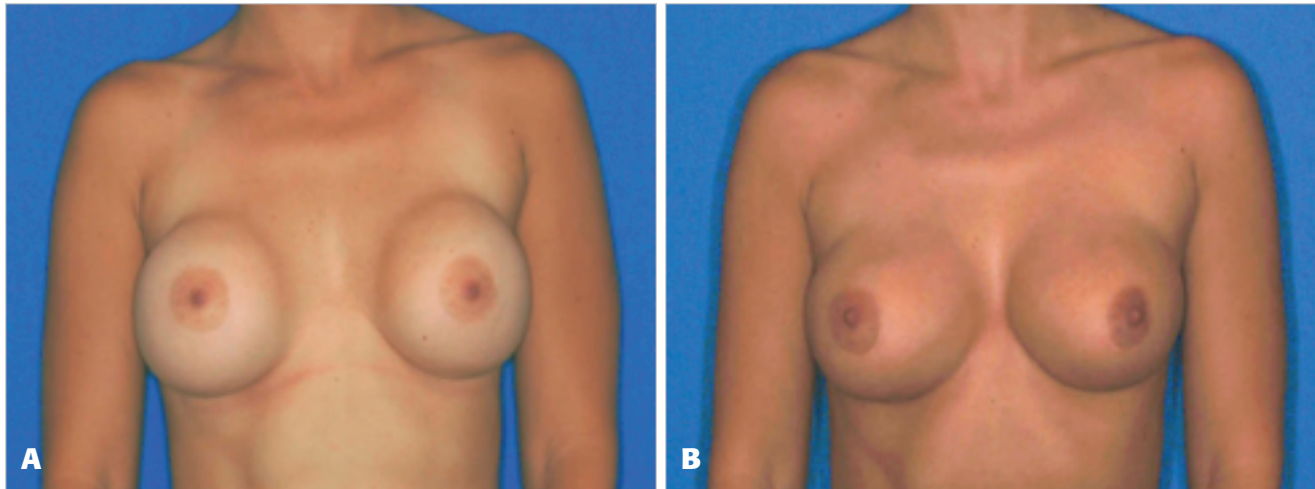


Figure 5. **A**, Preoperative view of a 23-year-old woman who underwent breast augmentation 5 years previously with 325-cc saline solution-filled implants. This was complicated by capsular contracture, and subsequent recurrence following open capsulotomy. The patient had wide-spaced breasts with lateral malposition of implants. **B**, Postoperative view 10 months after bilateral inferolateral capsulorrhaphy with superomedial (mirror-image) capsulotomy, and implant exchange to 325-cc smooth, round McGhan style 20 silicone implants.

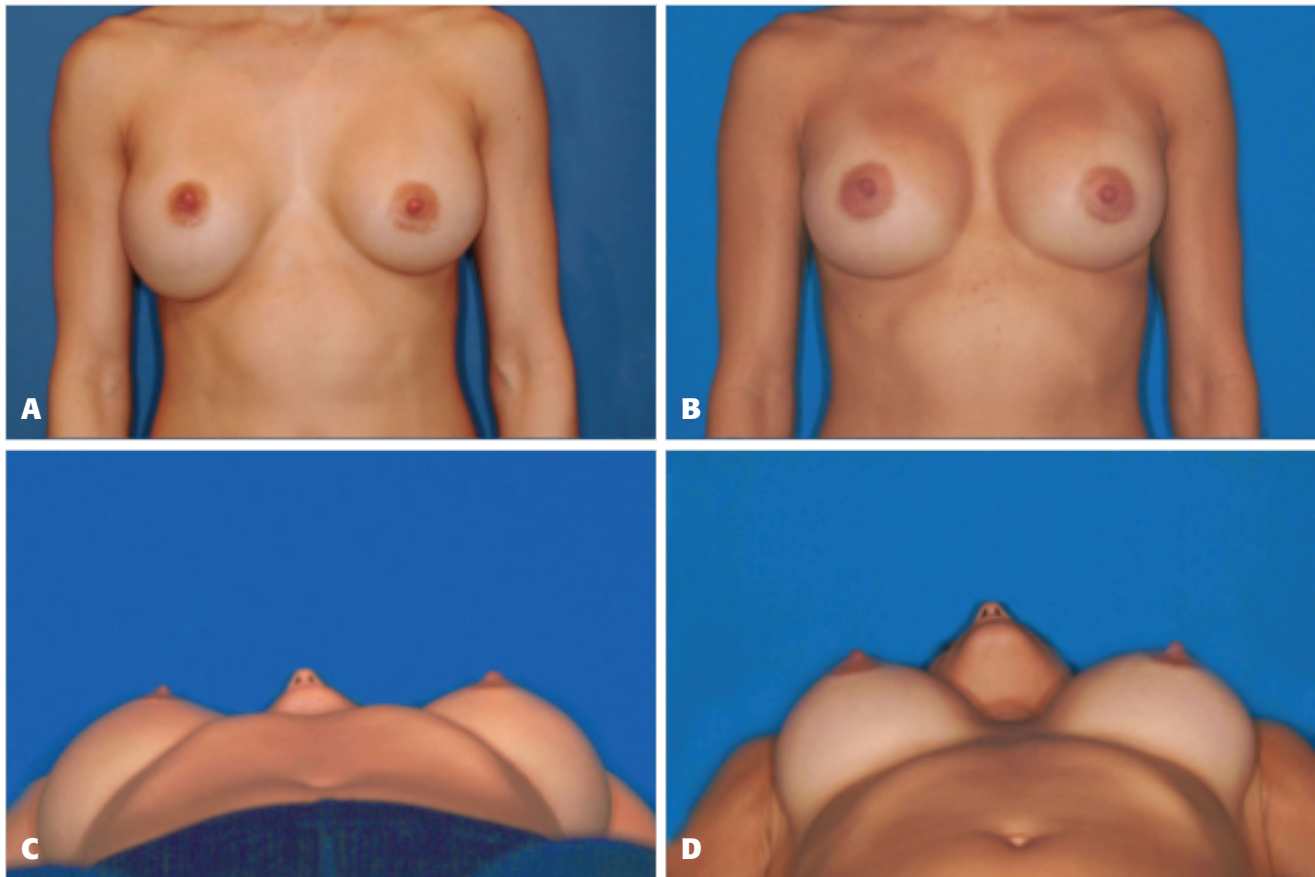


Figure 6. **A, C**, Preoperative views of a 25-year-old woman who underwent subpectoral breast augmentation 5 years previously with 375-cc saline implants filled to 450 cc. The patient's breasts exhibited asymmetry and lateral displacement on recumbency. **B, D**, Postoperative views 14-months after left lateral capsulorrhaphy, right inferolateral capsulorrhaphy, bilateral medial (mirror-image) capsulotomy, and implant exchange to 450 cc McGhan style 20 silicone implants.

patients had primary augmentations performed by the author, whereas the remaining 71 had primary augmentations performed outside of his practice. The average follow-up is 21 months, during which time there have been no complications. Of the patients, 35 (47%) required inferolateral capsulorrhaphy, 26 patients (35%)

required lateral capsulorrhaphy, 8 patients (11%) required medial capsulorrhaphy, 3 patients (4%) required inferior capsulorrhaphy, and 3 patients (4%) required superolateral capsulorrhaphy (Figure 10). Of final implants placed, 36% were smaller than those removed, 37% were larger than those removed, and

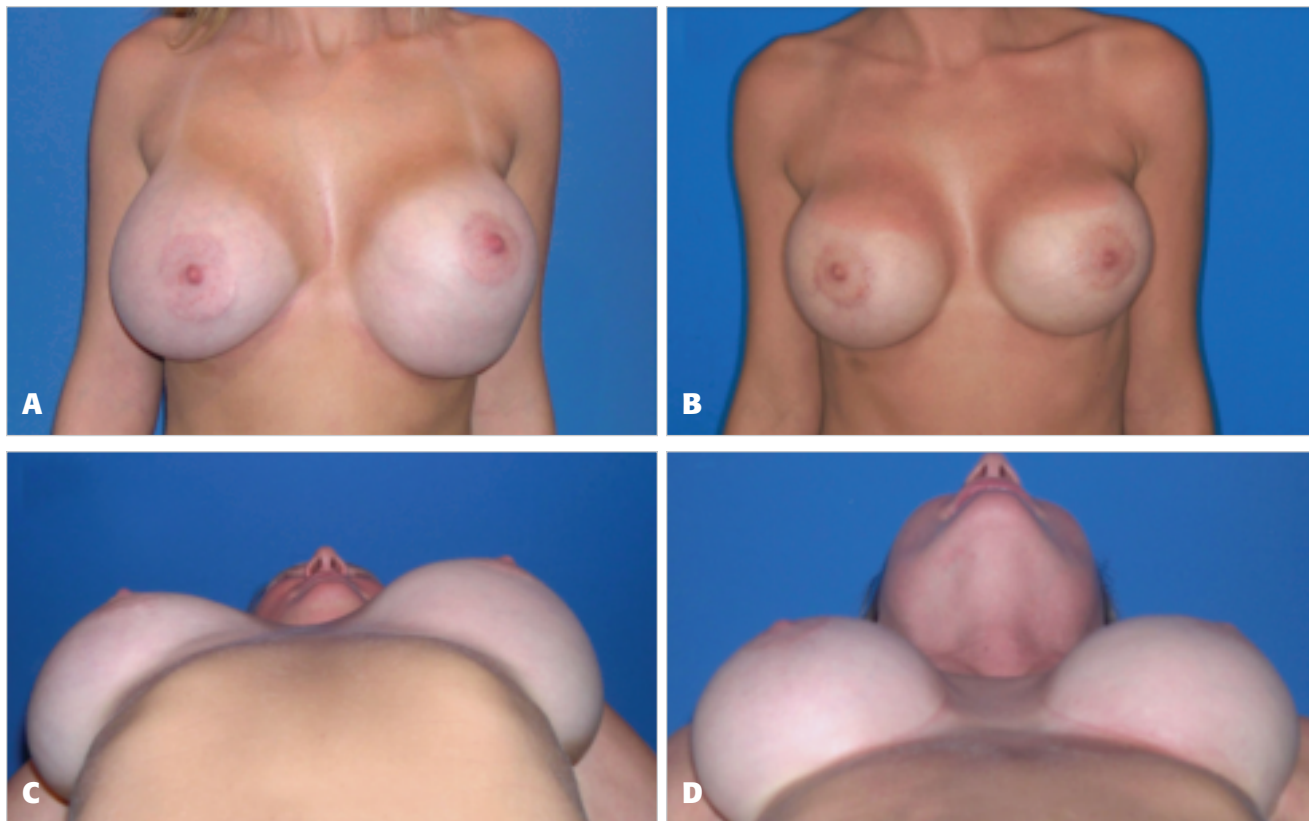


Figure 7. **A, C,** Preoperative views of a 26-year-old woman who underwent subpectoral breast augmentation and mastopexy 8 months previously with 550-cc and 575-cc saline solution-filled implants in the right and left breast, respectively. The patient had lateral malposition of the right implant and inferior and lateral malposition of the left implant. **B, D,** Postoperative views 13 months after right lateral capsulorrhaphy, left infero-lateral capsulorrhaphy, bilateral medial (mirror-image) capsulotomy, and circumareolar mastopexy. The patient's implants were exchanged for smooth, round McGhan style 45 high-profile silicone implants of 460 cc and 400 cc for the right and left breast, respectively.

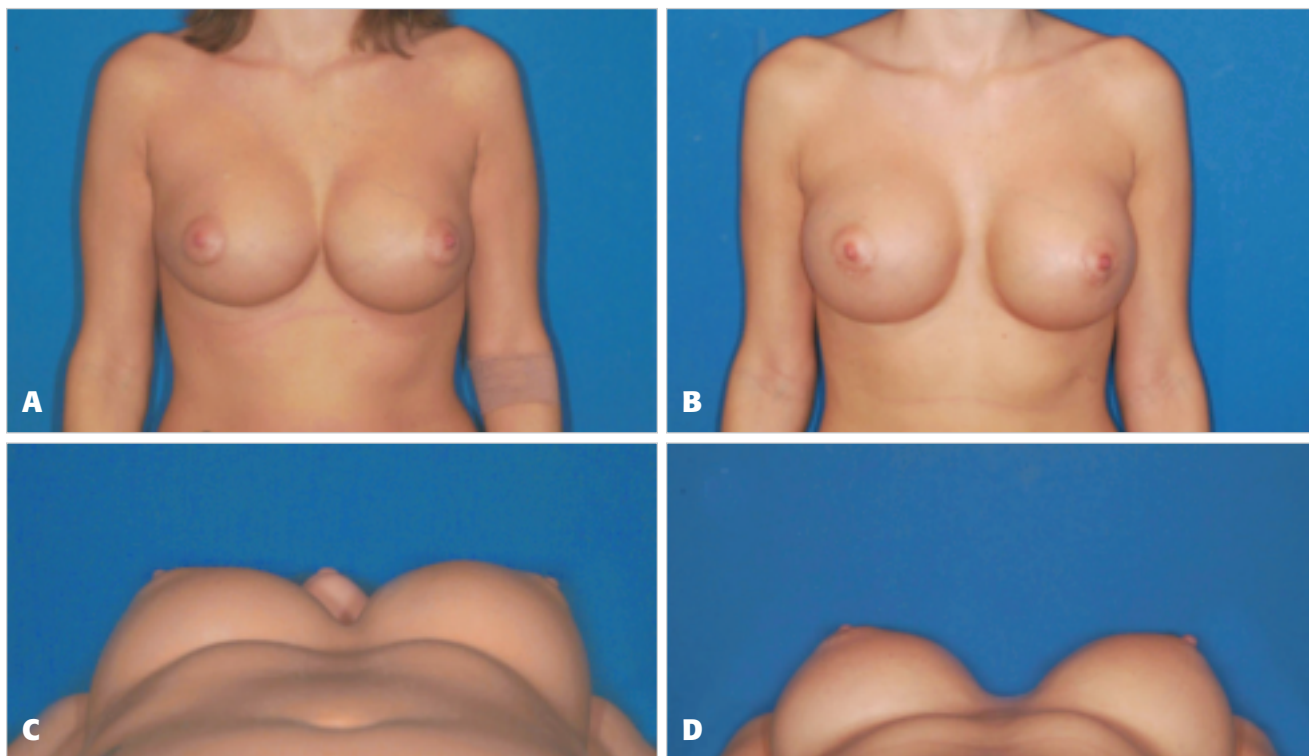


Figure 8. **A, C,** Preoperative views of a woman who underwent submammary breast augmentation with 360 cc McGhan textured implants 9 years previously. The patient had symmastia and three previous attempts at correction. **B, D,** Postoperative views 6 months after bilateral medial capsulorrhaphy with lateral partial-capsulectomy. The patient's implants were exchanged for smooth, round McGhan style 45 high-profile silicone implants of 460 cc and 500 cc for the left and right breast, respectively.

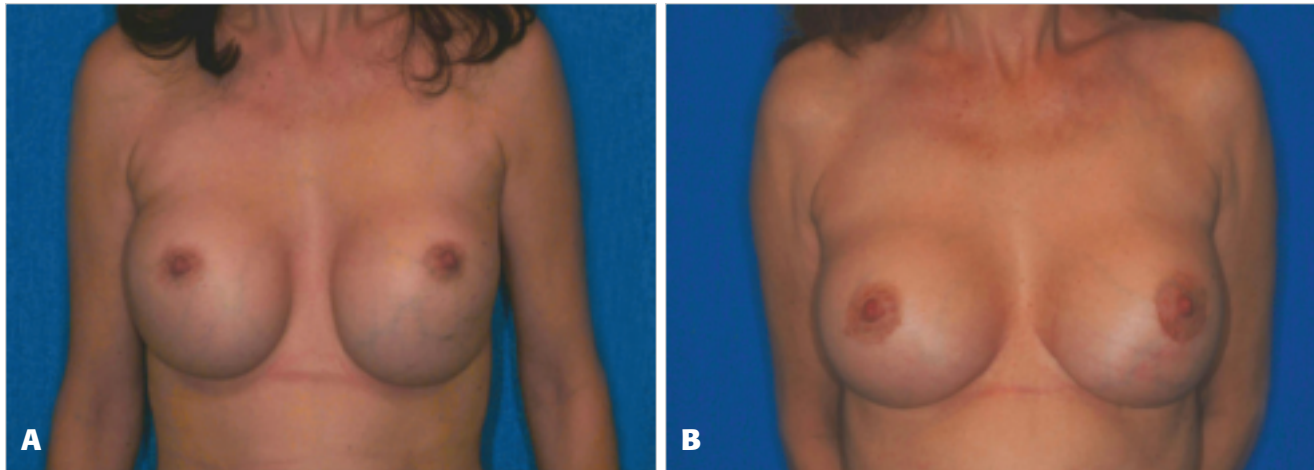


Figure 9. A, Preoperative view of a 50-year-old woman who underwent breast augmentation 6 years previously with 450 cc saline solution-filled implants. The patient had inferior implant malposition. B, Postoperative view 7 months after bilateral inferior capsulorrhaphy with superior (mirror-image) capsulotomy, and implant exchange to smooth, round McGhan style 20 silicone implants of 375 cc and 350 cc for the right and left breast, respectively.

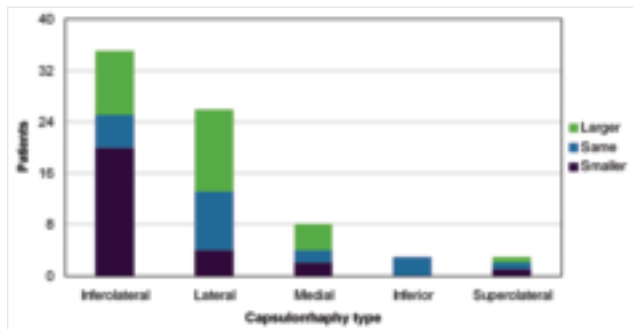


Figure 10. Number of patients having inferolateral, lateral, medial, inferior, and superolateral capsulorrhaphy. The number of patients having each type of capsulorrhaphy is further subdivided into those receiving implants of smaller, equivalent, and larger sizes compared with those removed.

Table. Patient questionnaire and results

Question	Mean of responses
How would you rate your final result aesthetically, 10 being best and 1 being worst?	8.3
How would you rate your result compared with your initial augmentation, 10 being most improved, 5 being equal, and 1 being worse?	8.7
How would you rate your recovery, 10 being easiest and 1 being most difficult?	7.9
All factors considered, how would you rate your experience with your revisionary breast surgery?	8.6

27% were of equivalent size to the implants removed. Most patients having inferolateral capsulorrhaphy had smaller implants placed, whereas most patients having capsulorrhaphy in other locations received larger or equally sized implants. The difference between mean preoperative implant size (381 cc) and mean postoperative implant size (378 cc) is negligible. Of lateral and inferolateral capsulorrhaphies, approxi-

mately 20% required excision of breast tissue. The number of patients having a capsulorrhaphy associated with a mastopexy was 37 (49%). Four patients (5%) had unilateral capsulorrhaphy.

In May 2006 a questionnaire was distributed to all subjects in the capsulorrhaphy study. Thirty-five patients (47%) responded (Table) and were generally happy with their results. On the basis of the comments on the questionnaire, approximately one third of respondents reported moderate to more severe pain after capsulorrhaphy.

Discussion

As the popularity of breast augmentation surgery continues, so does the need to repair complications. Implant malposition, symmastia, and the desire to change to smaller implants are all indications that may benefit from a capsulorrhaphy. It is important to evaluate the patient before surgery in a supine position to assess the displacement of the breast implant and symmetry. Photography with the patient in the supine position is important in demonstrating to the patient the extent of any asymmetry, as well as the degree of any lateral displacement of the breasts. The patient should be made aware that the position of the areola will change with respect to the capsulorrhaphy and that areolar repositioning may be required.

As more experience has been gained with this technique, it has become evident that there is no need to excise capsular tissue and no need for percutaneous suturing and that patients do not need to be placed in cumbersome dressings or be taped for extended periods of time. The mirror-image capsulotomy is an important aspect of the repair, decreasing tension on the capsulorrhaphy. The data indicate that inferolateral capsulorrhaphy was used in most patients for whom a change to a smaller implant was performed, reflecting the need for reduction of pocket volume in superior and medial directions. As always, surgical judgment is important in each case, as is evaluation of the tissue and skin quality. A patient with poor tissues who has already bottomed out

will not do well with an inferior capsulorrhaphy and placement of a large implant.

Capsulorrhaphy is a powerful technique in the plastic surgeon's armamentarium to deal with specific implant problems. The technique as described allows a repositioning of the breast implant in a straight-forward and predictable manner. The results have held up over time, while restoring symmetry and improving shape in patients who have been disappointed with their previous results.

Conclusion

Breast capsulorrhaphy is a technique that can be used for the repair of implant malposition and improving the results in revisionary breast surgery. There is a high level of satisfaction among patients. The patient should be made aware that there may be significant postoperative discomfort. All patients should be evaluated in both the sitting and supine position before surgery and photographed in the supine position from a "worm's eye" view. There is no need for excision of capsular tissue, percutaneous suturing, or prolonged taping. The technique is relatively straightforward and easy to learn, and the results appear to last. ■

AQ3 References

1. Chasan PE. Breast capsulorrhaphy revisited: A simple technique for complex problems. *Plast Reconstr Surg* 2004;115:296-301.
2. Spear SL, Little JW. Breast capsulorrhaphy. *Plast Reconstr Surg* 1988;81:274-279.
3. Codner MA, Cohen AT, Hester TR. Complications in breast augmentation: prevention and correction. *Clin Plast Surg* 2001;28:587-595.
4. Spear SL, Low M, Ducic I. Revision augmentation mastopexy: indications, operations, and outcomes. *Ann Plast Surg* 2003;51:540-546.
5. Dionyssopoulos A. The non-perfect results of breast implants. *Ann Chir Plast Esthet* 2005;50:534-543.
6. Carsen LN, Voice SD. Using a capsular flap to correct breast implant malposition. *Aesthet Surg J* 2001;21:441-444.

Accepted for publication July 27, 2007.

Reprint requests: Paul E. Chasan, MD, 9850 Genesee Ave., Suite 880, La Jolla, CA 92037.

Copyright © 2008 by The American Society for Aesthetic Plastic Surgery, Inc.

1090-820X/\$32.00

doi:10.1016.j.asj.2007.07.007

AQ1 Author: Please verify that the city and state are correct for 3M Corporation.

AQ2 Author: Please verify that the city and state are correct for BD Medical.

AQ3 Author: Please cite references 2-6 in order in the text or delete from the reference list.