



Today's Date: _____

Patient Name: _____

Patient DOB: _____

SURGEON/DATE

- | | | |
|---|--|---|
| <input type="checkbox"/> Bilal Ahmed, MD | <input type="checkbox"/> Michael Hodkin, MD | <input type="checkbox"/> Michael Orr, MD |
| <input type="checkbox"/> Paul Cacchillo, MD | <input type="checkbox"/> Patrick Hopen, MD | <input type="checkbox"/> Ahmar Sajjad, MD |
| <input type="checkbox"/> Joseph Carr, MD | <input type="checkbox"/> Anthony Lombardo, MD, PhD | |
| OD _____ | | OS _____ |

SUBJECTIVE

- | | | |
|---|---|--|
| <input type="checkbox"/> Thrilled with visual improvement | <input type="checkbox"/> Vision improving | <input type="checkbox"/> No complaints |
| <input type="checkbox"/> Eye discomfort or pain | <input type="checkbox"/> Vision getting worse | <input type="checkbox"/> Other _____ |

- Day 1 after surgery
- 1 week between eyes
- 2-4 weeks after surgery
- 100 day check (refractive)
- _____

EYE MEDICATIONS

- | | | | | | | |
|-----------------------------|-------------------------------|--|--|--|---|--|
| <input type="checkbox"/> OD | <input type="checkbox"/> none | <input type="checkbox"/> Pred-Moxi-Nepaf tid x1 week then bid x3 weeks | | <input type="checkbox"/> Ofloxacin qid | <input type="checkbox"/> Prednisolone acetate qid | <input type="checkbox"/> Ketorolac qid |
| <input type="checkbox"/> OS | <input type="checkbox"/> none | <input type="checkbox"/> Pred-Moxi-Nepaf tid x1 week then bid x3 weeks | | <input type="checkbox"/> Ofloxacin qid | <input type="checkbox"/> Prednisolone acetate qid | <input type="checkbox"/> Ketorolac qid |

EXAMINATION

VSC

OD 20/_____
OS 20/_____

Near VSC

OD J_____
OS J_____

IOP

OD _____mmHg
OS _____mmHg

REFRACTION

OD _____ 20/_____
OS _____ 20/_____

CONJUNCTIVA

- OD OS
- white
 - mild injection
 - subconj heme
 - other

CORNEA

- OD OS
- clear
 - arcuate incision(s)
 - edema
 - other

ANTERIOR CHAMBER

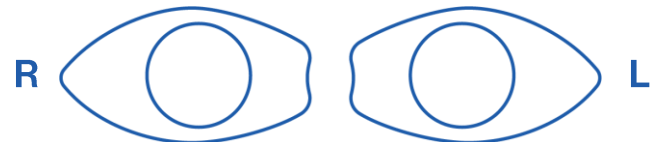
- OD OS
- deep & quiet
 - mild debris
 - mild cell
 - other

IRIS

- OD OS
- pupil round
 - other

IOL

- OD OS
- centered & normal
 - other



POSTERIOR CAPSULE

- OD OS
- clear
 - fibrosis
 - pearls
 - other

RETINA

- OD OS
- unchanged
 - CME
 - other

IMPRESSION

- Normal post-operative course
- Other _____

PLAN

- CPM and next visit in _____ week(s) / month(s) / year
- Change management _____

CO-MANAGING DOCTOR (PLEASE PRINT)

Submit form via fax to 317.579.7435 or email to referrals@esi-in.com