

Presacral Donor Site for Lip Augmentation

Paul E. Chasan, M.D., and Shahrar R. Rahban, B.S.

La Jolla, California, USA

Abstract. For over a century surgeons have been in search of the perfect tissue filler. In recent years lip augmentation has become quite popular. Despite the numerous methods employed to enhance the fullness of lips, autogenous free dermal fat grafting (FDFG) still remains a preferred method. FDFG has been extensively investigated clinically as well as histologically. However, despite its efficacy, FDFG has failed to gain widespread clinical acceptance. One reason has been concern about donor-site morbidity. In this paper, we describe a method of lip augmentation, which utilizes a dermal fat graft from the presacral region. This site is optimal because it has thick skin with minimal hair follicles and leaves a minimal scar.

Key words: Lip augmentation—Presacral donor site—Dermal fat graft

Technique

The patient is placed on the operating room table in the prone position. The area just above the anal verge is infiltrated with 1% lidocaine with epinephrine. An ellipse, at least 6 cm in length \times 2 cm in width, is deepithelialized (Fig. 1). The dermal fat graft is then removed in total and divided into an upper/lower lip on the back table. The presacral wound is closed in layers with interrupted No. 3-0 Monocryl sutures. After this is dressed, the patient is placed in the supine position. The lips are infiltrated with 1% lidocaine with epinephrine. The dermal fat graft is then contoured appropriately and the majority of fat is removed. Three small incisions are made in each lip, and a subcutaneous tunnel is developed with small curved Iris scissors. The tunnel is stretched by spreading the scissors on withdrawal. Using a Kelly

clamp, the instrument is inserted from the lateral access incision in the lip and brought out through the midline incision. The graft is brought in through the midline and brought out through the initial lateral access incision. A clamp is then applied to the graft at this point. Another Kelly clamp is placed through the other lateral access incision. The graft end is grasped, and the graft is then pulled through. Following this, a Kelly clamp is placed on each end of the graft, exiting the lateral incisions. A to-and-fro motion is used to seat the graft in a midline position. A small technical point is that the midline incision should be significantly larger than the lateral incisions, approximately 5 mm, in order to pass the graft into the lips. This incision heals quite well. Enlarging the incision has not been a problem. All incisions are closed with No. 5-0 Prolene sutures. Then 1% hydrocortisone cream is applied to the lips postoperatively, twice a day for 10 days.

Discussion

There are many techniques described for lip augmentation. Each of them has significant merits and disadvantages. Collagen has been used for lip augmentation for many years. Although it gives an excellent augmentation, its effect usually lasts 2–3 months and it requires a considerable amount of collagen. Fat injections have been utilized in the lips. This leads to considerable swelling of the lips, only for the patient to be disappointed in 1 or 2 months with almost-complete absorption of the fat. There is rarely lasting augmentation and often a lumpy appearance, despite multiple sessions. Gortex tubules and sutures have been used in the lips with limited augmentation and have a definite “rubber band” feel of a foreign object in the lips. Alloderm is a recent product, representing the newest series of attempts to provide an “off-the-shelf” soft tissue augmentation for the lips. We have found that Alloderm reabsorbs almost completely

Correspondence to Paul E. Chasan, M.D., 9850 Genesee Avenue, Suite 880, La Jolla, CA 92037, USA

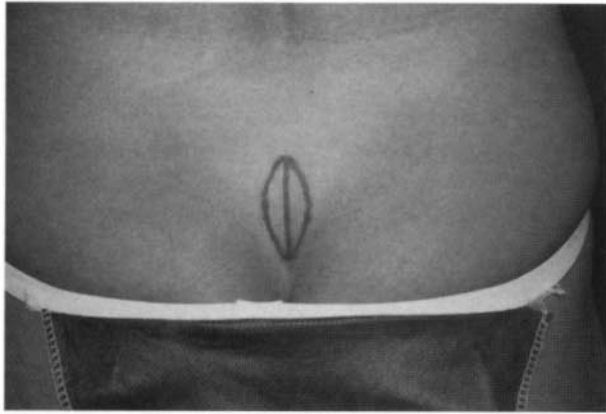


Fig. 1. Pre-op markings.

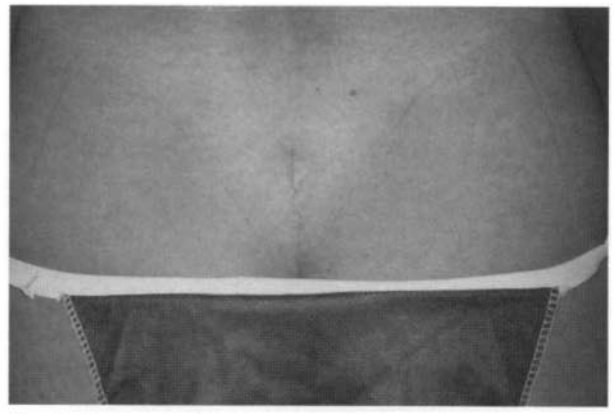


Fig. 2. Post-op incision.

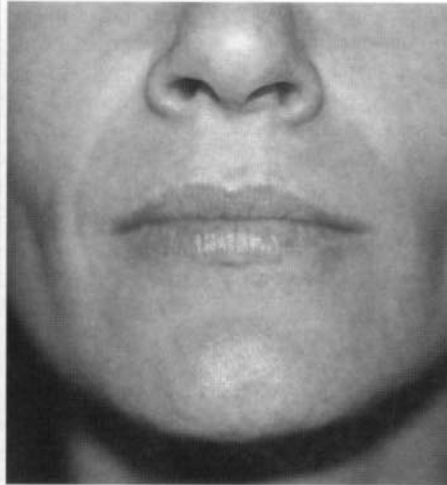
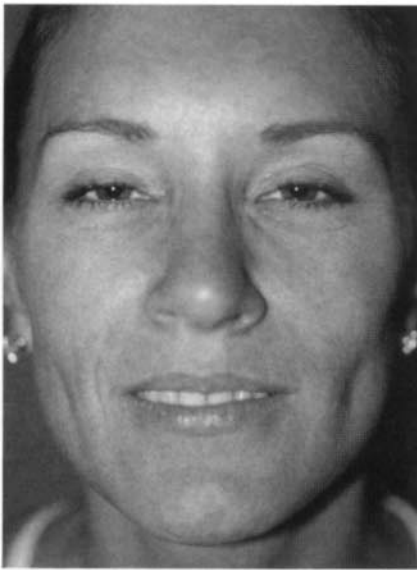

Fig. 3. Pre-op.

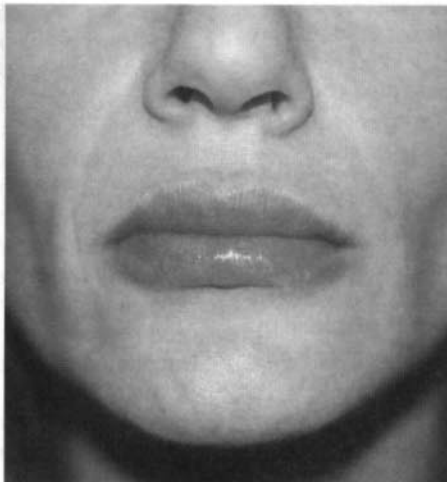
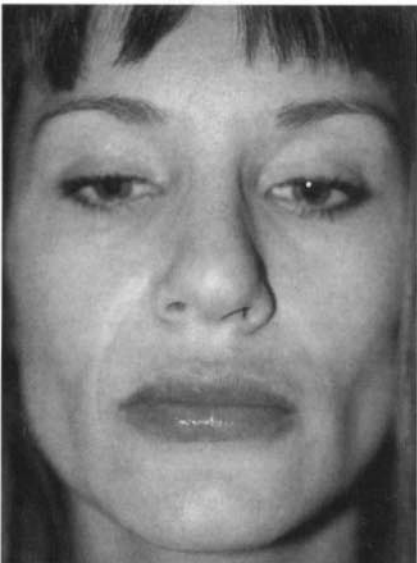

Fig. 4. Three months post-op.

and rather quickly. V-Y advancement flaps for lip augmentation have been utilized with some good success, however, there appears to be only a modest augmentation and significant scarring within the lips.

Living autogenous grafts have been used to enhance facial defects since the turn of the century. In 1914, Lexer [1] utilized free dermis to repair nasal defects, and in 1920 Eitner [2] utilized free dermis to enhance buccal defects. Shortly after, in 1931, Figi [3] described the use of free dermal fat grafting (FDFG) for correction of a depressed frontal sinus fracture. This was the earliest report of FDFG in the American literature. Since then, numerous clinical and histological studies have demonstrated the efficacy of FDFG in recontouring of facial defects [4–8]. There are several obvious advantages of FDFG over other tissue fillers such as alloplastic materials. Dermal fat grafts are completely histocompatible and therefore are free from foreign-body reactions. Since they revascularize, dermal fat grafts have a good long-term viability and are more resistant to infections. Furthermore, the inherent properties of the tissue make it soft and pliable for easy sculpting. Although free from volume loss, alloplastic materials are firm and produce an obvious discrepancy in texture and feel that is unacceptable in delicate structures such as the lips.

Despite these advantages, some surgeons are reluctant to use FDFG because of potential complications such as donor-site morbidity, graft resorption, and epithelial cyst formation. A desirable donor site should have minimal hair and a thick dermal component and leave an inconspicuous scar. The most commonly utilized donor sites have included the suprapubic abdomen, groin crease, and buttock. The problem with these sites is that in order to avoid hair-bearing skin, a visible scar is often produced. The suprapubic area has a disadvantage in patients with a high pubic hair line in which removing the hair follicles is quite difficult. The presacral region is an optimal donor site because the skin is thick, has minimal hair follicles, and can tolerate an incision well. A vertically oriented incision in this area heals quite well and even the skimpiest undergarments cover it (Fig. 2).

Graft resorption is also a common concern. As with all autologous fillers, there is varying degrees of resorption. Free fat grafts provide adequate bulk but resorb very quickly. In our experience, FDFG provided the longest-lasting effects with the right amount of bulk (Figs. 3 and 4). The variation in resorption is not clearly understood. A high dermis-to-fat ratio appears to decrease resorption. We have found that the optimal graft thickness is a dermal width of 1.0 and 1.5 cm. A study by Stark demonstrated that dermal fat grafts larger than 1.0 cm in thickness resulted in excessive resorption [9]. Conley and Clairmont also noted that the larger grafts resorbed more

extensively compared to smaller, more vascularized grafts [10].

An infrequent complication encountered with FDFG is epithelial cyst formation secondary to retained epithelial elements. Although clinical evidence of epithelial cyst formation is rare [4–8,10], careless deepithelialization technique and poor donor-site selection can increase the risk of cyst formation. The lack of coarse hair in the presacral region make it a desirable donor site.

Conclusion

Although many types of lip augmentation procedures have been described, the optimal result with the fewest disadvantages still appears to be the dermal fat graft. With meticulous deepithelialization technique, appropriate graft size, and wise donor-site selection, many of the once-concerning complications of dermal fat grafting can be avoided. The sacral area is an excellent choice for a donor site because it provides excellent graft material and the scar is inconspicuous.

References

1. Lexer E: Free transplantation. *Ann Surg* **60**:164, 1914
2. Eitner E: Cited by: Thompson N. The subcutaneous dermis graft: A clinical and histologic study in man. *Plast Reconstr Surg* **26**:1, 1960
3. Figi FA: Depression of frontal region, fat transplant. *Surg Clin North Am* **11**:8, 1931
4. Thompson N: The subcutaneous dermis graft: A clinical and histological study in man. *Plast Reconstr Surg* **26**:1, 1960
5. Schuessler WW, Steffanoff DN: Dermal grafts for correction of facial defects: a series of 80 cases. *Plast Reconstr Surg* **4**:341, 1949
6. Boering G, Huffstadt AJC: The use of dermal-fat grafts in the face. *Br J Plast Surg* **20**:172, 1967
7. Leaf N, Zarem HA: Correction of contour defects of the face with dermal and dermal-fat grafts. *Arch Surg* **105**:715, 1972
8. Davis RE, Guida RA, Cook TA: Autologous free dermal fat graft: Reconstruction of facial contour defects. *Arch Otolaryngol Head Neck Surg* **121**:95, 1995
9. Stark RB: Free transplants. In: Plastic surgery. Harper & Row: New York, Chap 5, 1962
10. Conley JJ, Clairmont AA: Dermal-fat fascia grafts. *Otolaryngol Head Neck Surg* **86**:641, 1978
11. Peer LA, Paddock R: Histologic studies on the fate of deeply implanted dermal grafts. *Arch Surg* **34**:268, 1937
12. Swenson SA: Cutis grafts: Clinical and experimental observations. *Arch Surg* **61**:881, 1950
13. Sawhney CP, Banerjee MB, Chakravarti RN: Behavior of dermal fat transplants. *Br J Plast Surg* **22**:169, 1969