

# Inferior Pedicle Technique in Breast Reduction: Basic Concepts

## INDICATIONS

Indications for breast reduction, regardless of the technique is used, include (a) self-identification of problems, (b) referral from another health care provider, and (c) issues of symmetry related to a lumpectomy or mastectomy for contralateral breast cancer.

Because of the wide dissemination of knowledge facilitated by the proliferation of health-related websites, prospective patients are often able to self-diagnose the cause of the stereotypical symptom cluster of macromastia. By surfing plastic surgeons' websites, a woman seeking breast reduction will often have gained a reasonable fund of knowledge regarding the benefits that breast reduction may offer. She is likely to become well educated about the range of techniques being offered, the likely functional and cosmetic outcomes, and the expected aesthetic shape. It is, of course, the in-person surgical consultation with an appropriately trained and credentialed plastic surgeon that can help to confirm the diagnosis, clarify the patient's do-it-yourself understanding, and correct any misinformation that the woman may have received. Some women are free of physical symptoms and seek breast reduction solely for aesthetic purposes, yet all women want an aesthetically proportioned breast shape delivered along with volumetric reduction.

Other women are referred for a plastic surgery consultation from their primary care physician, gynecologist, chiropractor, or spine specialist for conditions such as symptoms of back pain, neck pain, shoulder grooves, breast pain, intertrigo in the inframammary folds (IMFs), inability to exercise or participate in sports, or inability to fit into clothes. Most have failed some attempt at conservative management, such as physical therapy, exercise, weight loss, massage, or nonsteroidal anti-inflammatory drugs (NSAIDs). Attempts at weight loss are a "catch-22": Inability to exercise because of neck, back, and shoulder pain impedes their ability to lose weight, and thus the macromastia persists. Since the underlying problem of large, pendulous breasts remains uncorrected, it does seem illogical that conservative measures would suffice: Such women would have to undergo lifelong physical therapy or lifelong NSAIDs and be at risk for their adverse renal and gastric effects (1,2).

Given the high incidence of breast cancer in North American women, many patients undergo a lumpectomy followed by radiation therapy. This leads to fibrosis, breast volume loss, and contraction of the breast. Alternatively, if a woman has had a unilateral mastectomy followed by reconstruction (autologous or prosthetic based) that tends to have less ptosis and is smaller because of limitations in donor-site availability, the normal, unoperated breast will continue to age and have more ptosis and be larger. Hence, women may seek a unilateral breast reduction to match a side that has been treated for cancer.

## CONSULTATION

A detailed history is obtained to ensure that the patient is suitable for surgery from medico-surgico-psychosocial perspective. A notable family history of breast cancer should be worked up for genetic susceptibility (BRCA testing). This may precipitate bilateral mastectomy and immediate reconstruction instead of bilateral breast reduction. Mammograms are obtained as necessary to bring them up to date with current guidelines for baseline mammography and screening for breast cancer. American Cancer Society guidelines recommend a baseline mammogram at age 40 years and annually thereafter for women of average risk. Any detected anomalies should be referred to a breast oncologic surgeon to ascertain need for biopsy, imaging, or deferring of surgery to observe any suspicious radiographic abnormalities over time.

During the consultation process, measurements are undertaken for both the medical record and for third-party payer coverage criteria documentation. Typically, height, weight, sternal notch-to-nipple distance, and nipple-to-IMF distance are recorded bilaterally, and discrepancies in IMF and nipple-areolar complex (NAC) positions are pointed out to the patient. The degree of ptosis (none, mild, moderate, or severe) is assessed. During the focused breast exam, the breasts are screened for masses or nodules, axillary lymphadenopathy is checked, and the skin is examined for ulcerations, erosions, or postinflammatory hyperpigmentation. Nipple discharge is ruled out, and NAC size is noted (small, average, or dilated). Standard-view photography of the patient is done.

Lalonde breast sizers or a water displacement technique can be used to estimate the volume in each breast (3). With newer digital imaging technologies, it may be possible to estimate the volume from stereophotography.

Current bra size is elicited, and the desired cup size is discussed with the patient. Patients do not always understand the bra sizing system, and some request going from a 38DD to a 32B, for instance. The band size usually will not change (unless axillary liposuction is also done) since this reflects the underbust chest circumference. Ranges for volume resection that correlate with each one-cup-size reduction are from 200 to 350 cc, with little consensus. Some heavy-set women request a small breast cup size and should be counseled about choosing a cup size that is proportional to their overall body habitus. Lastly, cup size serves as a lay parlance discussion tool only. Cup sizes vary significantly by bra manufacturer, and these are not medical measurements. They serve as general guideposts to facilitate dialogue about a woman's desired target size.

The volume to be resected in each side, which may be different based on preexisting asymmetries, is estimated. Broad generalizations suggest that approximately 200 to 350 g is required for each one-cup-size change, and that each 1 cm of

asymmetry in NAC position between the breasts accounts for 100 g of breast volume asymmetry. Most insurance companies establish volume requirements of breast tissue to be resected to reimburse for the procedure. While there are many variations, some third-party payers require 500 g of resection at least. Other companies use a nomogram based on height and weight to determine how much breast tissue needs to be removed to be eligible for reimbursement.

## INSURANCE SYSTEMS

Preauthorization from insurance companies is sought with a copy of the consultation and the foregoing measurements, photographs of the torso in frontal and lateral views, and International Statistical Classification of Diseases and Related Health Problems-9 (ICD-9) and Current Procedural Terminology (CPT) codes. The ICD-9 codes frequently used in conjunction with breast reduction symptomatology are 611.1 (breast hypertrophy), 611.71 (breast pain), 692.9 (intertrigo), 724.8 (symptoms referable to back), 724.1 (back pain), 723.1 (neck pain), 723.9 (shoulder pain), 738.3 (shoulder grooves), and 709.0 (dyschromia). The CPT code is 19318-50. (Breast reduction preformed unilaterally to correct asymmetry with a reconstructed postmastectomy breast is covered by insurance without regard to size and volume criteria, as mandated by the Women's Health and Cancer Rights Act of 1998.)

When coverage for breast reduction is denied, an appeal letter may be considered, reminding the payer that recent scientific literature and evidence-based studies published in peer-reviewed journals strongly support the position that women undergoing reduction mammoplasty for symptomatic breast hypertrophy experience significant improvement in their preoperative signs and symptoms. Managed care organizations rate outcome or cost-effectiveness analyses as the most important factor in determining reduction mammoplasty coverage policies (4).

The plastic surgeon's office can often facilitate the appeal process, but the ultimate responsibility rests with the patient. The objective, ethical, and honest account of the patient's health care problem is captured in the office consultation note prepared by the physician, and a copy may be provided directly to the patient, supplemented with photographs. The patient may be encouraged to contact her payer or employer directly about her dissatisfaction. Some women will pay for services out of pocket in the face of denial and/or use their flexible health savings accounts to fund the surgery.

## PREOPERATIVE DISCUSSION

After a thorough medical history and physical exam, the patient is screened for outpatient surgery. Smoking or second-hand smoke exposure must be stopped for 6 to 8 weeks prior to surgery. Nicotine exposure via gum or patch is also eliminated. A newer, non-nicotine-containing medication, varenicline, may be initiated. Patients should additionally remain free of tobacco smoke and nicotine for the postoperative healing period of at least 6 weeks. Weight loss, if indicated, is desirable to get closer to ideal body weight, but this is frequently unrealistic, as discussed earlier.

Preoperative testing is directed by medical history, physical findings, and age per anesthesia criteria. Young, healthy women may not need any testing except for a history and phys-

ical examination. Those with medical illnesses may need a complete blood count, electrolytes, liver function tests, pulmonary function tests, chest x-ray, and/or electrocardiogram. Those with a significant cardiopulmonary history should be cleared by their internist or cardiologist.

The patient is instructed to stop medications that predispose to a bleeding diathesis, such as NSAIDs, aspirin, salicylic acids, and over-the-counter medications that may contain these ingredients. Herbal medications and vitamin supplements, especially in large doses, are also eliminated. In particular, vitamin E, ginkgo biloba, St. John's wort, and garlic are to be discontinued.

Estrogenic medications such as oral contraceptive pills (OCPs) and postmenopausal hormone replacement therapy should be discontinued to lower the risk of deep vein thromboses (DVTs) and venous thromboembolism (VTE) associated with surgery. Patients on OCPs should practice an alternate form of contraception in the preoperative and postoperative interval because OCPs (even when not discontinued) may have decreased effectiveness due to metabolism of other medications during the episode of surgical care.

During the consultation, the patient and her significant others are educated regarding the risks and benefits of breast reduction surgery, as well as the alternative techniques available such as (a) no surgery and attempt at weight loss, (b) breast liposuction, (c) periareolar incision, (d) a vertical pattern or short-scar procedure, (e) a transverse scar (Passot) procedure, or (f) Wise-pattern breast reduction.

Having no surgery and seeking reduction in breast size through exercise and weight loss is also a possibility, especially if the patient can achieve a weight loss to get to a normal body mass index (BMI). She may then be reevaluated at some future date to see whether she still needs a breast reduction or only a mastopexy. Breast liposuction may be successful in decreasing one or two cup sizes for some women with moderate hypertrophy without mild to moderate ptosis and should be considered. Liposuction does not address NAC ptosis and may worsen it. Periareolar techniques may have a role in mild hypertrophy but remain technically challenging and unpredictable. Vertical or short-scar reduction has the advantage of eliminating the transverse IMF scar; however, this has a 15% to 20% revision rate with possible future or intraoperative conversion to a Wise pattern or J or L scar. These breast reductions do not achieve their optimal shape right away and do so over time. This is less likely to have bottoming out or parenchymal maldistribution (pseudoptosis). The transverse scar technique is typically used with a superomedial or superior pedicle and/or with free nipple graft. However, the inferior pedicle reduction technique can be used with the transverse scar.

The Wise skin pattern is most commonly associated with the inferior pedicle breast reduction technique. This incision pattern can be used, however, with superior or superomedial pedicle techniques, as well as with free nipple grafts. Nevertheless, the Wise or inverted-T scar technique is most commonly associated with the inferior pedicle technique. The inferior pedicle breast reduction in combination with the anchor T incision remains the most popular method of breast reduction and is the most predictable (5). Approximately 75% of plastic surgeons in the United States use this technique, and approximately 50% of surgeons use this technique exclusively. It is the most versatile and has a straightforward learning curve. It bears emphasizing that pedicle and skin pattern can be chosen independently of each other in most, but not all, scenarios.

## CONSENT

The written informed consent is a supplement to the patient education process that occurs during the consultation. It should cover the risks including, but not limited to, infection, bleeding, hematoma, seroma, wound dehiscence, delayed healing, poor healing, and swelling. The patient is told about the potential for scarring, such as keloids, hypertrophic scar, hypopigmentation or hyperpigmentation, and dark or pink, itchy, or tender scars, which may be visible outside or through garments. Adverse sequelae include asymmetry, numbness, stiffness, pain, chronic pain, or anxiety and/or depression related to changes in body image. The patient is informed of the chance for further unplanned surgery with its additional risks, financial responsibilities, and time required for surgery and recuperation. Potential hospitalization may not be covered by insurance, since most reduction mammoplasties are done as outpatient cases at ambulatory surgery centers.

Urine pregnancy tests are recommended. If the woman is pregnant, she could be exposed to medications and anesthetics that cause birth defects or miscarriages.

There is the potential, but fortunately extremely rarely, for blood transfusion with major surgery and the accompanying risks including bacterial and viral infection (e.g., HIV, hepatitis) and transfusion reaction. There may be partial or total flap and tissue loss, fat necrosis, and loss of skin or of the NAC. Incomplete relief or no relief of the symptoms (e.g., back pain, neck pain) may occur, or the patient may be dissatisfied with the results of the surgery. No guarantee can be made of fitting into a particular clothes size or bra cup size or to match a digital simulation. Any surgery of the breasts leads to scars, both internal and external, and hence may hinder cancer surveillance and detection efforts. Magnetic resonance imaging may be required instead of mammograms for follow-up of calcifications from surgery.

Those patients who travel a great distance to a particularly well regarded surgeon may incur higher risks associated with traveling soon after surgery (e.g., flying, driving) such as DVTs or pulmonary embolisms from immobility in a confined car or airplane.

Comorbidities must be addressed in the informed-consent process as well. For instance, obesity and diabetes (controlled or uncontrolled) may contribute to poor healing and raise the rates of infection. After discussing best-case, worst-case, and average outcomes and scenarios and looking at representative photographs/diagrams, the patient and her family should feel comfortable that they grasp the likely benefits and potential for untoward events. They must understand the diagnosis, medical necessity versus elective nature of the surgery, goals of the procedure, pain management, expected time course of recovery and management of complications should they arise, and warning signs and symptoms of complications. Patients are provided sufficient time to consider the procedure in depth and should demonstrate their comprehension by being able to relate the information back to the surgeon and voice their understanding of the procedure in plain, lay language.

## CAUTIONS AND CONTRAINDICATIONS

One contraindication is recent postpartum state in which breast size is still changing and has not reached an equilibrium

plateau from involution. Active lactation is similarly a contraindication to breast reduction.

Age must be considered as well. With earlier and earlier age of thelarche and menarche in Western women, teen-aged girls are encountered with greater frequency with symptoms of macromastia, some of which is related to higher obesity rates in teens. The decision must be tailored to the physical findings, expected future growth, maturity level, and willingness to accept the potential for a repeat reduction mammoplasty in the future. There are no absolute age-related criteria, and the decision to operate is multifactorial.

Prior irradiation for breast conservation therapy (BCT) after lumpectomy is not a contraindication but should be given due consideration, as it may precipitate the need to alter the surgical plans. If an inferocentral lumpectomy has been performed, then the vascularity for an inferior pedicle reduction may not exist, and the plan should be changed in favor of an alternate pedicle. Radiation, independent of the lumpectomy site, will lead to slight modification of the surgical plans. For instance, the skin brassiere is not undermined widely, and, in general, more conservative markings are used.

Similarly, a prior breast reduction may be a contraindication to an inferior pedicle technique. Previous operative notes should be obtained when practical, since the inferior pedicle may have been resected during the surgery. Even if the prior reduction was an inferior pedicle procedure, the risks of injury to the pedicle and consequent loss of the NAC are nonetheless possible (6).

Diabetes, as a disease that compromises microvascular circulation, poses a challenge in breast reduction surgery. In this situation, as for radiation, the skin brassiere is not undermined as widely, pedicle width is enlarged, and longer distances for NAC are not transposed. Failure to modify the markings and extent of the reduction can contribute to higher rates of fat necrosis, NAC necrosis, and skin necrosis, particularly at the T junction.

Active smoking is a contraindication. Patients are insisted to be tobacco and nicotine free for a period of several weeks prior to surgery. This includes abstinence from nicotine gum or patch and from second-hand-smoke exposure. Urine cotinine tests may be indicated to encourage compliance. Urine cotinine tests are reported to detect tobacco use as recent as 2 to 10 days. Rarely, a carboxyhemoglobin test is indicated from an arterial blood gas sample in the preoperative holding area. Despite efforts to persuade and educate patients into smoking cessation for their own benefits, noncompliance is often encountered. Even with compliance, higher rates of complications are expected because of the aggregate toll that smoking has taken on their tissues.

A high BMI is not an absolute contraindication but may contribute to an overall anesthesia or surgical contraindication. The goal of getting patients into a 10% to 15% range of a normal BMI is not realistic. These patients find it impossible to exercise and thus difficult to lose weight precisely because the symptomatic macromastia makes them unable to exercise.

Very large reductions or those with dramatic ptosis and long sternal notch-to-nipple distance risk devascularizing the NAC and should be handled with a free nipple graft technique rather than an inferior pedicle procedure.

When several of these cautionary findings are found in conjunction, such as a diabetic patient who smokes or a previously radiated patient who also smokes, the surgeon must consider delaying the surgery until one or several factors can be optimized or mitigated.



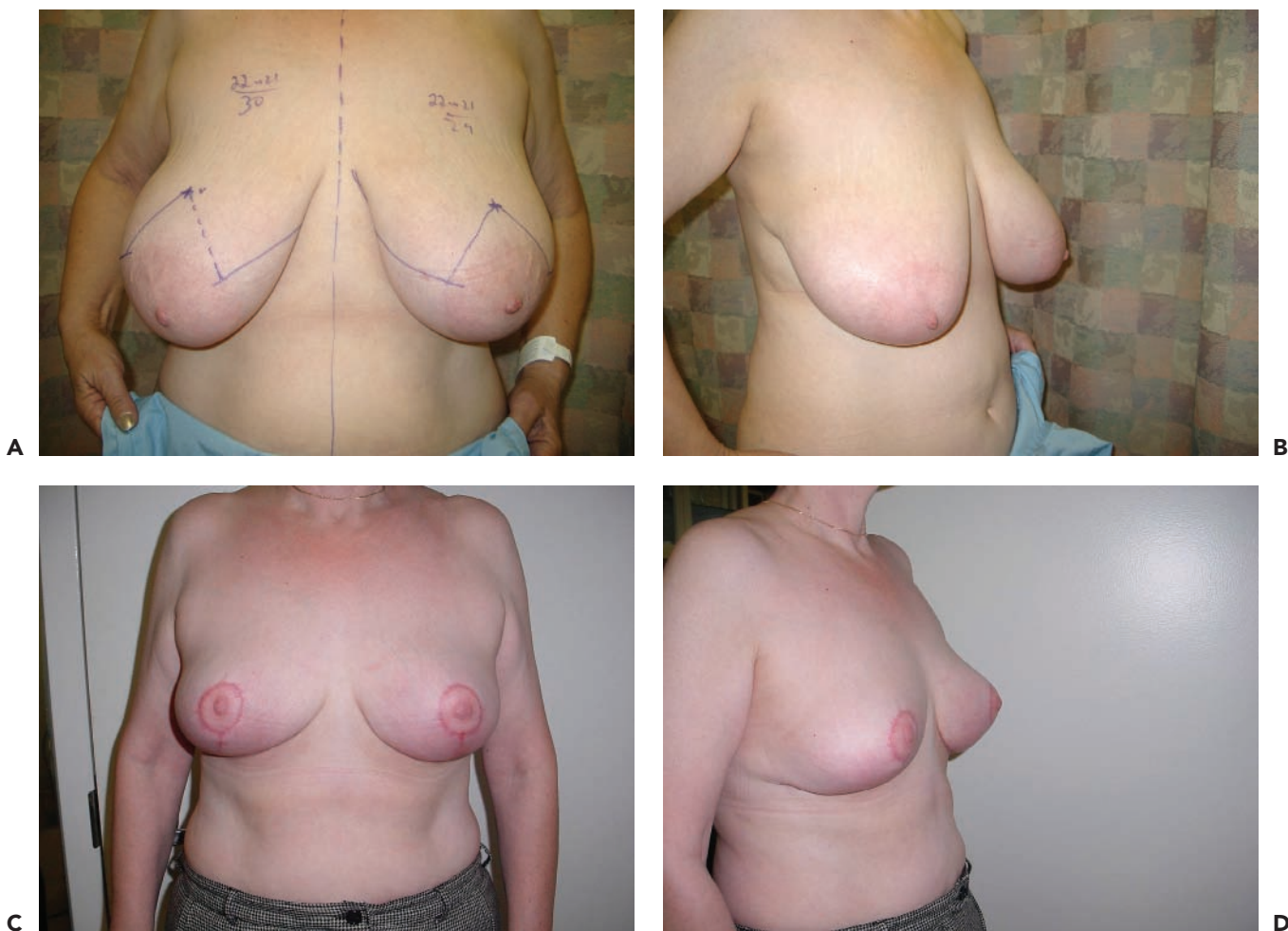## MARKINGS

Markings, which determine the entire operation except for some minor intraoperative adjustments, are done with the patient standing upright with arms adducted. Shoulders are placed squarely, and a midline reference line is drawn from the sternal notch to the umbilicus. Existing scoliosis and kyphosis of the spine and asymmetries are demonstrated to the patient. The IMFs bilaterally are drawn with an indelible surgical site marker. The IMFs are typically 21 to 25 cm from the sternal notch and about the level of the midhumeral point.

The midbreast lines are drawn vertically through the nipple to the IMF with the breast weight gently supported to decrease stretch traction on the supra-areolar skin. Obstetric calipers may be used to transpose the level of the IMF onto the anterior supported breast skin, or this can be done through bimanual palpation. The new nipple position is determined by placing a finger in the IMF and marking the anterior projection on the vertical midbreast line. This mark is confirmed against several landmarks, including the midhumeral point, or within a range of 18 to 24 cm from the sternal notch, and in comparison to the contralateral side.

Once the provisional neo-NAC position is chosen, two oblique lines (which, when closed, will be the vertical limb of the T incision) are dropped to make an inverted V. The vertical limbs are set to 4.5 to 7 cm to allow for future bottoming out. The limbs may be drawn with the assistance of an NAC template such as a McKissock keyhole pattern. The angle of divergence of the vertical limbs (which form an inverted V) is determined by the skin excess, as judged by pinching the excess skin. The greater the amount of skin, the wider the V will open. At a first approximation, the limbs of the V should be tangent to the NAC since the dilation of the NAC is typically proportionate to the degree of hypertrophy. When in doubt, one should make the V narrow since more skin can be excised during the tailor-tack phase. If too much skin is resected, then primary closure may not be possible—a mistake to be avoided.

Finally, a horizontal line is drawn from the inferior end point of the vertical lines to the IMF. They need not extend all the way to the medial extent or the lateral extent of the breast—a pearl gleaned from experience with the vertical-only approach. The horizontal lines meet the IMF at 1 to 4 cm from the lateral sternal border and roughly at the lateral limit of the breast crease (Fig. 94.1).



**Figure 94.1.** A: Preoperative sternal notch-to-nipple distance is 30 cm on the right and 29 cm on the left. The inframammary fold is at 22 cm bilaterally and the neo-nipple-areolar complex will be sited at 21 cm bilaterally. B: Oblique view. C: Postoperative result at 3 months, frontal view. D: Postoperative result at 3 months, oblique view.

## OPERATIVE DETAILS

The patient is scheduled as an outpatient procedure for 2 to 3 hours and admitted to the hospital only if necessary. Criteria for conversion to in-patient or 23-hour observation unit include presence of medical comorbidities, high blood loss, long surgical duration, uncontrolled postoperative pain, and intractable postoperative nausea and vomiting.

In accordance with the Joint Commission on the Accreditation of Healthcare Organizations guidelines for surgical infection prevention, preoperative antibiotics targeted at skin flora for a clean case are administered intravenously within 60 minutes prior to incision. They are discontinued 24 hours after surgery. First-generation cephalosporins are most commonly indicated in the non-penicillin-allergic patient to minimize surgical site infections.

[AU1]

Venodynes should be applied and activated prior to the induction of anesthesia. Chemoprophylaxis for VTE is administered when the patient is considered at elevated risk for DVT. Unfractionated heparin, low-molecular-weight heparins such as enoxaparin or dalteparin, or synthetic antithrombotics such as fondaparinux may be administered preoperatively and continued postoperatively for chemical prophylaxis of thrombotic events (7).

The patient is positioned supine with arms abducted to approximately 90 deg in a well-padded and cushioned fashion. A lower-body warmer is used to maintain normothermia during the operation.

General anesthesia is commonly used via an endotracheal tube, a laryngeal mask airway, or total intravenous anesthesia with agents such as propofol, midazolam, and fentanyl. Alternate techniques include spinal anesthesia or intravenous sedation with local anesthetics. When intravenous sedation is used as for anesthesia, infiltration of local anesthetics as a field block is requisite (8). However, even when general anesthesia is employed, a local field block or intercostal blocks with the addition of tumescent anesthesia may help to provide long-lasting postoperative pain relief and thus minimize use of postoperative narcotics. Some surgeons place indwelling catheters with pain pumps for postoperative pain management. Some surgeons use tumescent infiltration (dilute lidocaine and dilute epinephrine solution) for the additional benefit of hydrodissection and local hemostasis.

Assistants at surgery are used to help retract, suction, and expedite wound closure, thus minimizing the operative time and anesthetic experience. A smoke evacuator may be used during the surgery to minimize the smoke plume associated with the electrocautery.

The planned pedicle is an 8-cm-wide area centered about the breast meridian originating at the IMF and continuing to the level of the NAC. For larger reductions, the width should be increased to 10 cm. The pedicle is deepithelialized except for the NAC, which is left intact as a 42- or 45-mm-diameter circle. The NAC can be cut as a perfect circle using a Freeman cookie cutter, or small undulations and imperfections (like a running W-plasty) are tolerated to mimic a more natural NAC. The superior skin flap is elevated to reveal the underlying breast parenchyma. An omega- or horseshoe-shaped excision of parenchyma is performed, leaving a broadly attached, 8-cm-wide pedicle originating at the IMF and continuing to the level of the NAC. The pedicle that remains is vascularized by branches from the lateral thoracic, internal mammary, and intercostals vessels.

This excises tissue from the medial, superior, and lateral quadrants of the breast. Some prefer to resect tissue from each area separately, which is not as efficient as an en bloc excision but affords the opportunity to compare and shape each region more selectively. Medially, the tissue must not be overresected, so as to optimize cleavage. A layer of loose areolar tissue should be left on the pectoralis fascia to preserve the nerves traveling in this plane. The specimen from each side is separately labeled and weighed.

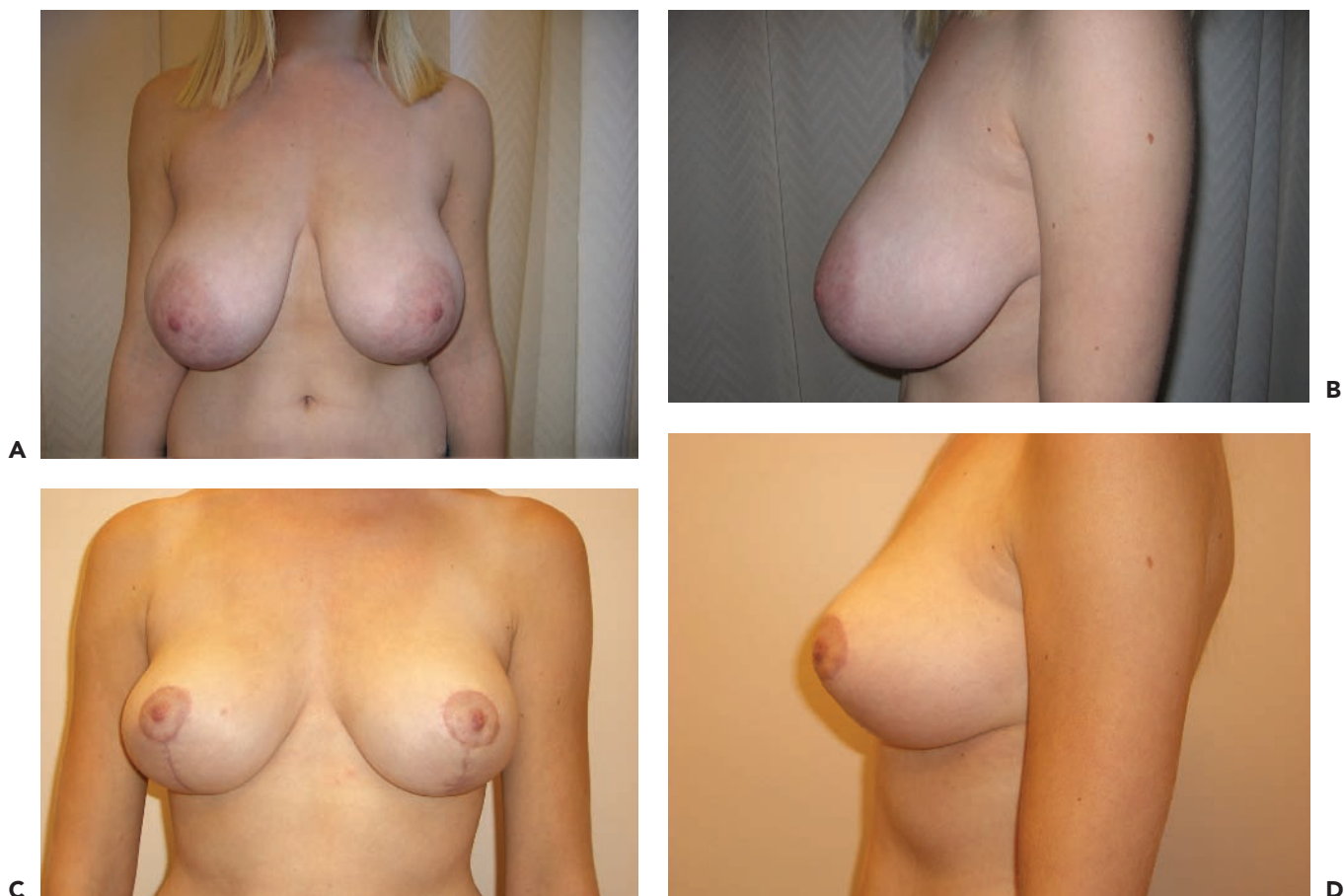Finally, a tailor-tack method is used to shape the breast. The surgeon shapes the breast by transposing the pedicle cephalad and supporting it with medial and lateral breast flaps. Skin staples or provisional sutures are used to create guidelines for closure. Then the patient is sat up intraoperatively, and size, shape, and symmetry are assessed. If the desired target size is not reached, additional piecemeal tissue may be excised from the pedicle or from the surrounding flaps. Differential resection is undertaken from each breast to account for preexisting asymmetries in size. Symmetry must be assessed, and if asymmetry exists, additional tissue may be excised unilaterally. Sterile Lalonde sizers may be used intraoperatively to judge symmetry of retained volumes. Once the desired volume of resection to achieve the requested bra cup size is achieved, the specimen may be sent to pathology, individually labeled for left and right sides. A request to use intraoperative weights is sent with the specimens to pathology since there may be some volume loss related to specimen desiccation postoperatively.

The remaining pedicle and flaps are finally assessed for adequacy of vascularity. Healthy uniform punctuate arterialized bleeding should be confirmed from the deepithelialized pedicle and its edges. The NAC should have good turgor and demonstrate contractile areolae. If there is a question, it may be pin pricked with a 25-gauge needle to assess pink bright bleeding. Rapid, dark congested blood suggests venous insufficiency. Another technique is to administer intravenous fluorescein and inspect the surgical site with a Wood ultraviolet lamp and to visualize fluorescence along all concerning areas to assure viability and vascularity.

All areas are irrigated with warm saline, and hemostasis is meticulously confirmed. Electrocautery is typically used for the smaller vessels, but suture ligation of larger vessels may be needed.

Shapes are optimized by advancing the medial and lateral skin flaps to help shape the breast parenchyma. In addition, the flap is advanced superiorly, and shaping sutures may be used to create a fuller central mound that is less dependent on skin support. This shaping technique is less effective in the setting of fatty breasts and has better outcomes with breasts with a greater glandular component that can hold suture. The patient is sat up again, and the positions for the neo-NAC are chosen. They should be placed at the point of maximal breast projection at a distance of 5 to 7 cm from the IMF. In larger breasts, one must be careful not to let the NAC fall too laterally or too high. If skin quality is poor, one can anticipate some future "bottoming out" or pseudoptosis and place the NAC a little lower. Once the neo-NAC is marked with a cookie cutter, the 38- to 45-mm-diameter circle of skin is excised, and the NAC is exteriorized and anchored with 3-0 inverted Vicryl suture. See Figure 94.2.

NAC viability should be assessed at this point. If there is good 2-second capillary refill with neither sluggish nor brisk refill, then closure is continued with 4-0 monofilament



**Figure 94.2.** A: Preoperative view with markings. Note the deep shoulder grooves. In larger breasts, the nipple must be moved more medially. B: Postoperative view with hypertrophic scars.

Au: Caption not match with Fig. pls. check.

absorbable suture. If there is a question of viability at this point, the sutures should be realized, and the wounds inspected for hematoma causing pressure on the flap, kinking of the pedicle, or undue tension from a tight skin closure. If correcting these potential causes of vascular insufficiency to the NAC does not restore vascularity, the NAC should be harvested as a full-thickness skin graft. After defatting, it can be grafted onto a deepithelialized circle on healthy breast skin flaps.

Drain use varies widely. Some surgeons use no drains, others use them only overnight, and some use them for a week or until drainage is lower than approximately 30 cc per 24-hour period. There is no difference in hematoma, seroma, or overall complication rates with or without drain use (9).

Concomitant axillary liposuction may be undertaken during breast reduction as an adjunct technique. This may not be covered by insurance, and prior arrangements should be made by the patient to address any fees for the surgeon, facility, or anesthesia associated with this. Liposuction may decrease the chest wall diameter by several inches, allow for better contouring of the lateral breast, and help prevent dog-ears in the incisions. It permits better-fitting brassieres postoperatively and can address unsightly bulges toward the lateral chest wall. Superwet technique employs infusion of

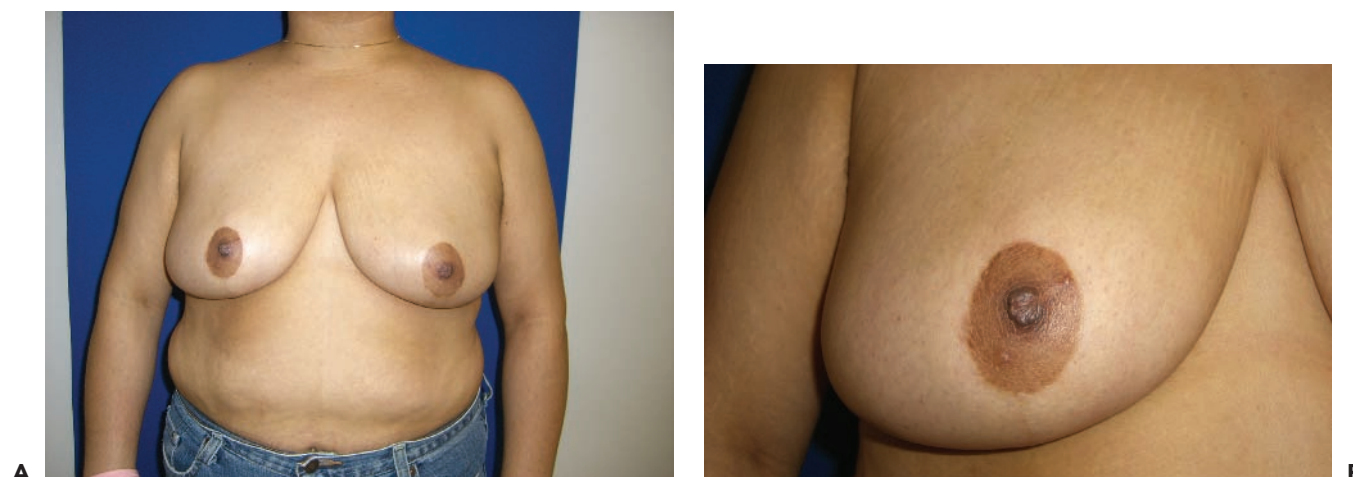tumescent solution in a proportion of approximately 1:1 or 2:1 with the anticipated volume of aspirate. A traditional or power-assisted cannula in the 2- to 4-mm range is used to aspirate fat in a smooth, graduated, and tapered fashion to contour the lateral chest. Ultrasonic or laser energy is typically not needed in this soft fat. The portal for liposuction may be placed through a separate stab incision that might be repurposed for a drain exit site (if one is used), or the cannulas may be placed from within the breast reduction incisions, thus minimizing additional scars.

Final closure of all incisions is typically with 3-0 Monocryl deep-dermal and 4-0 Monocryl subcuticulars. The NAC may be closed with running 6-0 fast-gut. Incisions may be dressed with surgical adhesive glue or Steri-Strips. After dry, sterile dressings are applied, the patient is then placed into an appropriate-sized surgical bra for support.

## POSTOPERATIVE CARE

Antibiotics are stopped 24 hours after surgery. Oral narcotic analgesics are continued as necessary—typically 1 week—and then NSAIDs can be initiated for both analgesia and as an anti-inflammatory. Postoperative nausea and vomiting are managed





**Figure 94.3.** A: Frontal view, preoperative. B: Lateral view, preoperative. C: Frontal view, 6 months postoperative, glandular shaping sutures used to avoid bottoming out. D: Lateral view, postoperative.

Au: Caption not match with Fig. pls. check.

with antiemetics as needed. Hydration and stool softeners can mitigate the constipative effects of narcotics.

Patients are allowed to shower after 48 hours, with or without drains. Steri-Strips may fall off by themselves at this stage.

Patients should be active and ambulating on the night of surgery and may increase to brisk walking in 3 to 5 days postoperatively. Running and other jarring motions should be avoided for 4 to 6 weeks postoperatively, but elliptical machines or stationary bicycle work can be started in 2 weeks. Patients are dissuaded for lifting objects greater than 10 lb for 2 to 4 weeks. After 6 weeks they may resume more strenuous aerobic work and lifting activities as tolerated.

Scar management and optimization is begun at about 4 weeks after surgery. Silicone gel sheets can afford better scars, as can scar massage with creams or vitamin E oils. See Figure 94.3. Gentle massage of scars and breasts is encouraged at 3 to 4 weeks to help scars mature, as well as to desensitize scars and encourage return of skin sensibility. Areas of prolonged numbness (such as the lateral chest after liposuction) tend to be perceived by patients as “fat,” much as a numb lip after a dental block tends to feel fat. Warm compresses may be applied, with the caveat that an insensate area can suffer a burn if compresses are too warm or applied for too long an interval. Patients return to the use of a normal bra or camisole at 4 weeks.

## COMPLICATIONS

While major complications are unusual, minor complications are frequent. Small areas of delayed healing are frequently identified at the T junction at the level of the IMF, and these heal with local wound care such as antibiotic ointment (e.g., bacitracin) and a Band-Aid. For larger areas of skin loss, wet to dry gauze dressings may be prescribed. If a dry eschar forms, it may be treated with silver sulfadiazine 1% topical ointment twice daily until it separates. Rarely, larger areas of full-thickness skin loss may need operative debridement and closure with a negative-pressure device (vacuum-assisted closure) or, rarer still, with a skin graft.

If a hematoma occurs, it may be observed if it is small, noninfected, and not compromising the skin. The risk of developing calcifications around the hemorrhage exists. A hematoma may be needle aspirated—a liposuction cannula is particularly effective. For larger hematomas, operative evacuation and hemostasis are indicated. Seromas should be needle aspirated (10).

Superficial infection can be treated with oral antibiotics, but if significant or if the patient becomes systemically ill, intravenous antibiotics are recommended in an inpatient setting. The need to debride is unusual.

Dog-ears may develop in the lateral breast area and are touched up under local anesthesia with elliptical excision. Hypertrophic or keloid scars may need revision once the inciting etiology (tension during closure) is removed. They may also be treated with injections of triamcinolone. Lasers may be used. Off-label intralesional injections of antineoplastic agents such as 5-fluorouracil have also been reported. See Figure 94.4.

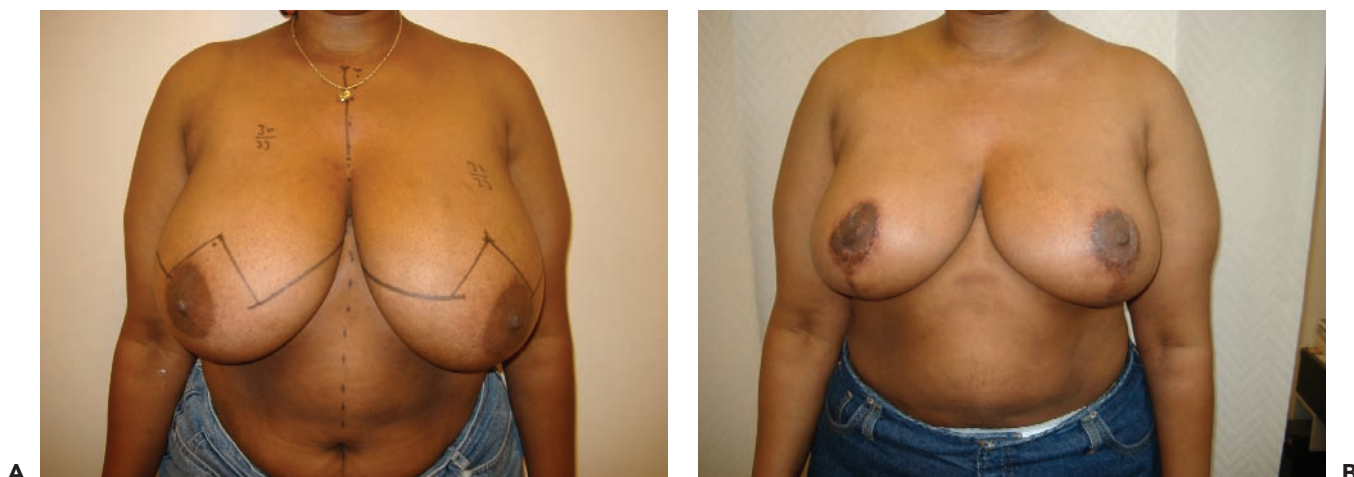
Occasionally the patient will report that she is still too large after reduction. A period of observation to allow edema to subside and for the patient to now attempt weight loss to get closer to a normal BMI (if she was overweight to start) should be undertaken.

An undesirable yet consistent long-term outcome of inferior pedicle and Wise-pattern breast reduction is “bottoming out” and developing a high NAC. A vertical skin excision may address the pseudoptosis sufficiently. Many techniques exist to lower the NAC, including excising excess skin in the IMF, but sometimes a scar above the NAC becomes necessary.

Fat necrosis should be treated conservatively initially since much of it will soften and improve. However, if after 6 to 9 months of massage and observation the fat necrosis is persistent, it should be excised through existing scars.

Nipple necrosis is managed conservatively until healed. Then, the nipple is reconstructed using the techniques for breast reconstruction (e.g., C-V flap, keyhole flap) and then tattooed. See Figure 94.5.

Malignancy is an uncommon finding in the breast specimen, but if found, it is discussed with the patient, pathologist, and a breast oncologic surgeon. If the malignancy is surrounded by a healthy margin of normal tissue, it can be considered an

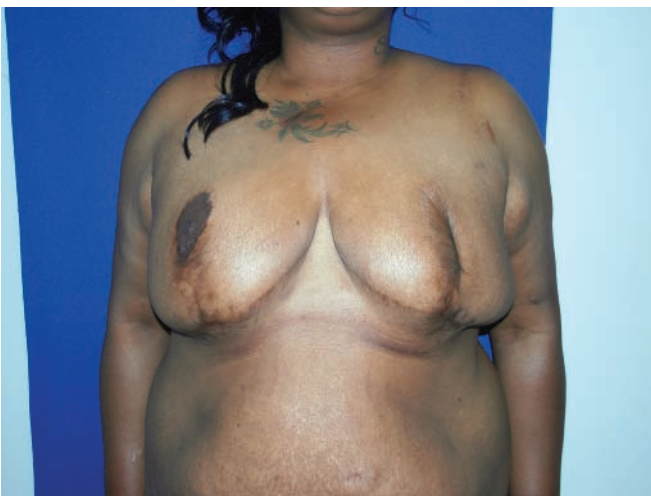

**Figure 94.4.** A: Long-term shape. Notice the fading of scars in this African American patient. B: Close-up view of incisions.

adequate lumpectomy. If not, then a mastectomy is indicated. Axillary lymph node sampling may be done via a sentinel lymph node technique. Radiation therapy would be indicated for this method of BCT.

## OUTCOMES

Numerous meta-analyses and prospective cohort studies provide level I and level II evidence that breast reduction is effective in addressing the symptoms associated with macromastia and that there is generally high patient and physician satisfaction (11). In breast reduction, the inferior pedicle technique takes center stage, as it is the most commonly subscribed to technique in the United States, has a low rate of complications, is versatile yet predictable, and preserves vascularity and sensation to the nipple (12).



**Figure 94.5.** Unilateral loss of nipple-areolar complex in a patient with fat necrosis throughout both breasts.

## EDITORIAL COMMENTS

The authors provide a very comprehensive guide for the management of the breast reduction patient. We must interpret this as their personal approach and not necessarily accept their comments as indicating anything approaching a standard of care. As I read this chapter prior to discussing it, I wished that they had spent more time describing the technique and less time on the more peripheral issues like insurance coverage, bra sizes, and so on. However, this chapter does provide an interesting overview regarding many aspects of managing the breast reduction patient.

There are many examples of where I might differ from the authors. For example, I do not measure the distance from the nipple to the IMF and prefer instead to measure how much the breast gland overhangs the fold, which is also much easier to measure than N-IMF. Similarly, I do not measure the size of the areola but refer to the preoperative pictures instead.

I find the discussion about bra sizes ambiguous. Although patients speak in terms of bra sizes, surgeons do not. We speak in terms of grams, and our concern is estimating as accurately as possible how much breast tissue we can safely remove. I often find that the bra sizes that patients report vary widely even for breasts of similar size. My experience is that for women with very large breasts who report DD, DDD, F, and G baseline bra cup sizes, the final postoperative bra size is often still a D or larger, but now it at least fits. The comment regarding nipple asymmetry corresponding to weight discrepancy in a ratio of 1 cm to 100 g is interesting but probably highly unreliable. My experience is often the opposite, with the more ptotic nipple sitting on the smaller more pendulous breast.

The authors' description of the informed-consent process is very personal and comprehensive. Mine is somewhat different, and I rely heavily on staff, printed materials, and commercially available information to round out the informed-consent process.



Regarding smoking, we strongly recommend that patients stop smoking for at least 2 weeks either side of surgery. We recognize that some patients cheat, and so we try to operate on previous smokers with more conservative technique than on nonsmokers.

The authors mention using obstetric calipers to transpose the IMF to the breast surface. I would like to think that using such calipers is pretty much a historical footnote.

All in all, this chapter is a thorough overview of the breast reduction experience particularly as it relates to reduction using the inferior pedicle.

S.L.S.

This chapter highlights the advantages associated with the use of an inferior pedicle in breast reduction. Several points are worthy of further emphasis. The authors rightly point out that the inverted-T skin pattern can be used with a number of different pedicles. However, using the inverted T with an inferior pedicle offers a strategic advantage due to the fact that the skin envelope and the pedicle with the attached NAC are managed separately. This allows the NAC to be lifted with no restriction, as opposed to a traditional vertical or superomedial technique, in which the pedicle base is part of the surrounding skin pattern and can therefore limit NAC transposition in cases of a short pedicle. The reader is also directed to the literature regarding the internal breast septum. This internal septum has profound influence on the vascularity of an inferior pedicle, and maintenance of the septal perforators is critical to the successful use of an inferior pedicle in cases of larger breast reductions with longer pedicles (13,14). Another aspect of the technique described in this chapter that is of particular importance is the practice of defining the final location of the NAC until the end of the case after the resection and skin tailoring have been performed. By sighting in the NAC position in this fashion as opposed to committing to the position of the NAC in the initial markings, inadvertent asymmetries or, perhaps more important, unwitting superior malpositions of the NAC can be prevented. As for complications, it stands to reason that the very tip of the inferior pedicle would be the area most at risk for ischemia, and it is in this location that fat necrosis is generally found in cases in which the length of the pedicle outstrips the ability of the vascular supply to nourish the tissues. Therefore, when firmness or an outright mass is noted just above the NAC

postoperatively, the etiology is nearly always fat necrosis at the tip of the pedicle. Observation over months will generally result in gradual resolution of the mass, leaving behind only a mild thickening. At one year postoperatively, if there is any persistence of a mass, it is advisable to remove the affected area to prevent any confusion with or masking of any underlying breast malignancy. As for bottoming out, if the attachments of Scarpa's fascia are left intact during the parenchymal resection along the inframammary fold, postoperative change in the shape of the breast will be greatly minimized, as the overlying breast parenchyma will be prevented from slipping inferiorly into the loose subscapular space. By combining these concepts with the principles outlined in the chapter, the inferior pedicle will continue to serve as the gold standard for breast reduction surgery, now and into the future.

D.C.H.

## REFERENCES

1. Kerrigan CL, Collins ED, Striplin DT, et al. The health burden of breast hypertrophy. *Plast Reconstr Surg* 2001;108:1591-1599.
2. Collins ED, Kerrigan CL, Striplin DT, et al. The effectiveness of surgical and nonsurgical interventions in relieving the symptoms of macromastia. *Plast Reconstr Surg* 2002;109:1556-1566.
3. Sigurdson LJ, Kirkland SA. Breast volume determination in breast hypertrophy: an accurate method using two anthropomorphic measurements. *Plast Reconstr Surg* 2006;118(2):313-320.
4. Krieger LM, Lesavoy MA. Managed care's methods for determining coverage of plastic surgery procedures: the example of reduction mammoplasty. *Plast Reconstr Surg* 2002;107:1234-1240.
5. Rohrich RJ, Gosman AA, Brown SA, et al. Current preferences for breast reduction techniques: a survey of board-certified plastic surgeons 2002. *Plast Reconstr Surg* 2004;114(7):1724-1733.
6. Matarasso A, Klatsky SA, Nahai F, et al. Secondary breast reduction. *Aesthet Surg J* 2006;26(4):447-455.
7. Khalifeh M, Redett R. The management of patients on anticoagulants prior to cutaneous surgery: case report of a thromboembolic complication, review of the literature, and evidence-based recommendations. *Plast Reconstr Surg* 2006;118(5):110e-117e.
8. Singh NK, Bluebond-Langner R, Nahabedian MY. Impact of anesthesia technique on breast reduction outcome: review of 200 patients with case-controls. *Aust N Z J Surg* 2003;73:A153-A330.
9. Wrye SW, Banducci DR, Mackay D, et al. Routine drainage is not required in reduction mammoplasty. *Plast Reconstr Surg* 2003;111(1):113-117.
10. Nahai FR, Nahai F. MOC-PSSM CME article: breast reduction. *Plast Reconstr Surg* 2008;121(1 suppl):1-13.
11. Chadbourne EB, et al. Clinical outcomes in reduction mammoplasty: a systematic review and meta-analysis of published studies. *Mayo Clin Proc* 2001;76:503-510.
12. Schreiber JE, Giroto JA, Mofid MM, et al. Comparison study of nipple-areolar sensation after reduction mammoplasty. *Aesthet Surg J* 2004;24(4):320-323.
13. Würinger E, Mader N, Posch E, et al. Nerve and vessel supplying ligamentous suspension of the mammary gland. *Plast Reconstr Surg* 1998;101(6):1486-1493.
14. Würinger E. Refinement of the central pedicle breast reduction by application of the ligamentous suspension. *Plast Reconstr Surg* 1999;103(5):1400-1410.



[AU1]Is "hours" OK?

