

# Alar Contour Grafts in Rhinoplasty: A Safe and Reproducible Way to Refine Alar Contour Aesthetics

Jacob G. Unger, M.D.  
Jason Roostaeian, M.D.  
Kevin H. Small, M.D.  
Ronnie A. Pezeshk, M.D.  
Michael R. Lee, M.D.  
Ryan Harris, B.A.  
Rod J. Rohrich, M.D.

Dallas, Texas



**Background:** Alar rim deformities such as retraction, notching, collapse, and asymmetry are common problems in rhinoplasty patients. Although alar rim deformities may be improved through rhinoplasty, this area is prone to late changes because of scarring of the soft triangles and a paucity of native structural support. The purpose of this study was to analyze the effect of alar contour grafts on primary rhinoplasty.

**Methods:** Fifty consecutive primary rhinoplasty patients with preoperative and postoperative photographs who received alar contour grafts were evaluated for alar aesthetics; 50 consecutive primary rhinoplasty patients without such grafts served as controls. Differences among alar retraction, notching, collapse, and asymmetry from anterior, lateral, and basal views were evaluated. Follow-up ranged from 1 to 4 years and was graded on a four-point scale.

**Results:** The average difference between the two groups' aggregate preoperative scores was 0.21 ( $p = 0.24$ ). The average preoperative and postoperative scores in the nongraft group were significant for worsening retraction, notching, and collapse but insignificant for asymmetry. The preoperative and postoperative scores for the graft group were insignificant for retraction but improved significantly for notching, collapse, and asymmetry. Postoperatively, the aggregate average of the scores in the nongroup was 0.32 points worse ( $p < 0.01$ ), whereas the graft group had a 0.33-point improvement ( $p < 0.01$ ).

**Conclusions:** Alar contour grafts have a clear and important impact on cosmetic results of primary rhinoplasty. Use of alar contour grafts has been shown to improve aesthetics, whereas there is a worsening of the measured parameters postoperatively without use of these grafts. (*Plast. Reconstr. Surg.* 137: 52, 2016.)

**CLINICAL QUESTION/LEVEL OF EVIDENCE:** Therapeutic, III.

Alar rim deformity is one of the more common problems that rhinoplasty patients can present with both preoperatively and postoperatively. Most notably, the issues that can affect this problematic area are retraction, notching, collapse, and asymmetry. Alar rim deformities are defined by the alar-columellar relationship, as discussed by Gunter<sup>1</sup> and further expanded upon by Guyuron.<sup>2</sup> The ideal alar rim on lateral view is defined as having a smooth contour with a slight arch, peaking vertically halfway between the tip-defining points and the columellar-lobular angle. In addition, the height of the alae should be no higher than 2 mm

above the long axis of the nostril. Also, the inferior border of the columella should be no lower than

**Disclosure:** The authors have no financial interest to declare in this research project or in any of the techniques or equipment used in this study. Dr. Rohrich receives instrument royalties from Eriem Surgical, Inc., and book royalties from CRC Press and Taylor and Francis Publishing. No funding was received for this article.

Supplemental digital content is available for this article. Direct URL citations appear in the text; simply type the URL address into any Web browser to access this content. Clickable links to the material are provided in the HTML text of this article on the Journal's website ([www.PRSJournal.com](http://www.PRSJournal.com)).

From the Department of Plastic Surgery, University of Texas Southwestern Medical Center.

Received for publication March 5, 2015; accepted June 23, 2015.

Copyright © 2015 by the American Society of Plastic Surgeons

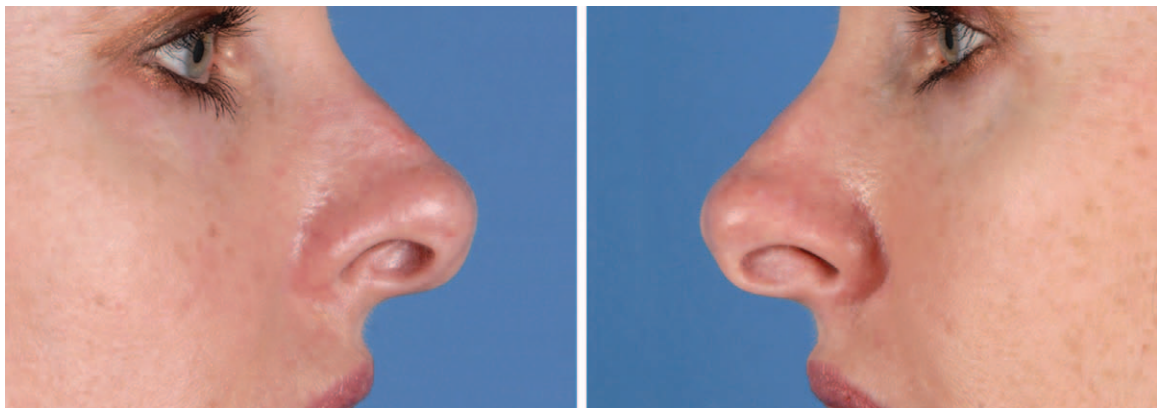DOI: 10.1097/PRS.0000000000001942

2 mm below the long axis of the nostril. Excessive elevation of the alar rim is considered alar retraction (Fig. 1), and a sharp angle within the ovular lateral contour is alar notching (Fig. 2), which can extend cephalically and is sometimes referred to as a parenthesis deformity or ball tip.<sup>3-5</sup> On basal view, the alae should maintain a straight or slightly convex shape from the tip to the alar base. The alae and tip configuration should resemble an equilateral triangle. As Sheen classically noted, the lateral crus of the lower lateral cartilage normally runs parallel to the alar rim.<sup>5</sup> This configuration is coupled with the attachments to the accessory cartilages in the pyriform aperture and their common perichondrium to create the lower lateral cartilage complex. The posterior half of the alar rim encompasses the alar lobule and is composed entirely of fibrofatty tissue and thick skin. When the lower lateral cartilage is congenitally cephalically oriented, there is a loss of support along the anterior portion of the alar rim, and a concavity can occur. This malformation of the rim on basal view is known as alar collapse and may be static, dynamic, or both (Fig. 3). This deformity can create both a functional collapse of the external valve and an unfavorable aesthetic appearance. Although much of the structure of the alar rim can be determined through the strength, shape, and position of the lower lateral cartilages, these cartilages do not allow for full control of an aesthetic alar rim, as evidenced by the common issues that still arise. Although issues such as asymmetry and alar-columellar relationship discrepancies can often be improved on the operating table with standard techniques such as tip suturing and columellar strut placement, this area is unfortunately prone to late changes resulting from scarring of the soft triangles and the paucity of structural support that exists in this region.

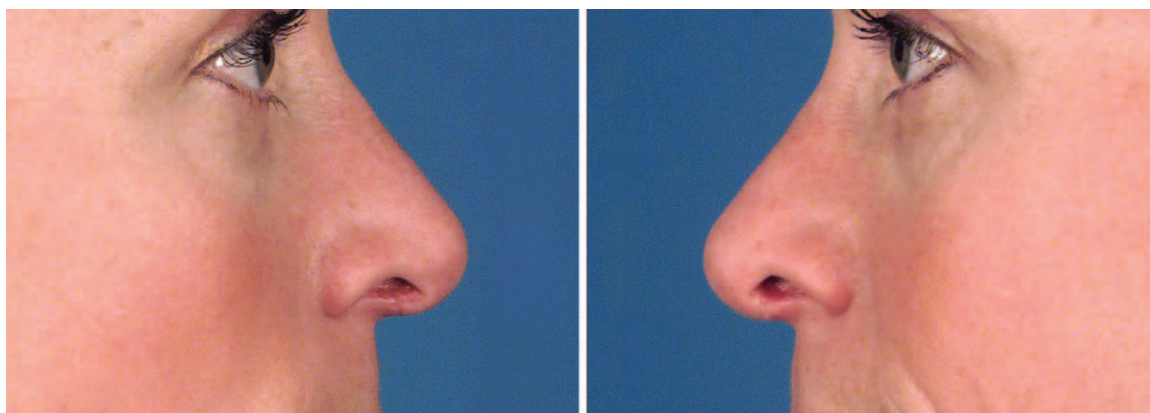
There have been many prophylactic interventions described for the plethora of aesthetic and functional challenges and abnormalities after primary rhinoplasty, specifically along the alar rim, including assorted suture techniques, advancement flaps, and grafts.<sup>2,6-9</sup> Previously, our group, and many others, have used alar contour grafts for various reasons in both primary and secondary rhinoplasty.<sup>10</sup> As these grafts have gained popularity, their indication for use has increased. The senior surgeon has now been using alar contour grafts routinely in all primary rhinoplasties because their effects on alar aesthetics have been impressive. Although it may be somewhat intuitive that alar rim or alar contour grafts serve a valuable purpose, it is our duty as physician-scientists to substantiate those claims with evidence-based medicine. The purpose of this study was to examine the degree to which alar aesthetics may be improved by using the placement of alar contour grafts in primary rhinoplasty.

## PATIENTS AND METHODS

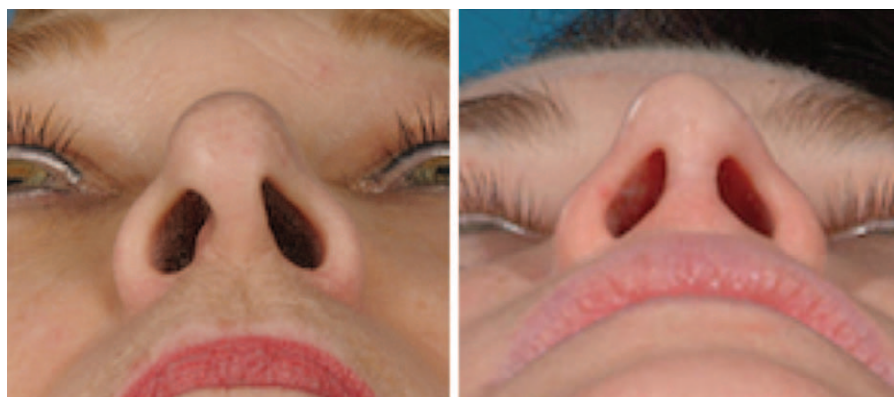A retrospective chart review was conducted on an institutional review board–approved database of patients who underwent rhinoplasty between 1996 and 2013 by a single surgeon. Fifty consecutive patients who were followed for at least 1 year were selected from the later subset (2006 through 2013), during which the surgeon performed alar contour grafts on all patients who underwent primary rhinoplasty. Fifty patients from prior to 2006 who did not receive alar contour grafts were then used as controls. Any patients who had received previous nasal surgery for trauma or tumor resection were excluded from the study. The retrospective chart review included patient demographics



**Fig. 1.** Patient example that demonstrates alar retraction. The smooth but elevated contour of the alar rim on the lateral view when compared with the long axis of the nostril is defined as alar retraction.



**Fig. 2.** Patient example that demonstrates alar notching. The acute angle along the alar rim from the lateral view between the soft triangle region and the alar lobule is defined as alar notching.



**Fig. 3.** Note the angle of the basal surface of the alar rim between the tip subunit and the alar base. This should ideally be straight, but the concavity noted in these examples is defined as alar collapse.

and postoperative complications. Three blinded plastic surgeons then evaluated primary rhinoplasty patients' results via standardized preoperative and postoperative photographs in sole regard to the alar aesthetics. The photographs were evaluated for differences between degrees of alar retraction, notching, collapse, and asymmetry from anterior, lateral, and basal views. All photographs ranged from 12 to 34 months of follow-up, with a mean follow-up of 15 months. All data categories were graded on a four-point scale: severe, 4; moderate, 3; minimal, 2; and none, 1. Differences between postoperative changes and scores were compared and statistically analyzed via paired *t* test.

### Technique

An open approach was used in all cases. A stair-step transcolumellar incision with bilateral infracartilaginous incisions was used to open the soft tissue envelope. The placement of the alar contour grafts is performed at the end of the

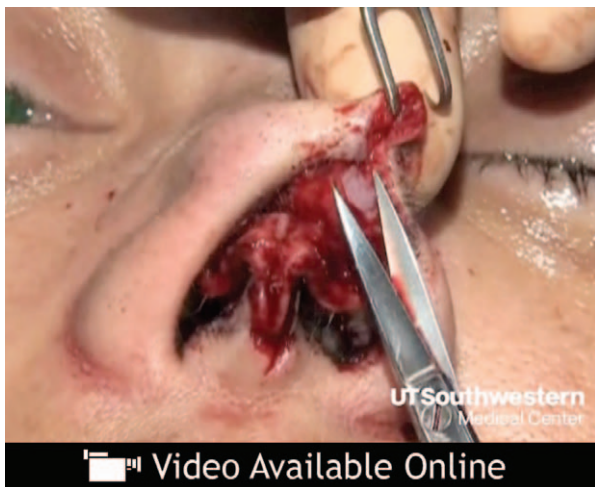procedure, immediately before closing, because these grafts are delicate and can become misplaced from their pocket or fractured during manipulation. Ideally, septal cartilage is used because it can be harvested within the primary surgical field, but an ear or rib cartilage graft may be used if septum is unavailable or inadequate in any way. It is important to note that although alar contour grafts are not large (measuring, on average, 2 to 3 mm wide and 1.5 cm long),<sup>11</sup> they must be of equivalent size, strength, and design. If the grafts are not nearly identical in both dimension and strength, these powerful grafts can cause tip deviation toward the weak side or asymmetric alar contour upon healing. The alar contour graft pocket is carefully dissected between the vestibular and nasal skin below the infracartilaginous incision by using long, sharp Stevens scissors. The pocket should be carried down into the alar lobule and ideally to the level of the alar base. This dissection will allow a secure pocket for graft placement. After the grafts are placed into their



pockets, the nasal skin is redraped for closure. Any excess cartilage that extrudes medially from the pocket is resected.<sup>10</sup> (See Video, Supplemental Digital Content 1, which demonstrates alar contour graft placement in a nonanatomic pocket along the alar rim extending from the infracartilagenous incision in a primary rhinoplasty and the subsequent improvement in basal alar aesthetics, available in the “Related Videos” section of the full-text article on PRSJJournal.com or, for Ovid users, at <http://links.lww.com/PRS/B514>.)

## RESULTS

The demographics were equivocal between the two groups, with no significant differences with regard to race, gender, smoking status, or age. The average difference between the aggregate preoperative scores of the two groups was 0.21, which was not significant ( $p = 0.24$ ). The average preoperative and postoperative scores in the non-alar contour graft group were significant for worsening retraction (1.99 and 2.30,  $p < 0.01$ ), notching (1.82 and 2.35,  $p < 0.01$ ), and collapse (1.94 and 2.36,  $p < 0.01$ ), but they were insignificant for asymmetry (2.35 and 2.38,  $p = 0.70$ ). The preoperative and postoperative scores for the alar contour graft group were insignificant for retraction (2.26 and 2.09,  $p = 0.08$ ), but they improved significantly for notching (2.08 and 1.6,  $p < 0.01$ ), collapse (2.22 and 1.89,  $p < 0.01$ ), and asymmetry (2.38 and 2.04,  $p < 0.01$ ).

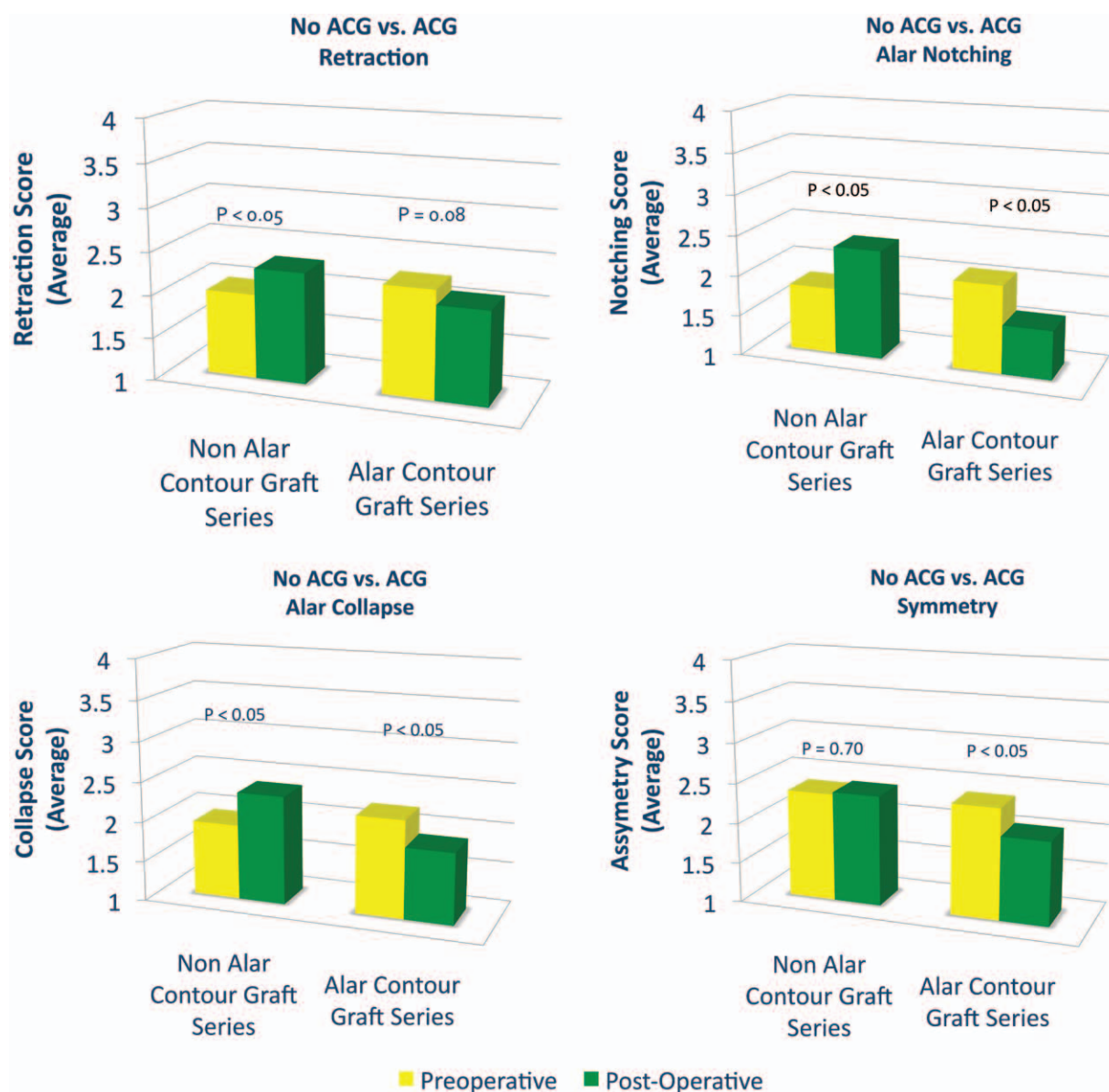


**Video.** Supplemental Digital Content 1, demonstrating alar contour graft placement in a nonanatomic pocket along the alar rim extending from the infracartilagenous incision in a primary rhinoplasty and the subsequent improvement in basal alar aesthetics, is available in the “Related Videos” section of the full-text article on PRSJJournal.com or, for Ovid users, at <http://links.lww.com/PRS/B514>.

The preoperative and postoperative images from each cohort were also analyzed within their respective groups (nongraft and graft). When evaluating the aggregated scores from all of the defined categories within each cohort, the overall aggregate difference was a 0.32-point worsening ( $p < 0.01$ ) in the nongraft group, whereas the graft group had a 0.33-point improvement ( $p < 0.01$ ) from the same analysis (Fig. 4). There were no major complications nor any revisions related to alar contour graft placement. Typical patient outcomes are demonstrated in Figures 5 through 8.

## DISCUSSION

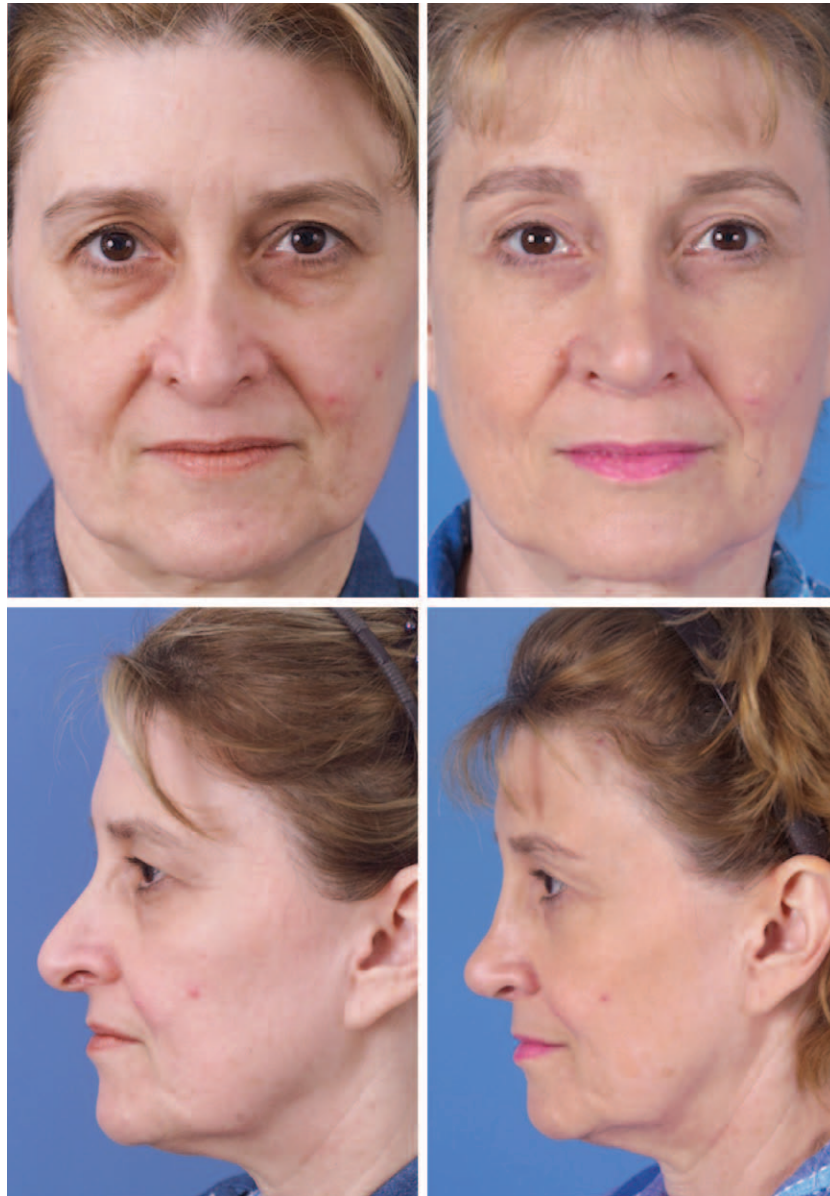Rhinoplasty is a constantly evolving field. This study demonstrates why our group's technique has evolved over time from occasional use of alar contour grafts in primary rhinoplasty to routine use. There are multiple modalities that have been described for correcting and defining alar abnormalities over the years.<sup>1–10,12–14</sup> Notably, Guyuron et al. recently published an article that detailed the dynamics and frequency of the use of the alar rim grafts. They found that a majority of patients who undergo rhinoplasty would benefit from alar rim grafts; the placement of an alar rim graft results in elongation of the short nostril, correction of the alar concavity, widening of the nostril, and slight caudal transposition of the alar rim. Guyuron suggested that this intervention could be a challenging and complex task, depending on the circumstances, with the average graft measuring approximately 15 to 16 mm long and 3 mm wide in this study. They concluded that it should be used in the majority of primary and secondary rhinoplasty patients to correct the existing retraction or prevent retraction in at-risk patients. Our technique follows similar surgical steps as outlined by Guyuron, reinforcing the application of his theoretical principles and suggested outcomes.<sup>15</sup> Gruber et al. also thoroughly reviewed the concept of alar rim grafting and lateral crural malposition. They hypothesized that if the lateral crus itself could be repositioned with less cephalic rotation and supported using an alar rim graft, many of the problems associated with abnormally configured lateral crura would be solved. It is important to note that although different terminology may be used amongst many of the leading figures in rhinoplasty, the concept is the same. To create an ideal and anatomically normal soft tissue construct to the alar rims, a combination of lateral crural repositioning and/or rim grafting can be powerful tools to improve alar dynamics and aesthetics.<sup>16</sup>



**Fig. 4.** Patients who did not receive an alar contour graft (ACG) versus patients who did. (Above, left) The preoperative and postoperative scores for the graft group were insignificant for retraction (2.26 and 2.09,  $p = 0.08$ ). (Above, right) The preoperative and postoperative scores for the graft group were improved significantly for notching (2.08 and 1.6,  $p < 0.01$ ). (Below, left) The preoperative and postoperative scores for the graft group were improved significantly for collapse (2.22 and 1.89,  $p < 0.01$ ). (Below, right) The preoperative and postoperative scores for the graft group were improved significantly for asymmetry (2.38 and 2.04,  $p < 0.01$ ).

Although many techniques have proved to be efficacious, they create unwieldy algorithms for treatment and oftentimes are such powerful maneuvers that they can generate their own unique set of problems, which then must be addressed after correcting the alar issues. Earlier in our group's application of alar contour grafts, they were only used in particular cases such as primary alar collapse with normal lining or in patients who underwent secondary rhinoplasty.<sup>10</sup>

As our experience progressed, we recognized that this technique was not limited to a patient who has a bulbous or boxy tip and congenital alar notching. In fact, the patient with weak lower lateral cartilages or cephalically rotated lower lateral cartilage would have a tendency to have postoperative notching or alar collapse because of the disruption of native support and the effects of scarring and healing on this weak soft tissue envelope. The use of alar contour was thus increased



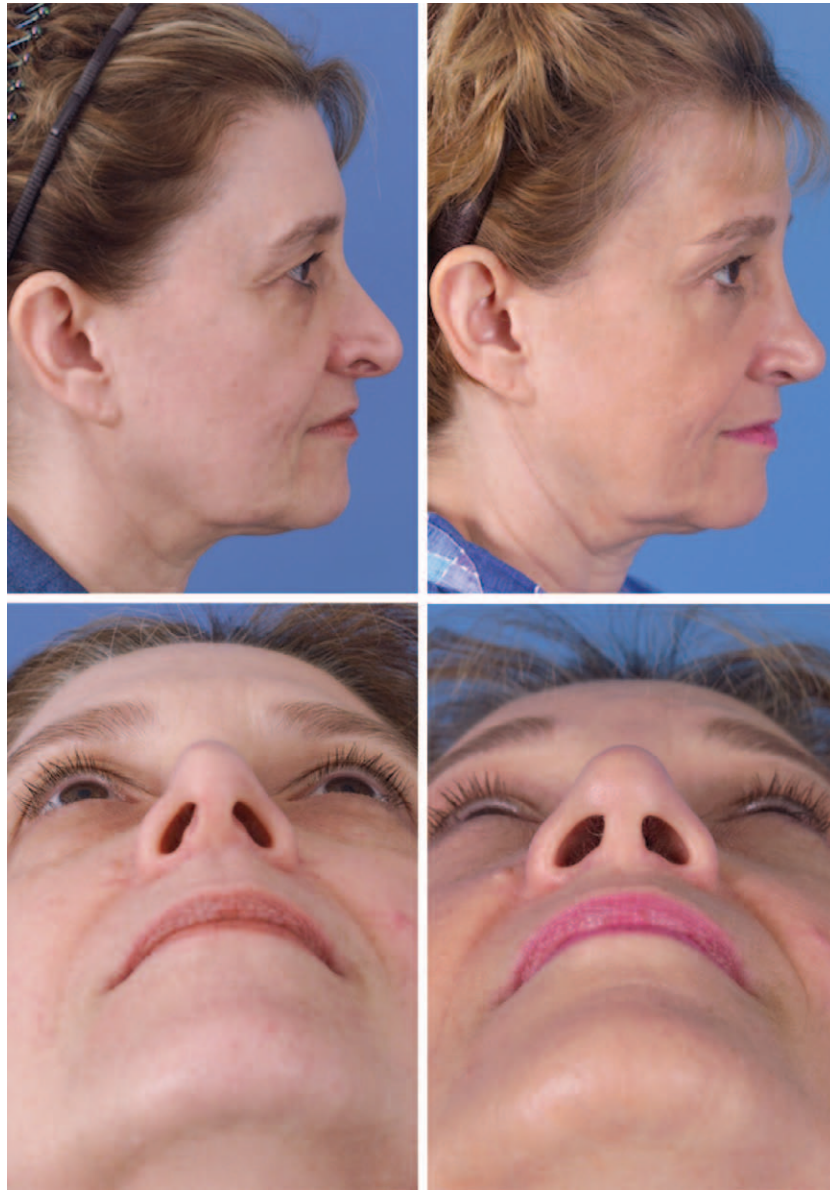**Fig. 5.** Patient example that demonstrates preoperative and postoperative photographs after an alar contour graft. Her aggregate preoperative scores were 2.33 for asymmetry, 2.67 for notching, 3 for retraction, and 1.67 for collapse. Her postoperative scores were 1.33 for asymmetry, 1 for notching, 1 for retraction, and 1.33 for collapse. This patient had no complications.

to include patients who appeared to have a weak or malpositioned lower vault. Although this application made an improvement in the consistency of results, there were still instances in which slight notching, collapse, or irregularities of the alar rim occurred in the postoperative period despite what appeared intraoperatively to be a structurally sound lower lateral cartilage complex and alar rim construct. Because one, despite experience, was unable to reliably predict postoperative alar anatomy and alar contour grafts had a very limited

complication profile, this technique became a standard part of our primary open rhinoplasty.

This study demonstrates that prophylactic use of alar contour improves alar aesthetics. Although the data indicate statistically significant improvement in most individual categories when comparing the two cohorts, it is important to note that there were statistically significant changes within each group as well. By using each group as its own control and comparing the preoperative and postoperative images within each cohort,



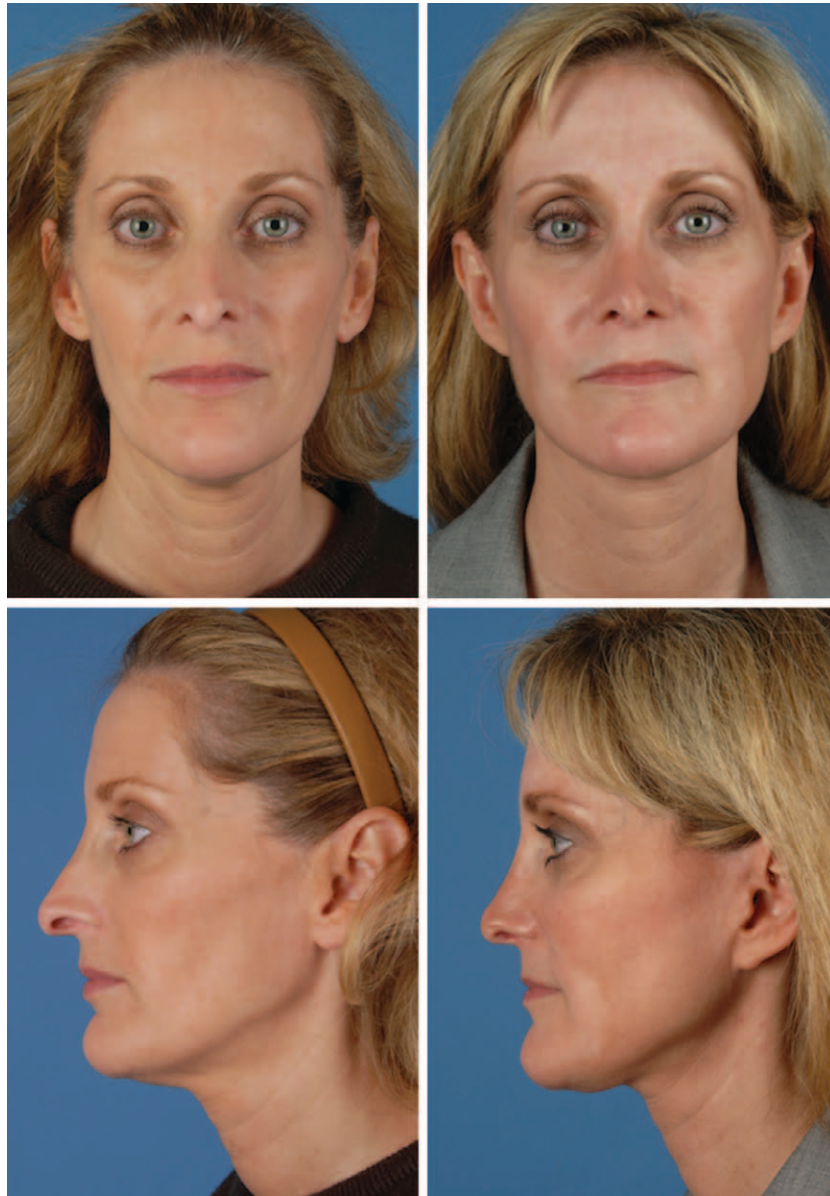

**Fig. 6.** Patient shown in Figure 5, additional views.

we have shown a clear aggregate improvement in alar aesthetics in the alar contour graft cohort and a definite worsening in the aesthetics in the non-alar contour graft cohort. In addition, in this series, we found no contraindications to using the graft in primary rhinoplasty. However, it should be noted that there may be instances in which the placement of an alar contour graft is not necessary, such as very strong and well-positioned lower lateral cartilages and excessively thick skin. These patient phenotypes may not require additional support because their inherent soft tissue strength and framework are adequate. We recognize that these situations are rare and this determination requires a high level of expertise. Thus,

the conservative course is to err on the side of placement of these beneficial, low-risk grafts.

Of note, alar contour grafts are especially helpful in our series because all of the rhinoplasties were performed in the open technique. For multiple reasons, this approach can result in alar retraction or notching with more frequency than the closed rhinoplasty. First, a scar is placed within the vestibular skin along the inferior border of the lower lateral cartilages; scarring, by nature, is unpredictable, and if a patient develops cicatricial tightening or increased scar burden, this fibrosis will cause an elevation of the alar rim, which results in retraction. In addition, alar retraction or notching may be accentuated by excessive suture



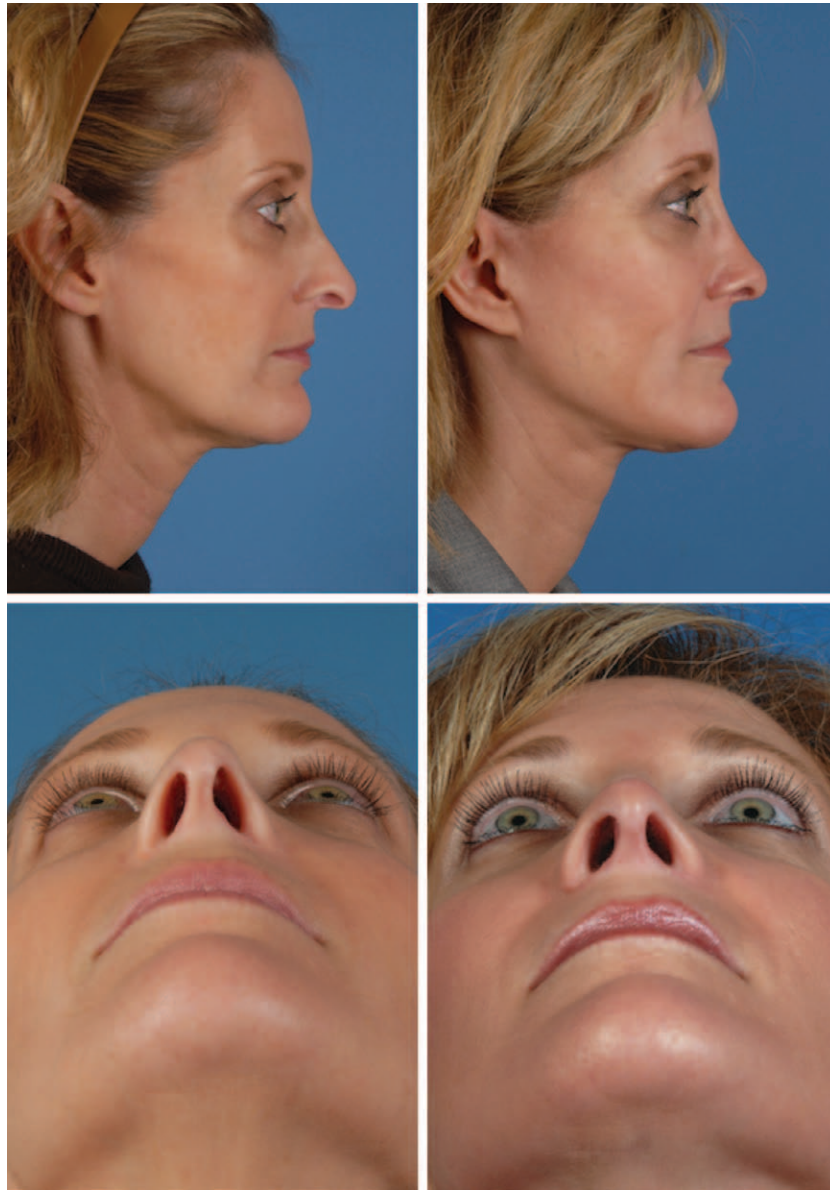**Fig. 7.** Patient example that demonstrates preoperative and postoperative photographs after an alar contour graft with significant aesthetic improvements. Aggregate preoperative scores were 3 for asymmetry, 2 for notching, 3 for retraction, and 1.67 for collapse. Her postoperative scores were 2.33 for asymmetry, 1.33 for notching, 1.33 for retraction, and 1 for collapse. This patient had no complications.

purchase of the vestibular skin when closing the infracartilagenous incisions. This suturing would cause a relative shortening of the vestibular skin in the vertical vector, which results in a notch or retracted ala. The alar contour graft acts as a buttress, in this case, to maintain the length of the vestibular skin during the scarring process while also providing a framework to set the length and shape of the nostril sill. Separately, dissecting any tip structures for needed modification inherently

weakens the tripod by dismantling the soft tissue framework (i.e., Pitanguy's ligament). Alar contour grafts reinforce the framework by using rigid materials to create a reliable scaffold for the soft tissue envelope after suture reconstruction of the domes.

Inherent limitations of this retrospective study include certain data points that were not available for analysis, and certain biases, such as selection bias, which were not accounted for.





**Fig. 8.** Patient shown in Figure 7, additional views.

Of note, alar contour grafts are now used routinely, regardless of perceived preoperative alar strength or shape, and thus, they do account for this selection bias to some degree. Furthermore, in addition to alar contour grafts, the native anatomy of the lower lateral cartilages has a direct impact on alar contour, symmetry, and aesthetics. Unfortunately, we did not record anatomical intraoperative observations of the native position of the lower lateral cartilages because this observation is not customary in our usual intraoperative routine. Thus, we cannot extrapolate this intraoperative data for our retrospective review. Although the nasal framework is an important component to

alar shape, which is not analyzed in this paper because of a lack intraoperative data, the independent effect on alar aesthetics of alar contour grafts was the primary focus of this study. Another limitation of this study is that the cohort who received alar contour grafts had surgery later in the career of the senior surgeon, thus there could be a learning bias that resulted in the improved results in this group. Finally, the reviewers' assessment was limited to a visual analog scale from two-dimensional photography. With the advent of three-dimensional photography and computerized data analysis, a more objective and quantifiable method to analyze symmetry may be possible.

This study is the first of its kind to try to determine the aesthetic benefit of including alar contour grafts in primary rhinoplasty by comparing the results with a control group by the same surgeon. As the results indicate, the use of this technique produces a superior aesthetic result with regard to the alar rim. There were no complications or complaints regarding the alar contour grafts in this series. However, it must be noted that although alar contour grafts have an excellent ability to prevent or improve postoperative notching, collapse, and retraction, they are often not strong enough or sufficient in cases with severe preoperative deformity, such as in secondary rhinoplasty or in cases in which there is a paucity of vestibular skin or soft tissue loss. Although we would recommend placing alar contour grafts in the majority of these cases as well, it may be necessary to further support the soft tissue with more powerful techniques such as lateral crural strut grafts.

## CONCLUSIONS

Alar contour grafts have had a clear and important impact in aesthetic results of primary rhinoplasties. These grafts have become an ideal method for controlling alar shape attributable to ease of placement, direct effect on the problem area, low complication profile, and minimal cartilage requirement. The use of alar contour grafts has been shown to improve aesthetics when used, whereas there has been a clear worsening of the measured parameters postoperatively without the aid of these grafts.

**Rod J. Rohrich, M.D.**

Department of Plastic Surgery  
University of Texas Southwestern Medical Center  
1801 Inwood Road  
Dallas, Texas 75390  
rod.rohrich@utsouthwestern.edu

## PATIENT CONSENT

*Patients provided written consent for the use of their images.*

## REFERENCES

1. Gunter JP, Rohrich RJ, Friedman RM. Classification and correction of alar-columellar discrepancies in rhinoplasty. *Plast Reconstr Surg*. 1996;97:643–648.
2. Guyuron B. Alar rim deformities. *Plast Reconstr Surg*. 2001;107:856–863.
3. Constantian MB. The boxy nasal tip, the ball tip, and alar cartilage malposition: Variations on a theme: A study in 200 consecutive primary and secondary rhinoplasty patients. *Plast Reconstr Surg*. 2005;116:268–281.
4. Toriumi DM. New concepts in nasal tip contouring. *Arch Facial Plast Surg*. 2006;8:156–185.
5. Sheen JH. *Aesthetic Rhinoplasty*. 1st ed. Mosby; 1978.
6. Hackney FL. Diagnosis and correction of alar rim deformities in rhinoplasty. *Clin Plast Surg*. 2010;37:223–229.
7. Juri J, Juri C, Grilli DA, Zeaiter MC, Belmont J. Correction of the secondary nasal tip. *Ann Plast Surg*. 1986;16:322–332.
8. Hamra ST. Repositioning the lateral alar crus. *Plast Reconstr Surg*. 1993;92:1244–1253.
9. Tardy ME Jr, Toriumi D. Alar retraction: Composite graft correction. *Facial Plast Surg*. 1989;6:101–107.
10. Rohrich RJ, Raniere J Jr, Ha RY. The alar contour graft: Correction and prevention of alar rim deformities in rhinoplasty. *Plast Reconstr Surg*. 2002;109:2495–505; discussion 2506.
11. Gunter JP et al. Importance of the alar-columellar relationship. In: Gunter JP, Rohrich RJ, Adams WP, eds. *Dallas Rhinoplasty: Nasal Surgery by the Masters*. 2nd ed. St. Louis, Mo.: Quality Medical Publishing; 2007:401–411.
12. Toriumi DM, Josen J, Weinberger M, Tardy ME Jr. Use of alar batten grafts for correction of nasal valve collapse. *Arch Otolaryngol Head Neck Surg*. 1997;123:802–808.
13. Gunter JP, Rohrich RJ. Correction of the pinched nasal tip with alar spreader grafts. *Plast Reconstr Surg*. 1992;90:821–829.
14. Gunter JP, Friedman RM. Lateral crural strut graft: Technique and clinical applications in rhinoplasty. *Plast Reconstr Surg*. 1997;99:943–952; discussion 953–955.
15. Guyuron B, Bigdeli Y, Sajjadian A. Dynamics of the alar rim graft. *Plast Reconstr Surg*. 2015;135:981–986.
16. Gruber RP, Fox P, Peled A, Belek KA. Grafting the alar rim: Application as anatomical graft. *Plast Reconstr Surg*. 2014;134:880e–887e.