

# The Inframammary Fold (IMF) Fixation Suture: Proactive Control of the IMF in Primary Breast Augmentation

Carey F. Campbell, MD; Kevin H. Small, MD;  
and William P. Adams Jr, MD

Aesthetic Surgery Journal  
2015, 1–5  
© 2015 The American Society for  
Aesthetic Plastic Surgery, Inc.  
Reprints and permission:  
journals.permissions@oup.com  
DOI: 10.1093/asj/sjv178  
www.aestheticsurgeryjournal.com  
**OXFORD**  
UNIVERSITY PRESS

Accepted for publication June 26, 2015.

Previous reports have suggested that inferior implant malposition following primary breast augmentation is secondary to violation of the inframammary fold (IMF) and subsequent poor reconstitution of the scaffold during the initial surgical procedure.<sup>1</sup> Additionally, inferior malposition may be related to occult weakness at the level of the IMF incision over time. Specifically, in an inframammary dual-plane/submuscular pocket, instability of the IMF can result in continued inferior descent of the breast implant due to the weight of the implant, the weight of the breast parenchyma, and the downward force of pectoralis animation.

Certain preoperative breast topography requires surgeons to alter the IMF to create optimal aesthetic results. In women with a short nipple-to-IMF distance or tuberous breast deformity, the IMF is intentionally lowered to expand the lower pole. However, inadequate subcutaneous release of the native IMF can result in a tight band across the inferior aspect of the implant. Additionally, failure to reconstitute a new IMF in these patients can also result in continued implant descent without banding.<sup>2</sup>

Although the etiology of implant malposition is multifactorial and patient dependent, the literature has focused on reactive, secondary techniques rather than proactive maneuvers in primary augmentation to prevent the deformity. These have included radial scoring, conversion to a subglandular plane or neo-submuscular pocket, creation of a dual plane, postoperative upper-pole compression and support of the neo-IMF, capsulorrhaphy, use of acellular dermal matrix, and deep fixation to the chest wall perichondrium.<sup>3</sup>

Prevention remains the most powerful solution, and preoperatively recognizing patients who are at high risk for

this complication allows for prevention of the deformity. Our practice has categorized the following as high-risk:

- (1) Surgical lowering of the IMF
- (2) Utilization of implants 20% larger than recommended by the high-5 process<sup>4</sup>
- (3) Nulliparous women with dense glandular breast tissue
- (4) Narrow breast width (BW < 11 cm)
- (5) Shaped form stable implants
- (6) Constricted lower pole or tuberous breasts

These groups are at increased risk for implant malposition because they have proportionally greater weight from the implant and/or breast tissue against the strength of the IMF.<sup>5</sup> Secondary to gravity, dynamic activities, and location of implants behind the breast parenchyma or pectoralis, these implants exert a constant stress on the inferior pole of the breast.<sup>6</sup> Furthermore, surgical repositioning of the fold places the patient at increased risk for a persistent native

From the Department of Plastic Surgery, University of Texas Southwestern Medical Center, Dallas, TX.

#### Corresponding Author:

Dr William P. Adams, Jr, Department of Plastic Surgery, University of Texas Southwestern Medical Center, 6901 Snider Plaza, Suite 120, University Park, TX 75205, USA.  
E-mail: dr@dr-adams.com

Presented at: the Residents and Fellows Forum and the General Assembly, the American Society for Aesthetic Plastic Surgery's annual meeting in Montreal, Québec, Canada in May 2015.

IMF with inferior implant malposition or inferior descent of the implant due to weakened IMF support.

As such, 3-point suture fixation, a technique commonly seen in breast reconstruction or secondary breast revisions,<sup>7-9</sup> has been used preemptively in our practice in these high-risk primary-breast-augmentation patients. This tutorial describes the senior author's experience with this approach to reinforce the IMF, minimize implant malposition, and maximize outcomes.

## ANATOMY

First described by Sir Astley Cooper in 1845,<sup>10</sup> the precise anatomy of the IMF remains controversial in the literature. Multiple authors cite that a discrete inframammary crease ligament is found originating from the fifth rib medially to the sixth interspace laterally and inserts into the deep dermis at the level of the IMF.<sup>11-13</sup>

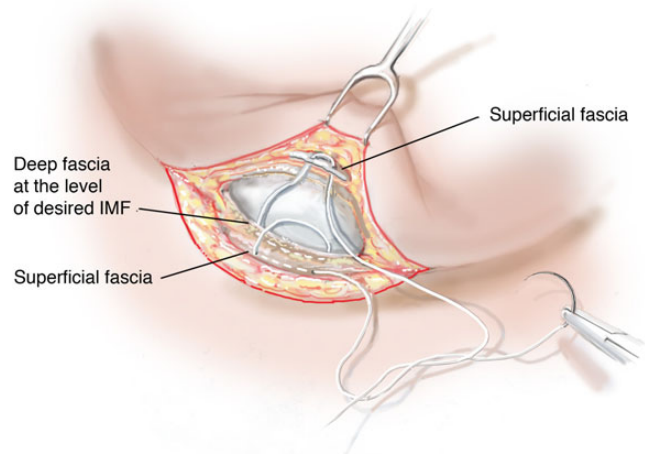
Recent anatomic dissections of the breast have identified dermal attachments to the deep and superficial fascia that constitute the foundation of the IMF rather than the presence of a distinct inframammary crease ligament. These dissections have shown that the superficial fascia splits into a subcutaneous layer anterior to the gland (Camper's fascia) and a superficial fascia layer deep to the gland (Scarpa's fascia). Below this Scarpa's layer, a layer of deep fascia lies on the anterior surface of the pectoralis major and serratus anterior muscle. Collagen fibers from the superficial and deep layers of the superficial fascia traverse the gland to insert into the dermis at the level of the IMF.<sup>14,15</sup>

Even though the anatomy of the IMF may be disputed and these ligamentous structures or fascial confluences may not be fully appreciated clinically, the IMF should still be reinforced for these high-risk patients because of their potential for inferior implant malposition. A 3-point suture would ideally mimic dermal attachments between the superficial Camper's fascia, Scarpa's fascia, and deep fascia on the anterior surface of the pectoralis.

## OPERATIVE DETAILS

For the purposes of this study, 3-point suture fixation was only applied to primary subpectoral breast-augmentation patients with an inframammary approach. Implants, as well as the IMF, were selected based on tissue-based measurements.<sup>4</sup>

After pocket dissection and implant placement,<sup>16</sup> a 3-point fixation suture (3-0 vicryl) was placed at the midpoint of the incision between the superficial fascia along the lower aspect of the IMF incision, the superficial fascia along the upper aspect of the IMF incision, and the deep fascia at the IMF (Figure 1).<sup>17</sup> This fixation was repeated 1 cm lateral and medial to the midpoint, closing the breast pocket. The implant was protected during all points of fixation. The 3-point suture fixation created dermal fascial attachments to



**Figure 1.** This illustration depicts 3-point suture placement between the superficial fascia of the breast envelope, the superficial fascia at the IMF, and the deep fascia at the IMF.

the underlying deeper fascia, reinforcing the IMF. Of note, appropriately placed 3-point suture fixation will transmit a mild external indentation to the soft tissue that will dissipate over the subsequent 2 weeks. The remainder of the incision was closed in layers. A video demonstrating the IMF fixation suture at the IMF of the breast in a primary breast augmentation is available as Supplemental Material.

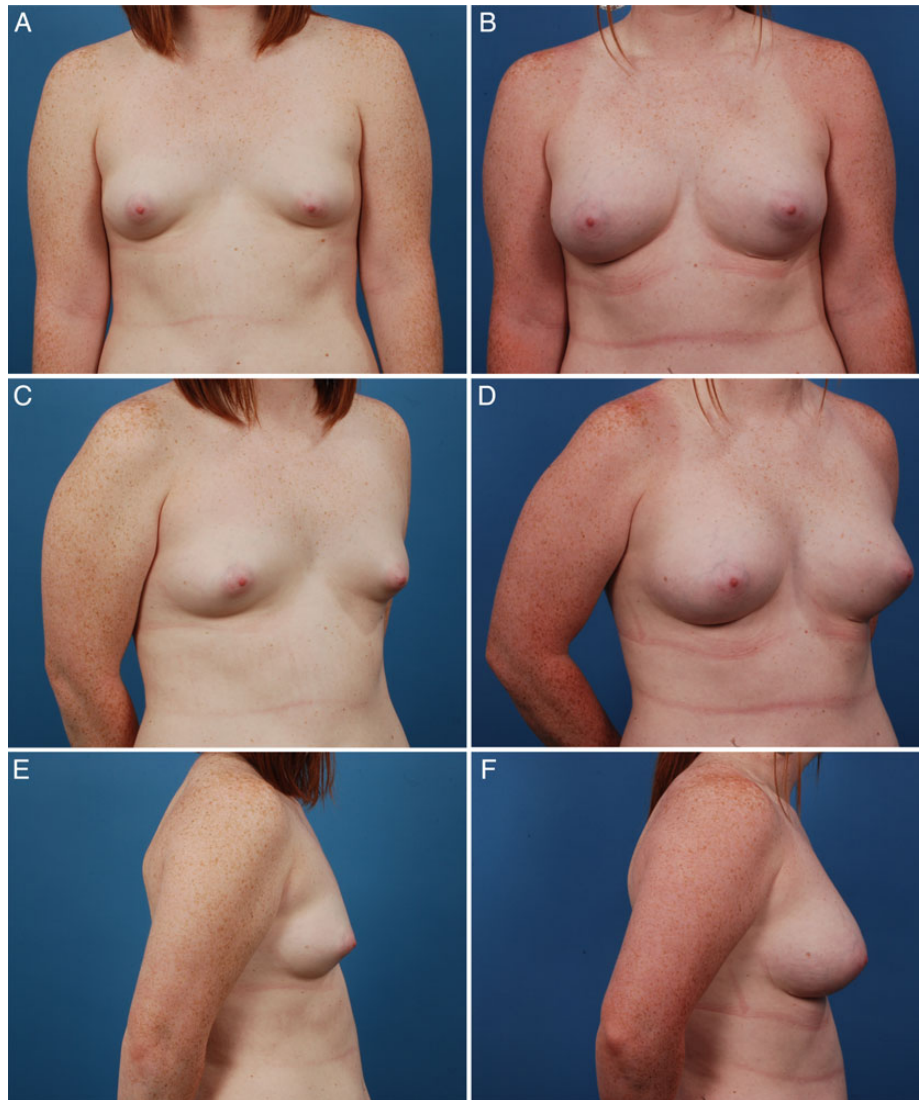## MY EXPERIENCE

We have applied this technique from 2010 through 2014 to approximately 600 high-risk primary-breast-augmentation patients in our practice. All of these patients had at least 1 of the 6 aforementioned preoperative criteria; these patients had increased stress on the IMF and/or iatrogenic weakness of the IMF. No postoperative complications were reported, and implant malposition was less than 1% in this series. All high-risk patients seemed to benefit equally from placement of a 3-point suture. Future investigations are needed to determine which patient subtypes have the highest benefit from IMF fixation or if the presence of multiple criteria have a compounded risk of implant malposition.

Since implementing this protocol, no high-risk patients in the clinical practice have been excluded from this surgical algorithm. All patients have been seen approximately 1 week, 1 month, 3 months, 6 months, and 1 year postoperatively. Representative clinical cases are depicted in Figure 2 (constricted pole) and Figure 3 (narrow breast).

## OUTCOMES

This article describes a single surgeon's experience with 3-point suture fixation as a preventive adjunct for implant malposition in primary breast augmentation. This technique



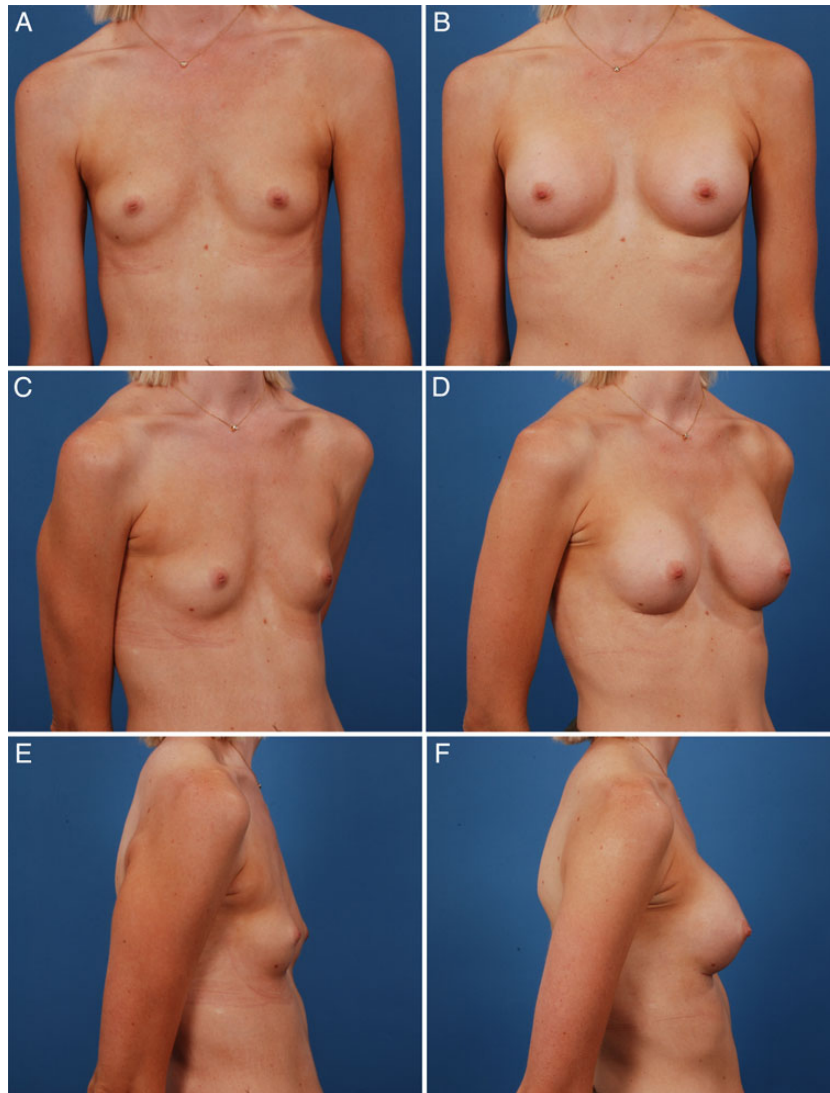
**Figure 2.** Preoperative (A, C, E) and 1-year postoperative (B, D, F) photographs of this 20-year-old woman with a constricted lower pole. Her right breast measurements were sternal notch-to-nipple, 20.5 cm; nipple-to-IMF, 8 cm; and breast base width, 12 cm. Her left breast measurements were sternal notch-to-nipple, 21 cm; nipple-to-IMF, 6 cm; and breast base width, 12 cm. She received a bilateral breast augmentation with 295cc Mentor (Santa Barbara, CA) contour profile gel style 322 silicone implants and 3-point suture technique.

did not increase operative time, implant trauma, operative bleeding, or postoperative recovery. Postoperatively, patients did not complain of increased pain or IMF distortion. Long-term studies are needed; but anecdotally, implant malposition has been less than 1% with this surgical adjunct in this high-risk population. Prior to 2010, the incidence of implant malposition was 3% in this cohort.

Even though we have not seen any complications from this procedure in our series, this intervention is not 100% atraumatic. Three-point suture fixation places increased suture material in the incision, possibly leading to a foreign body reaction. Additionally, the suture causes a temporary

fold deformity; however, this deformity subsides after a few weeks. Furthermore, placement of a deep-fascial suture potentially increases the risk of hematoma or implant injury. As a result of these possible adverse outcomes, we reserve the 3-point suture for high-risk patients.

This article focuses on technical refinements rather than a comparative series; as such, the specifics of patient demographics and/or clinical outcomes were not extrapolated. A longer, larger investigation with detailed patient characteristics is needed to compare our series vs controls. Despite these limitations, because this technical refinement is easily adaptable, sustainable, has minimal risk,



**Figure 3.** Preoperative (A, C, E) and 1-year postoperative (B, D, F) photographs of this 26-year-old woman with a narrow breast. Her right breast measurements were sternal notch-to-nipple, 18.5 cm; nipple-to-IMF, 6.5 cm; and breast base width, 10.5 cm. Her left breast measurements were sternal notch-to-nipple, 19 cm; nipple-to-IMF, 6.5 cm; and breast base width, 10.5 cm. She received a bilateral breast augmentation with 234 cc Allergan (Parsippany, NJ) style 15 silicone implants, repositioning of the fold down to 7.2 cm, and 3-point suture technique.

and does not increase operative time, reporting the surgical steps and indications of this technique is valuable to plastic surgeons.

### **COST**

No increased financial cost was associated with use of this technique.

### **CONCLUSIONS**

By preemptively treating breast augmentation patients who are at high risk for IMF deformities, this IMF fixation suture

can control the IMF and implant position. This technical refinement for breast augmentation may help refine results and minimize future complications; however, future studies are needed for definitive conclusions.

### **Supplementary Material**

This article contains supplementary material located online at [www.aestheticsurgeryjournal.com](http://www.aestheticsurgeryjournal.com).

### **Disclosures**

The authors declared no potential conflicts of interest with respect to the research, authorship, and publication of this article.



## Funding

The authors received no financial support for the research, authorship, and publication of this article.

## REFERENCES

1. Spear SL, Pittman T. Discussion: the double-bubble deformity: cause, prevention, and treatment. *Plast Reconstr Surg*. 2013;132(6):1444-1445.
2. Fisher J, Handel N, Hall-Findlay EJ. Double bubble deformity. In: Fisher J, Handel N, eds. *Problems in Breast Surgery: A Repair Manual*. Boca Raton, FL: CRC Press; 2014: 227-252.
3. Handel N. The double-bubble deformity: cause, prevention, and treatment. *Plast Reconstr Surg*. 2013;132(6): 1434-1443.
4. Tebbetts JB, Adams WP. Five critical decisions in breast augmentation using five measurements in 5 minutes: the high five decision support process. *Plast Reconstr Surg*. 2005;116(7):2005-2016.
5. Médard de Chardon V, Balaguer T, Chignon-Sicard B, Lebreton E. Double breast contour in primary aesthetic breast augmentation: incidence, prevention and treatment. *Ann Plast Surg*. 2010;64(4):390-396.
6. Vegas MR, Martin del Yerro JL. Stiffness, compliance, resilience, and creep deformation: understanding implant-soft tissue dynamics in the augmented breast: fundamentals based on materials science. *Aesthetic Plast Surg*. 2013;37(5):922-930.
7. Spear SL, Little JW III. Breast capsulorrhaphy. *Plast Reconstr Surg*. 1988;81(2):274-279.
8. Chasan PE. Breast capsulorrhaphy revisited: a simple technique for complex problems. *Plast Reconstr Surg*. 2005;115(1):296-301.
9. Bogetti P, Cravero L, Spagnoli G, et al. Aesthetic role of the surgically rebuilt inframammary fold for implant-based breast reconstruction after mastectomy. *J Plast Reconstr Aesthet Surg*. 2007;60(11):1225-1232.
10. Cooper AP. *On the Anatomy of the Breast*. London: Longmans; 1845.
11. Bayati S, Seckel BR. Inframammary crease ligament. *Plast Reconstr Surg*. 1995;95(3):501-508.
12. Maillard GF, Garey LJ. An improved technique for immediate retropectoral reconstruction after subcutaneous mastectomy. *Plast Reconstr Surg*. 1987;80(3): 396-408.
13. van Straalen WR, Hage JJ, Bloemena E. The inframammary ligament: myth or reality? *Ann Plast Surg*. 1995;35(3):237-241.
14. Muntan CD, Sundine MJ, Rink RD, Acland RD. Inframammary fold: a histologic reappraisal. *Plast Reconstr Surg*. 2000;105(2):549-556.
15. Matousek SA, Corlett RJ, Ashton MW. Understanding the fascial supporting network of the breast: key ligamentous structures in breast augmentation and a proposed system of nomenclature. *Plast Reconstr Surg*. 2014;133(2):273-281.
16. Adams WP Jr. The process of breast augmentation: four sequential steps for optimizing outcomes for patients. *Plast Reconstr Surg*. 2008;122(6):1892-1900.
17. Adams William P. *Breast Augmentation*. McGraw-Hill *Plastic Surgery Atlas*. New York: McGraw-Hill Medical; 2011.