

# Face Lift

Dinah Wan, M.D.  
Kevin H. Small, M.D.  
Fritz E. Barton, M.D.

Dallas, Texas

**Learning Objectives:** After studying this article, the participant should be able to: 1. Identify the essential anatomy of the aging face and its relationship to face-lift surgery. 2. Understand the common operative approaches to the aging face and a historical perspective. 3. Understand and describe the common complications following face lifting and treatment options.

**Summary:** Surgical rejuvenation of the aging face remains one of the most commonly performed plastic surgery procedures. This article reviews the anatomy of the face and its impact on surgical correction. In addition, this review discusses the evolution of various face-lift techniques and the current surgical approach to the aging face. Finally, this article discusses potential postoperative complications after rhytidectomy and management solutions. (*Plast. Reconstr. Surg.* 136: 676e, 2015.)

## ANATOMY

### Skin, Bone, and Soft Tissue

Facial aging is a multifactorial process involving the skin, facial skeleton, and soft tissue. Epidermal thinning, collagen loss, and dermal elastosis contribute to the fine rhytides of the skin.<sup>1</sup> Remodeling of the facial skeleton creates the morphologic basis of aging.<sup>2,3</sup> Posterior retrusion of the bony maxilla with age leads to a blunted midface and loss of support for the periorbital tissues.<sup>2,3</sup> Inherently prominent globes and a hypoplastic maxilla also contribute to a “negative vector” relationship, where the globe projects anterior to the malar eminence, creating an environment for lower lid laxity, sagging cheeks, and a prominent tear trough.<sup>4-6</sup>

Although the facial skeleton certainly generates the morphologic basis of aging, bony manipulation or augmentation is limited in facial rejuvenation surgery. Rather, it is the soft-tissue envelope that is primarily addressed in face lifts.<sup>7</sup> Soft-tissue ptosis, whether as a result of ligamentous attenuation, volume deflation, or bony retrusion, leads to the deep creases of the aging face and represents the target of surgical correction.

### Retaining Ligaments

In 1989, Furnas described ligaments anchoring the soft tissues of the cheek to underlying

fibro-osseous structures.<sup>8</sup> These were further characterized by Stuzin et al. in 1992.<sup>9</sup> The zygomatic ligaments anchor the malar cheek skin to the periosteum of the zygomatic eminence. The zygomatic ligaments exist as a series of fibrous septa permeating the malar pad and are collectively known as the McGregor patch.<sup>8-10</sup> The mandibular ligaments arise from the parasymphyseal and symphyseal regions of the mandible and insert into the overlying skin of the chin. The mandibular septum is an osteocutaneous zone of adherence that spans the middle third of the mandibular body and is the posterolateral continuation of the mandibular ligament. The mandibular septum inserts 1 cm superior to the mandibular border and separates the cheek/jowl fat from the neck/submandibular fat.<sup>11</sup> The masseteric cutaneous and parotid cutaneous ligaments (or Lore fascia) arise from the anterior border of the masseter and the parotid gland, respectively, to insert into dermis (Fig. 1).<sup>9</sup> Laxity of these ligaments contributes to vertical descent of facial tissue, leading to the sagging appearance and deep creases of the aging face.<sup>9</sup> Repeated animation of facial mimetic muscles such as in smiling also contributes to this ligamentous attenuation.<sup>9,12,13</sup>

### Mimetic Muscles

The mimetic muscles control facial expression and are situated in two layers. The superficial

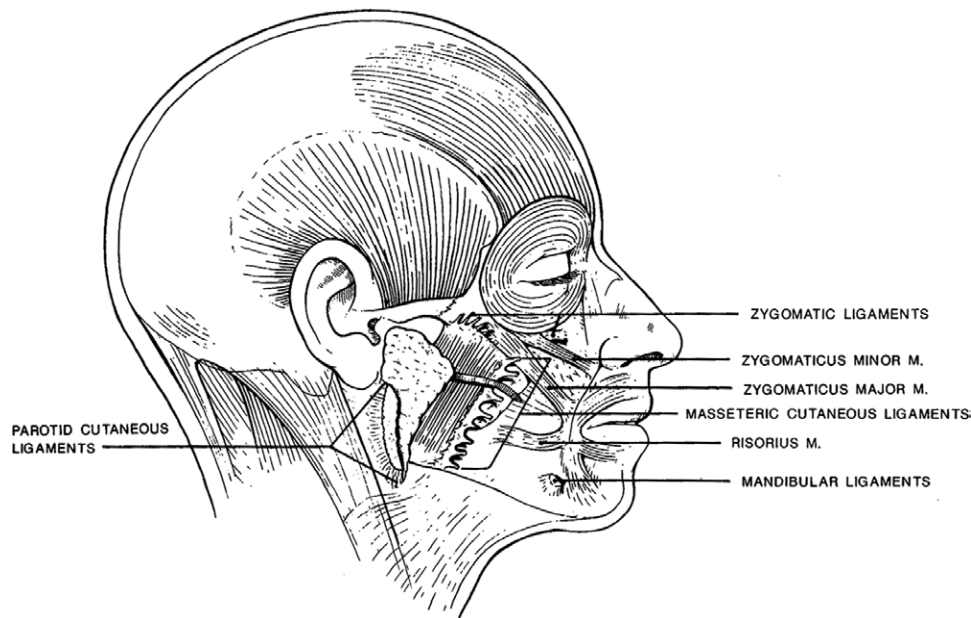
*From the Department of Plastic Surgery, University of Texas Southwestern Medical Center.*

*Received for publication February 28, 2015; accepted April 8, 2015.*

*Copyright © 2015 by the American Society of Plastic Surgeons*

DOI: 10.1097/PRS.0000000000001695

**Disclosure:** There are no funding sources for this work. The authors have no financial interest with any product mentioned in the article.



**Fig. 1.** The retaining ligaments anchor the soft tissues of the face. The zygomatic and mandibular ligaments are osteocutaneous ligaments that originate from periosteum and insert directly into the dermis. The masseteric cutaneous and parotid cutaneous ligaments originate from fixed underlying structures such as the anterior border of the masseter muscle and the parotid gland, respectively, and insert into dermis. [Reprinted with permission from Stuzin J. Face lifting. *Plast Reconstr Surg.* 2008;121(Suppl):1–19.]

layer consists of the zygomaticus major and minor, the levator labii superioris, risorius, the depressor anguli oris, and the orbicularis oculi and oris. The deep layer includes the levator anguli oris, buccinator, depressor labii inferioris, and mentalis.<sup>7,14</sup> The modiolus is the fibrous junction just lateral to the angle of the mouth where the zygomaticus major, levator and depressor anguli oris, risorius, and buccinator muscles converge. All mimetic muscles are innervated by the facial nerve from their deep surface except for the buccinator, mentalis, and levator anguli oris, which are innervated from the superficial surface.<sup>15</sup>

### Superficial Musculoaponeurotic System

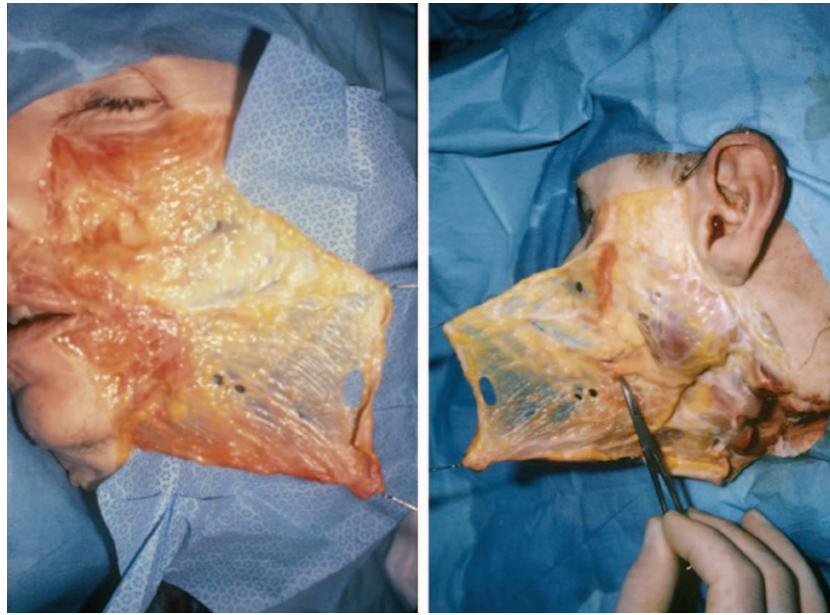
Probably the earliest description of the superficial musculoaponeurotic system (SMAS) was in Sir Charles Bell's 1799 publication *A System of Dissections*, in which he called this fascial layer the "cellular membrane."<sup>16,17</sup> Gray followed in 1859 with his description of the "superficial subcutaneous fascia" of the face.<sup>18</sup> Mitz and Peyronie's classic anatomical study of 1976 referred to this layer as the "superficial musculo-aponeurotic system," and with this study, the term SMAS was coined.<sup>19</sup> The SMAS has since become a prevalent entity in the description of face-lift procedures. The SMAS was originally described as the superficial fascia

of the face that invests the superficial layer of mimetic muscles and divides the subcutaneous fat into two layers.<sup>19</sup> It is in continuity with the temporoparietal fascia, frontalis muscle, and galea superiorly, and the platysma and superficial cervical fascia inferiorly.<sup>20</sup> The SMAS becomes attenuated medially (Fig. 2, left).<sup>21,22</sup> Branches from the anterior facial artery course on the undersurface of the SMAS (Fig. 2, right).<sup>14</sup>

The deep temporal fascia in the temporal region, the parotidomasseteric fascia in the cheek, and the deep cervical fascia in the neck represent the deep fascial layers under which the branches of the facial nerve course. As such, when performing a sub-SMAS dissection, care is taken to not violate the underlying deep facial fascia to avoid injury to the facial nerve.<sup>9</sup>

### Neurovascular Structures

The facial nerve (seventh cranial nerve) emerges from the stylomastoid foramen and enters the substance of the parotid gland where the main trunk branches. The buccal and zygomatic branches are well collateralized within the cheek, which buffers them from clinically consequential injuries.<sup>23</sup> By contrast, the frontal branch and marginal mandibular branch are more often terminal, rendering them less forgiving of injury.<sup>24</sup>



**Fig. 2.** Cadaver dissection of the SMAS, with its anterior distribution investing the superficial mimetic muscles (*left*). Branches from the anterior facial artery can be seen on the undersurface of the SMAS (*right*). (Reprinted with permission from Barton FE Jr. *Facial Rejuvenation*. Boca Raton, Fla: Quality Medical Publishing/CRC Press; 2008.)

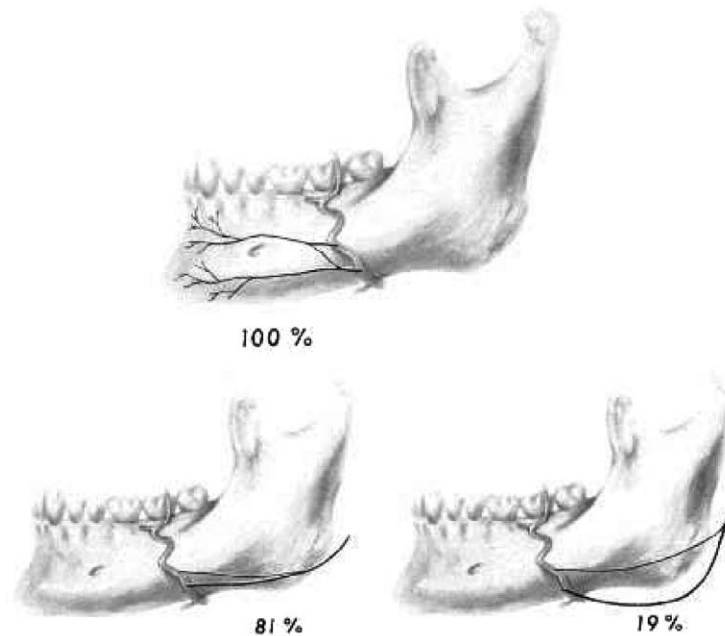
The frontal, or temporal, branch of the facial nerve courses along the Pitanguy line, which ascends from 0.5 cm below the tragus to 1.5 cm above the lateral brow.<sup>25</sup> It can be found within 10 mm cephalad to the sentinel vein, which is a perforating vessel that pierces the temporoparietal fascia 5 mm lateral to the frontozygomatic suture.<sup>26–28</sup> The frontal branch is vulnerable to injury as it crosses the zygomatic arch 2.5 cm anterior to the external auditory meatus<sup>29</sup> in a plane deep to the temporoparietal fascia. A distinct fascial layer deep to the temporoparietal fascia, the parotid-temporal fascia, has been shown to exist at this level, providing a second layer of protection for the frontal branch at the zygomatic arch.<sup>30</sup>

The marginal mandibular branch of the facial nerve courses along the inferior mandibular border in a plane deep to the platysma, within the superficial layer of the deep cervical fascia. An anatomical study of 100 cadaveric facial halves found that, posterior to the facial artery, the mandibular branch courses above the inferior mandibular border in 81 percent of specimens; in the other 19 percent, the nerve dips down, with its lowest point within 1 cm below mandibular border (Fig. 3, *below, right*),<sup>31</sup> but it can be found as low as 4 cm below the mandible.<sup>24,32</sup> Anterior to the facial artery, the

nerve courses above the inferior border of the mandible (Fig. 3, *above*).

The facial artery arises from the external carotid artery and rounds the lower border of the mandible as it exits the neck, approximately 3 cm from the mandibular angle.<sup>33,34</sup> The facial vein lies immediately posterior to the artery at this level. Both vessels are crossed over by the facial nerve. Superiorly, the facial artery continues its course over the anterior surface of the masseter.<sup>34</sup>

The great auricular nerve (C2–C3) provides the dominant sensory supply to the ear, specifically, the lobule, concha, and posterior auricle.<sup>14,35</sup> The lesser occipital nerve contributes mainly to the sensory innervation of the upper ear.<sup>36</sup> The great auricular nerve is the most commonly injured nerve in face-lift surgery.<sup>37</sup> Complete severance of this nerve causes numbness of the ear, and partial severance can create painful neuromas.<sup>14</sup> The nerve is technically protected by the superficial cervical fascia but is prone to injury as it exits the posterior border of the sternocleidomastoid muscle where the platysma is absent. It crosses the midbelly of the sternocleidomastoid muscle at the McKinney point 6.5 cm inferior to the external auditory canal.<sup>35,37,38</sup> The external jugular vein courses parallel and 0.5 cm anterior to the great auricular nerve, and the lesser occipital nerve courses posteriorly (Fig. 4).



**Fig. 3.** Illustration of anatomical variations of the mandibular branch of the facial nerve in a cadaveric study of 100 facial halves. Posterior to the facial artery, the mandibular ramus passed above the inferior mandibular border in 81 percent of specimens (*below, left*). In the other 19 percent, the mandibular branch passed in an arc with its lowest point 1 cm or less below the mandibular border (*below, right*). Anterior to the facial artery, the mandibular branch coursed above the mandibular border 100 percent of the time (*above*). (Reprinted with permission from Dingman RO, Grabb WC. Surgical anatomy of the mandibular ramus of the facial nerve based on the dissection of 100 facial halves. *Plast Reconstr Surg Transplant Bull.* 1962;29:266–272.)

### Fat Compartments

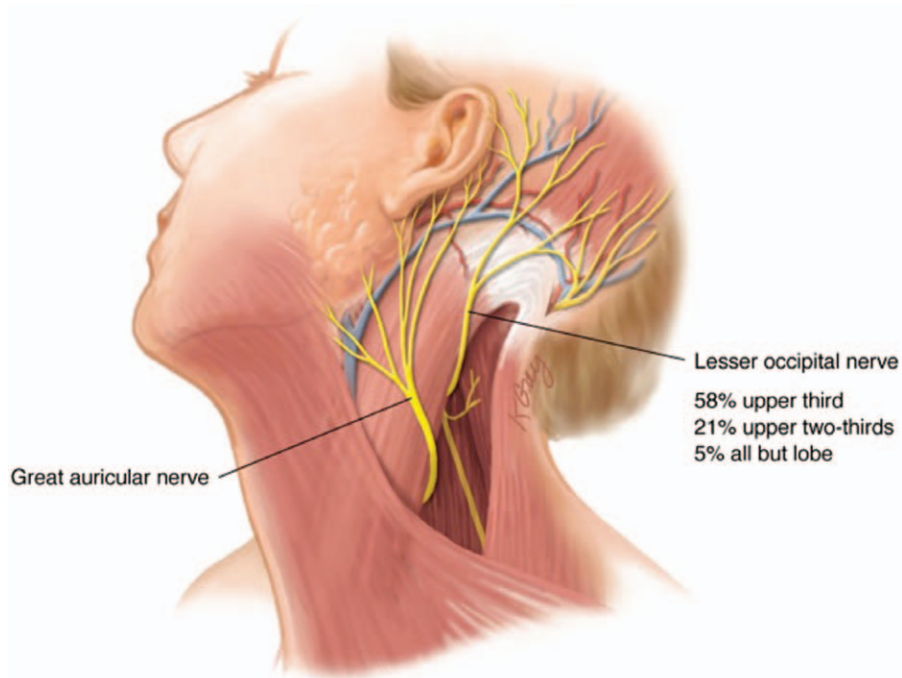
Traditionally, facial fat is broadly divided into superficial and deep layers relative to the SMAS. Further partitioning of these two layers into distinct compartments is not as intuitive. In 2007, Rohrich and Pessa<sup>39</sup> isolated the facial fat compartments as defined by their natural septal boundaries<sup>40,41</sup> using methylene blue dye diffusion in cadaveric specimens. The superficial cheek compartments, from medial to lateral, consist of the nasolabial fat, superficial medial, middle, and lateral temporal cheek fat.<sup>39</sup> The infraorbital fat lies cephalad to the superficial medial cheek fat and, together with the nasolabial fat, are collectively referred to as the superficial malar fat (Fig. 5, *left*).<sup>42</sup> Identification of the deep cheek fat compartments followed thereafter (Fig. 5, *right*).<sup>43,44</sup> The deep medial cheek fat lies deep to the upper lip elevators, with the buccal fat pad situated laterally.<sup>43,44</sup> The sub-orbicularis oculi fat lies deep to the lower lid orbicularis and is adherent to the maxillary periosteum.<sup>45</sup> The fat compartments lend support to Lambros' theory

of relative volumetric gains and losses creating the deep creases of the aging face rather than actual descent of soft tissues.<sup>46</sup> Histologic and clinical studies suggest that preferential deflation of the deep facial fat pads leads to loss of support and descent of the overlying superficial fat, thereby contributing to a “pseudoptosis” of soft tissues that occurs with time.<sup>43,44,47</sup>

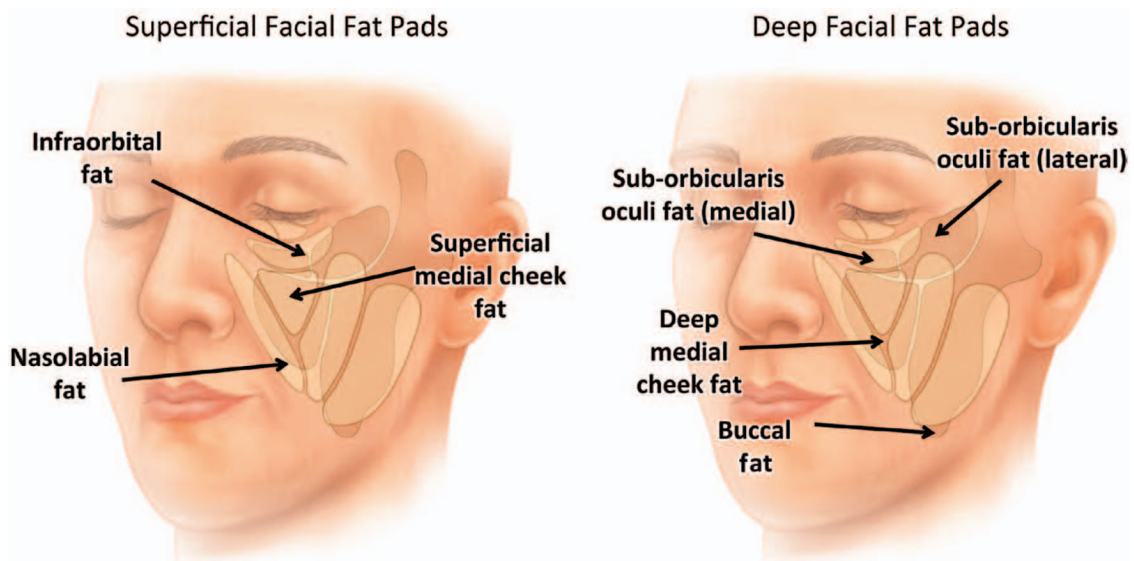
## EVOLUTION OF FACE-LIFT TECHNIQUES

### Subcutaneous Lift

The first forms of face lifting were described in the early 1900s by Miller<sup>48</sup> and Passot<sup>49</sup> as discontinuous ellipsoidal skin excisions in natural skin creases (Fig. 6). In 1927, Bames recognized the importance of wide subcutaneous undermining of the face to achieve an effective lift.<sup>50</sup> The “classic subcutaneous lift” evolved from this concept and is characterized by extensive skin undermining with advancement and excision of excess skin (Fig. 7).<sup>50–55</sup>



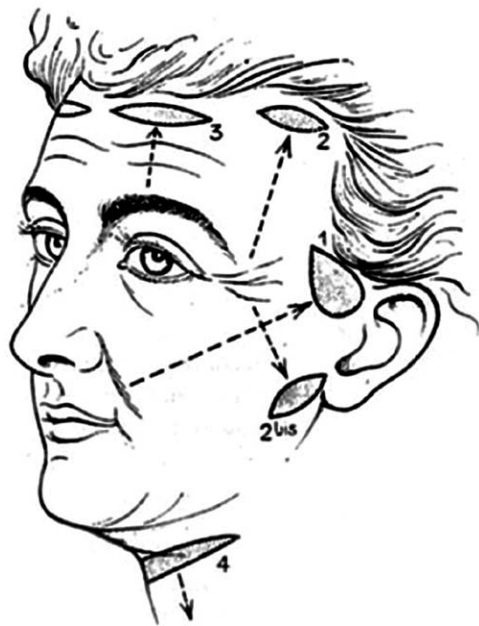
**Fig. 4.** The great auricular nerve exits the posterior border of the sternocleidomastoid muscle and crosses the midbelly of the sternocleidomastoid muscle 6.5 cm inferior to the external auditory canal. The external jugular vein courses anterior to the nerve, and the lesser occipital nerve courses posteriorly. (Reprinted with permission from Barton FE Jr. *Facial Rejuvenation*. Boca Raton, Fla: Quality Medical Publishing/CRC Press; 2008.)



**Fig. 5.** The superficial malar fat compartments (left) include the infraorbital fat, superficial medial cheek fat, and nasolabial fat. The deep midfacial fat compartments (right) include the sub-orbicularis oculi fat, deep medial cheek fat, and part of the buccal fat pad. (Reprinted with permission from Pessa JE, Rohrich RJ. The cheek. In *Facial Topography: Clinical Anatomy of the Face*. St. Louis: Quality Medical Publishing; 2012:77, 47–94.)

To enhance cheek elevation, Aufricht<sup>56</sup> described suture plication of the subcutaneous fatty tissue, whereas Pangman and Wallace<sup>57</sup> suspended the subcutaneous fascial layer as

adjunctive procedures to the subcutaneous lift. These likely represented the earliest descriptions of what is now known as SMAS plication or SMAS suspension, respectively. However, these



**Fig. 6.** The earliest forms of face lifts involved discontinuous ellipsoid skin excisions in natural skin creases. (Reprinted with permission from Barton FE Jr. *Facial Rejuvenation*. Boca Raton, Fla: Quality Medical Publishing/CRC Press; 2008.)

early mentions of deeper layer manipulation were largely ignored, with the subcutaneous lift remaining the predominant procedure for the following two decades.<sup>14</sup> Although subcutaneous lifts are still performed today, they are limited in their ability to reposition deep tissues in patients when used alone.<sup>7,58</sup>

### A Deeper Plane (Sub-SMAS)

In 1974, Skoog's description of a dissection plane deep to the superficial subcutaneous fascia marked the beginning of a renaissance era in face-lifting techniques.<sup>59</sup> This superficial fascial layer was subsequently named the SMAS by Mitz and Peyronie in 1976.<sup>19</sup> Skoog repositioned the skin, SMAS, and platysma as a composite flap, using suspension of the deeper tissues to relieve skin tension. The sub-SMAS dissection yields a thick and robust composite flap with longer lasting results at the expense of a deeper, more dangerous dissection.<sup>60</sup>

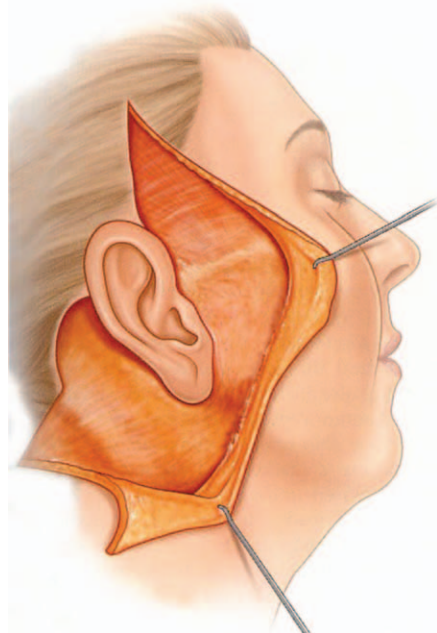
Although revolutionary for its time, Skoog's procedure never gained popularity during his lifetime. Because of concerns for facial nerve injury with deeper dissection, the early sub-SMAS dissections were conservative and rarely extended past the parotid capsule,<sup>14</sup> limiting mobilization of the anterior cheek. Webster et al. in 1982 highlighted the importance of dissecting past the fixed SMAS

overlying the parotid capsule to access the mobile anterior SMAS, to effect a substantial change in the midface (Fig. 8).<sup>61</sup> This transition was substantiated by anatomical studies that better delineated the SMAS anteriorly.<sup>20,21,62–64</sup>

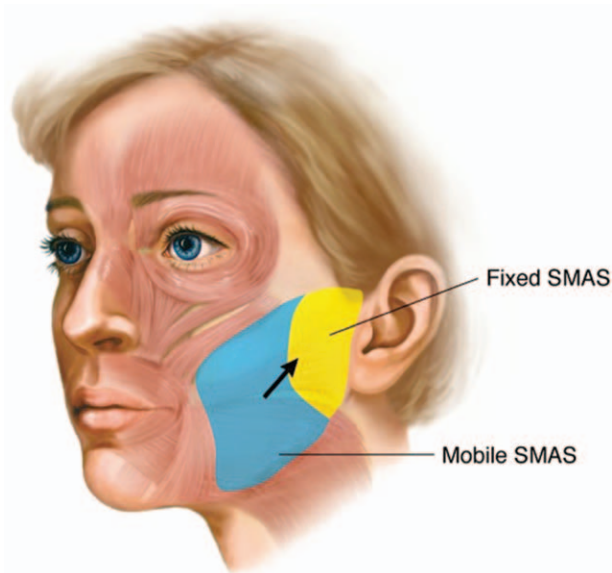
### Composite Lift (Single Skin/SMAS Flap)

The 1980s and 1990s prompted modifications to the Skoog procedure aimed at improving SMAS mobilization while maintaining the original concept of elevating the skin and SMAS layers together as a single unit. Owsley<sup>65</sup> and Lemmon and Hamra<sup>60</sup> described extending the sub-SMAS and subplatysmal dissections to improve midface and neck mobility. Hamra continued Lemmon's work with the "deep-plane rhytidectomy" in 1990, stressing the importance of extending the sub-SMAS dissection medially over the zygomaticus major to lift the anterior cheek.<sup>66</sup> He further refined this procedure in 1992 to a "composite rhytidectomy," describing en bloc suspension of skin, platysma/SMAS, malar fat, and orbicularis oculi as a composite musculocutaneous flap (Fig. 9).<sup>67</sup>

Concurrently, Barton developed the "high SMAS" technique, which was unique for suspending the SMAS more superiorly above the zygomatic arch (Fig. 10). This procedure ensured



**Fig. 7.** The classic subcutaneous lift with pretragal incision and wide subcutaneous undermining of the face. (Reprinted with permission from Pitman GH. *Foundation facelift*. In: Aston SJ, Steinbrech DS, Walden JL, eds. *Aesthetic Plastic Surgery*. London: Elsevier; 2009:121.)



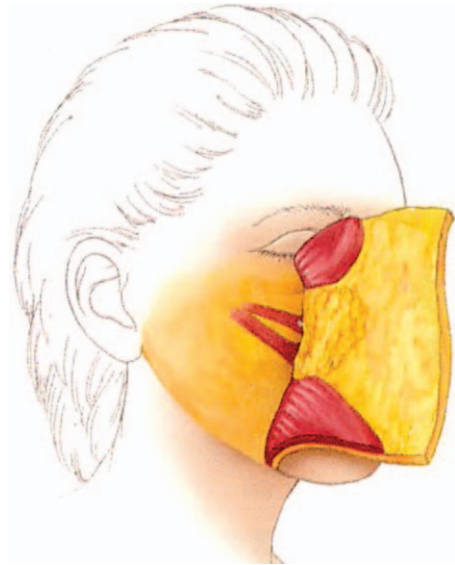
**Fig. 8.** The fixed SMAS in the lateral cheek laminates the parotid capsule and does not transmit motion anteriorly. The mobile SMAS is located anterior to the parotid capsule and glides along the areolar space overlying the masseter and buccal fat pad. To achieve adequate mobilization of the cheek, the sub-SMAS dissection must extend into the area of the mobile SMAS. (Reprinted with permission from Barton FE Jr. *Facial Rejuvenation*. Boca Raton, Fla: Quality Medical Publishing/CRC Press; 2008.)

release of the zygomatic ligaments, allowing a true superior pull of the malar and zygomatic soft tissues (**Level of Evidence: Therapeutic, IV**).<sup>68</sup> By transitioning from the sub-SMAS to subcutaneous plane above the zygomatic major, the cheek skin flap is released from the underlying tether of the SMAS-invested zygomaticus muscle, helping to efface the nasolabial fold (Fig. 11).<sup>21,22</sup>

### Two-Layer Lift (Separate Skin and SMAS Flap)

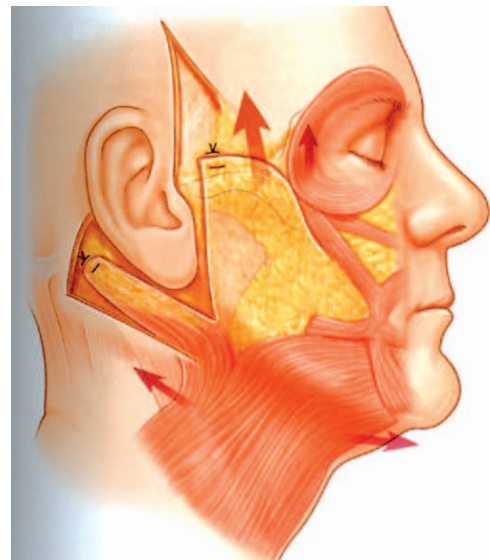
Connell diverged from the original composite lift and instead elevated the skin flap as a separate layer from the SMAS.<sup>69,70</sup> This allowed independent manipulation of the skin and SMAS layers and segmentation of the SMAS flap to create multiple vectors of suspension.

Reports of bifurcating the SMAS flap and using the preauricular posterior margin to suspend the neck separately were initially published in the early 1980s.<sup>71,72</sup> Barton uses a similar bivector approach in the high SMAS (Fig. 10). Connell and Marten furthered this concept with the “trifurcated SMAS flap” in 1995, which incised the SMAS flap into three segments to provide three independent vectors of elevation.<sup>70</sup> The superior segment is anchored vertically to the temporal

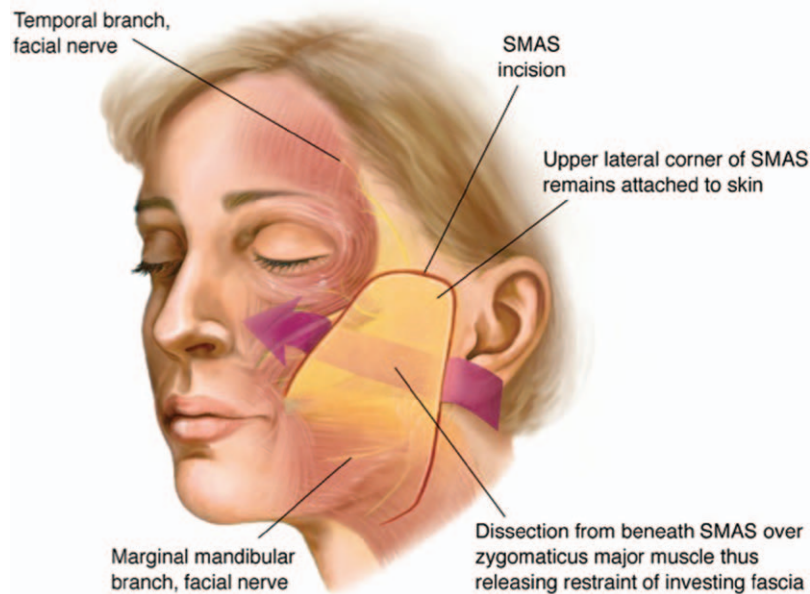


**Fig. 9.** Hamra's composite rhytidectomy, which includes suspension of the orbicularis muscle along with the skin, SMAS, platysma, and malar fat as a single composite unit. (Reprinted with permission from Warren RJ, Aston SJ, Mendelson BC. Face lift. *Plast Reconstr Surg*. 2011;128:747e–764e.)

fascia to suspend the midface and malar tissues. The middle segment is anchored to the cut edge of the SMAS over the zygomatic arch to correct the cheek and jawl. Lastly, the inferior segment is



**Fig. 10.** Barton's high SMAS technique suspends the main SMAS flap vertically above the zygomatic arch to elevate the malar and zygomatic soft tissues. The SMAS flap is incised posteriorly, with the preauricular strip suspended superolaterally to the mastoid fascia to improve neck and jaw contour. (Reprinted with permission from Barton FE Jr, Meade RA. The “High SMAS” face lift technique. In: Aston SJ, Steinbrech DS, Walden JL, eds. *Aesthetic Plastic Surgery*. London: Elsevier; 2009:133.)



**Fig. 11.** Similar to Hamra, Barton transitions his dissection from a sub-SMAS plane to a subcutaneous plane above the zygomaticus muscle. This frees the cheek skin flap from the underlying tether of the SMAS-invested zygomaticus major and helps efface the nasolabial fold. (Reprinted with permission from Barton FE Jr. *Facial Rejuvenation*. Boca Raton, Fla: Quality Medical Publishing/CRC Press; 2008.)

transposed in a primarily posterior vector to the mastoid fascia to correct the neck.

In 1995, Stuzin et al. described a similar two-layer lift, which came to be known as the “extended SMAS” (Fig. 12).<sup>10</sup> Stuzin’s extended SMAS is similar to Barton’s high SMAS in that the SMAS dissection in both techniques extends anteriorly in a plane just superficial to the zygomaticus muscles in an effort to better mobilize the cheek. Conversely, in the extended SMAS, the skin and SMAS layers are raised as two completely separate flaps with varying vectors, whereas Barton’s high SMAS is a composite skin and SMAS flap, separated only in its lateral portions over the parotid to bifurcate the ear. In addition, the excess SMAS in the extended SMAS is rolled onto itself to provide bulk rather than discarded in the high SMAS technique.

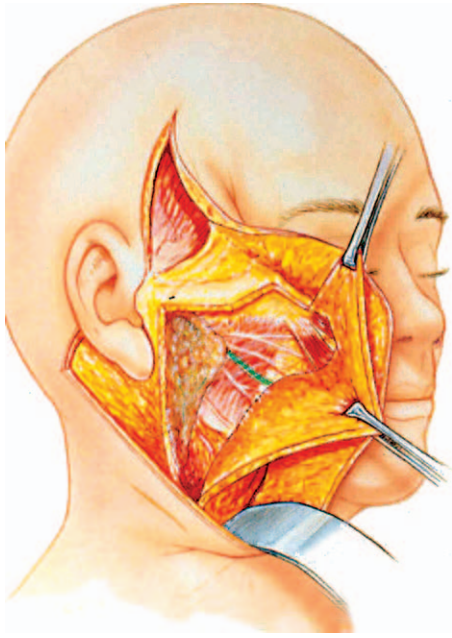
#### Limited Lift with SMAS Manipulation

In 1995, Robbins et al.<sup>73</sup> repopularized Aufricht’s original concept<sup>56</sup> of a simple subcutaneous rhytidectomy supplemented with SMAS plication as an effective alternative to formal SMAS elevation. By plicating the SMAS at the anterior border of masseter, the ptotic nasomandibular tissue is suspended superolaterally to recreate the youthful cheek and blunt the nasolabial fold.

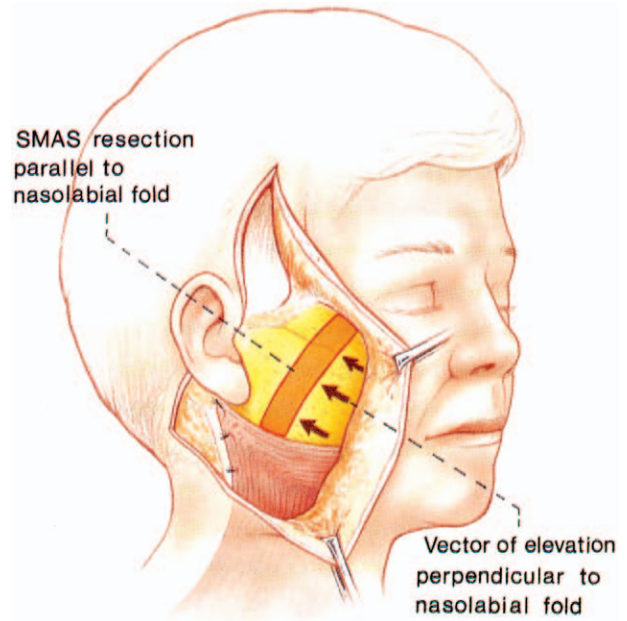
The late 1990s subsequently observed the spectrum swing from extensive sub-SMAS dissections back to subcutaneous rhytidectomies, with the addition of SMAS manipulation. These techniques limit preauricular incisions and skin undermining to only that needed for SMAS plication, thus minimizing morbidity, recovery time, and scar visibility while still providing reliable results. Proponents of the limited lift argue that SMAS plication is just as effective as formal SMAS elevation, and that complete release of the retaining ligaments is unnecessary, as they are already attenuated with age.<sup>74</sup> Adversaries argue that superior results are achieved with formal SMAS elevation and complete release of the deep cheek attachments.<sup>14</sup> Regardless, SMAS plication can be a useful alternative if the SMAS is thin and prone to tearing with attempted elevation.<sup>10</sup>

Baker described the lateral SMASectomy<sup>75,76</sup> in 1997 as a modification to the standard SMAS plication. In Baker’s procedure, a strip of SMAS overlying the anterior parotid edge is excised rather than plicated (Fig. 13). The mobile anterior edge of the excised SMAS is then secured to the fixed SMAS edge overlying the gland in a vector perpendicular to the nasolabial fold.

In 1999, Saylan proposed the “S-lift,” in which purse-string sutures are used to plicate the SMAS.<sup>77</sup> The S-lift refers to the S-shaped preauricular skin



**Fig. 12.** An illustration of Stuzin's extended SMAS. The skin flap is elevated as a separate layer from the SMAS flap to allow independent manipulation of the two layers. (Reprinted with permission from Stuzin JM. Extended SMAS facelift: Restoring facial shape in facelifting. In: Aston SJ, Steinbrech DS, Walden JL, eds. *Aesthetic Plastic Surgery*. London: Elsevier; 2009:92.)



**Fig. 13.** In Baker's lateral SMASectomy, a strip of SMAS overlying the anterior parotid edge is excised. The cut edge of the anterior mobile SMAS is then suspended to the fixed edge of the fixed SMAS overlying the parotid gland. (Reprinted with permission from Baker DC. Lateral SMASectomy. *Plast Reconstr Surg*. 1997;100:509–513.)

excision made to access the SMAS. Tonnard et al. modified this procedure 3 years later with the “minimal access cranial suspension,” or “MACS lift.”<sup>78</sup> Through a limited preauricular incision, Tonnard et al. similarly placed purse-string sutures in various locations in the SMAS, suspending ptotic facial tissues to the deep temporal fascia above the arch (Fig. 14). Although limited by the occasional suture tear-through and anecdotally transient effects, the minimal access cranial suspension lift has quickly become one of the more popular face-lift procedures performed today.<sup>58</sup>

### Individualized Approaches: Focus on Vectors and Volume

Recent publications in the face-lift literature have focused on individualized treatment plans to accommodate patient-specific facial shapes, vectors, and volumetric requirements. In 2007, Stuzin described an algorithm for SMAS procedures tailored to the long versus wide face.<sup>79</sup> For the long face, he recommends extending the SMAS dissection medially with resuspension in an oblique vector to restore malar volume and width. For the wide face, he proposes limiting SMAS dissection medially and suspending the soft tissues in a vertical vector to reposition the submalar fat superiorly.

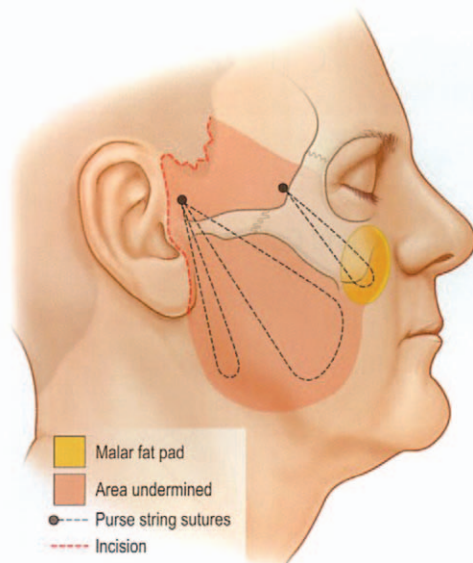
Similarly, the “individualized component” face-lift approach described by Rohrich et al. in 2009 advocates extensive skin undermining and SMAS stacking in the oblique vector to enhance cheek fullness in the long, narrow face (Fig. 15).<sup>74</sup> For the short, wide face, Rohrich et al. recommend limited skin undermining, with SMAS excision (SMASectomy) and resuspension in the vertical vector to enhance submalar hollowing. To further customize his results, Rohrich et al. added fat compartment-guided fat transfers for a simultaneous “lift-and-fill” face lift.<sup>80</sup>

## COMPLICATIONS

### Hematoma

Hematoma is the most common early complication following face-lift surgery. Resorption of adrenalin in the early postoperative period can lead to rebound hypertension and subsequent hematoma.<sup>81</sup> The incidence in nonhypertensive patients is approximately 3 percent, but the incidence rises approximately 8 percent in hypertensive patients and in male patients (**Level of Evidence: Therapeutic, IV**).<sup>82</sup>

The most common cause of hematoma is related to uncontrolled blood pressure. Patients



**Fig. 14.** The minimal access cranial suspension lift described by Tonnard et al. uses purse-string sutures to suspend the SMAS in different vectors to the deep temporal fascia. (Reprinted with permission from Warren RJ, Aston SJ, Mendelson BC. Face lift. *Plast Reconstr Surg.* 2011;128:747e–764e; and Tonnard PL, Verpaele AM, Morrison CM. MACS face lift. In: Aston SJ, Steinbrech DS, Walden JL, eds. *Aesthetic Plastic Surgery*. London: Elsevier; 2009:138.)

who preoperatively have a history of hypertension should be instructed to take their blood pressure medications on the morning of surgery. As an adjunct, oral clonidine (0.1 to 0.3 mg) or a transdermal patch (0.1 to 0.2 mg) can be administered preoperatively or intraoperatively, respectively, to keep blood pressure low in the perioperative period, especially as the injected adrenalin absorbs. Intraoperative hypertension should be well controlled, and maintenance of postoperative systolic blood pressure below 140 mmHg is desirable.<sup>7</sup> Beta-blockers (5 to 10 mg of labetalol) or calcium channel blockers (0.25-mg bolus of nicardipine) can maintain blood pressure intraoperatively. Of note, one should avoid additional beta-blockers for patients currently receiving beta-blockers to prevent relative bradycardia. Injected adrenalin from the local anesthetic solution is slowly absorbed, such that postoperative hematomas usually occur 4 to 10 hours after surgery. Postoperatively, blood pressure can be controlled with beta blockade (100 mg of oral labetalol) or an alpha agonist (0.1 to 0.3 mg of clonidine).<sup>7</sup> Concurrently, pain, restlessness, and/or nausea must be controlled, as each factor may increase blood pressure and the development of a hematoma.<sup>83</sup>

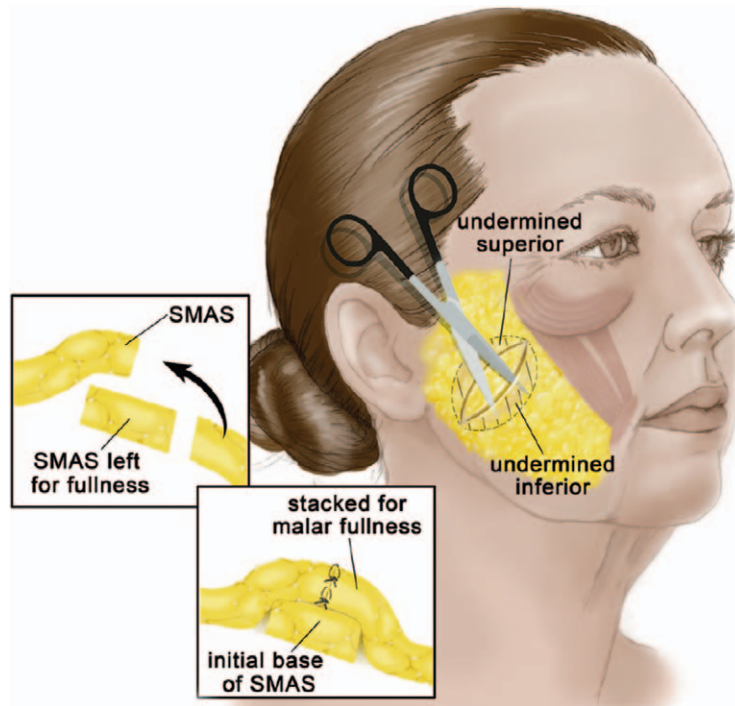
The incidence of hematoma is increased in patients taking platelet-inhibiting medications such as aspirin and other nonsteroidal antiinflammatory drugs. Supplements with antiplatelet or anticoagulant properties can also increase perioperative bleeding risk. These agents include but are not limited to garlic, ginger, vitamin E, fish oil, glucosamine, and green tea.<sup>84</sup> Such medications should be discontinued 2 to 3 weeks before elective surgery.<sup>83,84</sup> Intravenous desmopressin may be administered for intraoperative bleeding associated with presumed platelet inhibition.<sup>85</sup> Furthermore, a concurrent open anterior platysmaplasty with rhytidectomy significantly increases the risk of hematoma.<sup>86,87</sup> Of note, the most important aspect in preventing hematoma after blood pressure is meticulous hemostasis.<sup>83</sup>

An expanding hematoma is most likely to occur in the first 24 hours after surgery and should be evacuated promptly. Early intervention will prevent subsequent necrosis of skin flaps caused by edema and tissue ischemia.<sup>7,83</sup> Although return to the operating room for exploration is the classic treatment, bedside evacuation with a suction catheter has been successful in managing early, acute unilateral hematomas in cooperative patients with controlled blood pressure.<sup>88</sup>

### Skin Necrosis

The incidence of skin necrosis following cervical rhytidectomy ranges from 1 percent in sub-SMAS procedures to 3.6 percent in subcutaneous face lifts.<sup>81</sup> The incidence of skin flap ischemia is significantly higher with overly thin flap dissections, excessive tension, hematoma, constrictive dressings, and vascular occlusive disorders, particularly smokers.<sup>81,89</sup> Skin necrosis should be addressed conservatively with local wound care; the majority of cases will eventually heal spontaneously.

Adaptations in the postoperative regimen can minimize flap edema and subsequent ischemia. Postoperative drains will collect perioperative serum, preventing fluid from collecting under the skin flaps. However, drains do not prevent or remove significant hematoma. In addition, avoidance of neck dressings will prevent pressure necrosis of the thin neck flaps and allow appropriate venous return. Furthermore, restriction of salt and water intake may limit postoperative edema, which affects not only tissue ischemia but also stress relaxation of the skin flaps.<sup>14</sup>



**Fig. 15.** In SMAS stacking, SMAS incision and plication stacks tissue in the direction that the SMAS is lifted. SMAS stacking in the oblique vector is beneficial in narrow faces that require more malar fullness. (Reprinted with permission from Rohrich RJ, Ghavami A, Lemmon JA, Brown SA. The individualized component face lift: Developing a systematic approach to facial rejuvenation. *Plast Reconstr Surg.* 2009;123:1050–1063.)

## Infection

The incidence of wound infections is very rare following cervical rhytidectomy. Intravenous perioperative antibiotics for *Staphylococcus aureus* or *Staphylococcus epidermidis* prophylaxis (typically a cephalosporin or vancomycin) are routinely given, even though there is little evidence to support their administration. Preauricular infections may result from *Pseudomonas aeruginosa* colonizing the otic canal.<sup>90</sup> *Pseudomonas* infections usually respond to oral ciprofloxacin but may require incision and drainage.

In known carriers or those at risk (health care professionals) for methicillin-resistant *S. aureus*, nasal and ear canal cultures can be swabbed for screening.<sup>91</sup> If present, patients can treat mucosal colonizations and skin flora with topical mupirocin ointment for 7 to 10 days and chlorhexidine soap body washes for 5 days preoperatively.<sup>92</sup> Postoperative methicillin-resistant *S. aureus* infections are treated by oral trimethoprim/sulfamethoxazole or intravenous vancomycin.

## Nerve Injury

Historically, the incidence of a permanent facial nerve motor branch injury following a

subcutaneous or sub-SMAS face lift is less than 1 percent.<sup>81</sup> Transient nerve dysfunction in the first few hours postoperatively is very common and attributable to the lingering effects of local anesthetic.<sup>93</sup> Prolonged nerve dysfunction identified days later may be attributable to traction, cautery, sutures, or surgical division.<sup>83</sup> Spontaneous recovery is usually noted within 3 to 4 months. The most commonly injured motor branches are likely buccal; however, they often go unnoticed or are more forgiving because of the rich collateralization of the branches.<sup>24,83,93</sup> The frontal branch and the marginal mandibular branch are less tolerant to injury because of their minimal arborization and are most likely to result in clinically significant sequelae after injury.<sup>24,94</sup> Temporary paralysis of contralateral mimetic muscles with botulinum toxin can improve symmetry while the patient is waiting for motor nerve recovery in unilateral marginal or cervical branch palsy.

Sensory innervation of the skin flap is always disrupted following rhytidectomy; however, patients typically recover spontaneously, usually within 12 months. The most commonly injured sensory nerve is the great auricular nerve. A

recognized injury should be repaired immediately intraoperatively. A painful neuroma may form after injury and/or repair, but this sequela is fortunately rare.<sup>83</sup>

### Unsatisfactory Scars

Improper incision placement can lead to obvious scars, distortion of the ear, and unnatural shifting of the hairline. Excessive tension can lead to loss of hair, depigmentation, and widened scars.<sup>83,93</sup> Incisions within the hairline should be beveled to preserve the hair follicles so that hair may grow through the incision to camouflage any scar.<sup>14</sup>

In the early postoperative period, antibiotic ointment applied daily will epithelialize wounds faster and improve scar outcomes. Widened or irregular scars can be improved with scar revision, which should be deferred to at least 6 months postoperatively, when tissues have relaxed. Hypertrophic scars can be treated with intralesional steroid injections at monthly intervals.<sup>14</sup>

### Smoking

The incidence of face-lift skin flap necrosis is 12.5 times greater in smokers than in nonsmokers.<sup>95</sup> Smoking acutely induces temporary vasospasm<sup>96</sup> and chronically stimulates permanent obliterative endarteritis.<sup>97</sup> Consequently, smoking creates an environment of relative tissue hypoxia and delayed wound healing mediated by vasoconstriction, abnormal cellular function, and thrombogenesis.<sup>98</sup>

Patients should abstain from smoking 4 weeks before surgery and 4 weeks after surgery. Sudden withdrawal of nicotine products is often unsuccessful because of their addictive nature. A gradual transition course with nicotine gum or patch, supplemented with psychotherapeutic drugs, may be more effective for smoking cessation.<sup>7</sup>

Of note, patients typically underreport their smoking habits. Given the potential ischemic complications of smoking, surgeons may be advised to screen suspicious patients. Cotinine, the metabolic byproduct of nicotine, can be detected for up to 4 days after smoking.<sup>99</sup> A urinary or salivary cotinine test is available for practitioners and is equally efficacious.<sup>100,101</sup>

**Kevin H. Small, M.D.**

Department of Plastic Surgery  
University of Texas Southwestern Medical Center  
1801 Inwood Road  
Dallas, Texas 75390  
kevinmallmd@gmail.com

### REFERENCES

1. Gonzalez-Ulloa M, Flores ES. Senility of the face: Basic study to understand its causes and effects. *Plast Reconstr Surg*. 1965;36:239–246.
2. Pessa JE. An algorithm of facial aging: Verification of Lambros's theory by three-dimensional stereolithography, with reference to the pathogenesis of midfacial aging, scleral show, and the lateral suborbital trough deformity. *Plast Reconstr Surg*. 2000;106:479–488; discussion 489–490.
3. Shaw RB Jr, Katzel EB, Koltz PF, et al. Aging of the facial skeleton: Aesthetic implications and rejuvenation strategies. *Plast Reconstr Surg*. 2011;127:374–383.
4. Yaremchuk MJ. Improving periorbital appearance in the "morphologically prone". *Plast Reconstr Surg*. 2004;114:980–987.
5. Barton FE Jr, Ha R, Awada M. Fat extrusion and septal reset in patients with the tear trough triad: A critical appraisal. *Plast Reconstr Surg*. 2004;113:2115–2121; discussion 2122–2123.
6. Jelks GW, Jelks EB. The influence of orbital and eyelid anatomy on the palpebral aperture. *Clin Plast Surg*. 1991;18:183–195.
7. Barton FE Jr. Aesthetic surgery of the face and neck. *Aesthet Surg J*. 2009;29:449–463; quiz 464–466.
8. Furnas DW. The retaining ligaments of the cheek. *Plast Reconstr Surg*. 1989;83:11–16.
9. Stuzin JM, Baker TJ, Gordon HL. The relationship of the superficial and deep facial fascias: Relevance to rhytidectomy and aging. *Plast Reconstr Surg*. 1992;89:441–449; discussion 450–451.
10. Stuzin JM, Baker TJ, Gordon HL, Baker TM. Extended SMAS dissection as an approach to midface rejuvenation. *Clin Plast Surg*. 1995;22:295–311.
11. Reece EM, Pessa JE, Rohrich RJ. The mandibular septum: Anatomical observations of the jowls in aging. Implications for facial rejuvenation. *Plast Reconstr Surg*. 2008;121:1414–1420.
12. Gosain AK, Amarante MT, Hyde JS, Yousif NJ. A dynamic analysis of changes in the nasolabial fold using magnetic resonance imaging: Implications for facial rejuvenation and facial animation surgery. *Plast Reconstr Surg*. 1996;98:622–636.
13. Owsley JQ, Roberts CL. Some anatomical observations on midface aging and long-term results of surgical treatment. *Plast Reconstr Surg*. 2008;121:258–268.
14. Barton FE Jr. *Facial Rejuvenation*. Boca Raton, Fla: Quality Medical Publishing/CRC Press; 2008.
15. Freilinger G, Gruber H, Happak W, Pechmann U. Surgical anatomy of the mimic muscle system and the facial nerve: Importance for reconstructive and aesthetic surgery. *Plast Reconstr Surg*. 1987;80:686–690.
16. Bell C. *A System of Dissections, Part 2*. Edinburgh: Mundell & Son; 1799.
17. Pessa JE, Desvigne LD, Lyons AE. An early description of the superficial musculoaponeurotic system by Sir Charles Bell. *Plast Reconstr Surg*. 1999;103:1071–1072; discussion 1073.
18. Gray H. *Anatomy: Descriptive and Surgical*. Philadelphia: Balanchard and Lea; 1859.
19. Mitz V, Peyronie M. The superficial musculo-aponeurotic system (SMAS) in the parotid and cheek area. *Plast Reconstr Surg*. 1976;58:80–88.
20. Wassef M. Superficial fascial and muscular layers in the face and neck: A histological study. *Aesthetic Plast Surg*. 1987;11:171–176.
21. Barton FE Jr. The SMAS and the nasolabial fold. *Plast Reconstr Surg*. 1992;89:1054–1057; discussion 1058–1059.
22. Barton FE Jr. Rhytidectomy and the nasolabial fold. *Plast Reconstr Surg*. 1992;90:601–607.

23. Davis RA, Anson BJ, Budinger JM, Kurth LR. Surgical anatomy of the facial nerve and parotid gland based upon a study of 350 cervicofacial halves. *Surg Gynecol Obstet.* 1956;102:385–412.
24. Baker DC, Conley J. Avoiding facial nerve injuries in rhytidectomy: Anatomical variations and pitfalls. *Plast Reconstr Surg.* 1979;64:781–795.
25. Pitanguy I, Ramos AS. The frontal branch of the facial nerve: The importance of its variations in face lifting. *Plast Reconstr Surg.* 1966;38:352–356.
26. Trinei FA, Januszkiewicz J, Nahai F. The sentinel vein: An important reference point for surgery in the temporal region. *Plast Reconstr Surg.* 1998;101:27–32.
27. Isse NG. Endoscopic forehead lift: Evolution and update. *Clin Plast Surg.* 1995;22:661–673.
28. De La Plaza R, Valiente E, Arroyo JM. Supraperiosteal lifting of the upper two-thirds of the face. *Br J Plast Surg.* 1991;44:325–332.
29. Al-Kayat A, Bramley P. A modified pre-auricular approach to the temporomandibular joint and malar arch. *Br J Oral Surg.* 1979;17:91–103.
30. Trussler AP, Stephan P, Hatef D, Schaverien M, Meade R, Barton FE. The frontal branch of the facial nerve across the zygomatic arch: Anatomical relevance of the high-SMAS technique. *Plast Reconstr Surg.* 2010;125:1221–1229.
31. Dingman RO, Grabb WC. Surgical anatomy of the mandibular ramus of the facial nerve based on the dissection of 100 facial halves. *Plast Reconstr Surg Transplant Bull.* 1962;29:266–272.
32. Nelson DW, Gingrass RP. Anatomy of the mandibular branches of the facial nerve. *Plast Reconstr Surg.* 1979;64:479–482.
33. Cicekcibasi A, Yilmaz M, Kiresi D, Seker M. The mandibular landmarks about the facial artery and vein with multidetector computed tomography angiography (MDCTA): An anatomical and radiological morphometric study. *Int J Morphol.* 2012;30:504–509.
34. Ellis E, Zide MF. *Surgical Approaches to the Facial Skeleton.* 2nd ed. Philadelphia: Lippincott Williams & Wilkins; 2006.
35. Rohrich RJ, Taylor NS, Ahmad J, Lu A, Pessa JE. Great auricular nerve injury, the “subauricular band” phenomenon, and the periauricular adipose compartments. *Plast Reconstr Surg.* 2011;127:835–843.
36. Pantaloni M, Sullivan P. Relevance of the lesser occipital nerve in facial rejuvenation surgery. *Plast Reconstr Surg.* 2000;105:2594–2599; discussion 2600–2603.
37. McKinney P, Katrana DJ. Prevention of injury to the great auricular nerve during rhytidectomy. *Plast Reconstr Surg.* 1980;66:675–679.
38. McKinney P, Gottlieb J. The relationship of the great auricular nerve to the superficial musculoaponeurotic system. *Ann Plast Surg.* 1985;14:310–314.
39. Rohrich RJ, Pessa JE. The fat compartments of the face: Anatomy and clinical implications for cosmetic surgery. *Plast Reconstr Surg.* 2007;119:2219–2227; discussion 2228–2231.
40. Schaverien MV, Pessa JE, Rohrich RJ. Vascularized membranes determine the anatomical boundaries of the subcutaneous fat compartments. *Plast Reconstr Surg.* 2009;123:695–700.
41. Rohrich RJ, Pessa JE. The retaining system of the face: Histologic evaluation of the septal boundaries of the subcutaneous fat compartments. *Plast Reconstr Surg.* 2008;121:1804–1809.
42. Owsley JQ. Lifting the malar fat pad for correction of prominent nasolabial folds. *Plast Reconstr Surg.* 1993;91:463–474; discussion 475–476.
43. Gierloff M, Stöhring C, Buder T, Gassling V, Açil Y, Wiltfang J. Aging changes of the midfacial fat compartments: A computed tomographic study. *Plast Reconstr Surg.* 2012;129:263–273.
44. Rohrich RJ, Pessa JE, Ristow B. The youthful cheek and the deep medial fat compartment. *Plast Reconstr Surg.* 2008;121:2107–2112.
45. Rohrich RJ, Arbique GM, Wong C, Brown S, Pessa JE. The anatomy of suborbicularis fat: Implications for periorbital rejuvenation. *Plast Reconstr Surg.* 2009;124:946–951.
46. Lambros V. Observations on periorbital and midface aging. *Plast Reconstr Surg.* 2007;120:1367–1376; discussion 1377.
47. Wan D, Amirlak B, Giessler P, et al. The differing adipocyte morphologies of deep versus superficial midfacial fat compartments: A cadaveric study. *Plast Reconstr Surg.* 2014;133:615e–622e.
48. Miller C. *The Correction of Featural Imperfections.* Chicago: Oak Printing Company; 1907.
49. Passot R. La chirurgie esthétique des rides du visage. *Presse Med.* 1919;27:258–262.
50. Bames O. Truth and fallacies of face peeling and facelifting. *Med J Rec.* 1927;126:86–87.
51. Conway H. The surgical face lift–rhytidectomy. *Plast Reconstr Surg.* 1970;45:124–130.
52. Bourguet J. La disparition chirurgicale des rides et plis du visage. *Bull Acad Med (Paris)* 1919;82:183.
53. Duffy MJ, Friedland JA. The superficial-plane rhytidectomy revisited. *Plast Reconstr Surg.* 1994;93:1392–1403; discussion 1404–1405.
54. Hoefflin SM. The extended supraplatysmal plane (ESP) face lift. *Plast Reconstr Surg.* 1998;101:494–503.
55. González-Ulloa M. The history of rhytidectomy. *Aesthetic Plast Surg.* 1980;4:1–45.
56. Aufricht G. Surgery for excess skin of the face. In: *Transactions of the Second International Congress of Plastic and Reconstructive Surgery.* Edinburgh: E & S Livingstone; 1960:495–502.
57. Pangman WJ II, Wallace RM. Cosmetic surgery of the face and neck. *Plast Reconstr Surg Transplant Bull.* 1961;27:544–550.
58. Adamson PA, Litner JA. Evolution of rhytidectomy techniques. *Facial Plast Surg Clin North Am.* 2005;13:383–391.
59. Skoog T. *Plastic Surgery: New Methods and Refinements.* Philadelphia: Saunders; 1974.
60. Lemmon ML, Hamra ST. Skoog rhytidectomy: A five-year experience with 577 patients. *Plast Reconstr Surg.* 1980;65:283–297.
61. Webster RC, Smith RC, Papsidero MJ, Karolow WW, Smith KF. Comparison of SMAS plication with SMAS imbrication in face lifting. *Laryngoscope* 1982;92:901–912.
62. Yousif NJ, Gosain A, Matloub HS, Sanger JR, Madiedo G, Larson DL. The nasolabial fold: An anatomic and histologic reappraisal. *Plast Reconstr Surg.* 1994;93:60–69.
63. Pensler JM, Ward JW, Parry SW. The superficial musculoaponeurotic system in the upper lip: An anatomic study in cadavers. *Plast Reconstr Surg.* 1985;75:488–494.
64. Jost G, Levat Y. Parotid fascia and face lifting: A critical evaluation of the SMAS concept. *Plast Reconstr Surg.* 1984;74:42–51.
65. Owsley JQ Jr. Platysma-fascial rhytidectomy: A preliminary report. *Plast Reconstr Surg.* 1977;60:843–850.
66. Hamra ST. The deep-plane rhytidectomy. *Plast Reconstr Surg.* 1990;86:53–61; discussion 62–63.
67. Hamra ST. Composite rhytidectomy. *Plast Reconstr Surg.* 1992;90:1–13.
68. Barton FE Jr, Hunt J. The high-superficial musculoaponeurotic system technique in facial rejuvenation: An update. *Plast Reconstr Surg.* 2003;112:1910–1917.

69. Connell BF. Eyebrow, face, and neck lifts for males. *Clin Plast Surg*. 1978;5:15–28.
70. Connell BF, Marten TJ. The trifurcated SMAS flap: Three-part segmentation of the conventional flap for improved results in the midface, cheek, and neck. *Aesthetic Plast Surg*. 1995;19:415–420.
71. Jost G, Lamouche G. SMAS in rhytidectomy. *Aesthetic Plast Surg*. 1982;6:69–74.
72. Randall P, Skiles MS. The “SMAS sling”: An additional fixation in face lift surgery. *Ann Plast Surg*. 1984;12:5–9.
73. Robbins LB, Brothers DB, Marshall DM. Anterior SMAS plication for the treatment of prominent nasomandibular folds and restoration of normal cheek contour. *Plast Reconstr Surg*. 1995;96:1279–1287; discussion 1288.
74. Rohrich RJ, Ghavami A, Lemmon JA, Brown SA. The individualized component face lift: Developing a systematic approach to facial rejuvenation. *Plast Reconstr Surg*. 2009;123:1050–1063.
75. Baker DC. Lateral SMASectomy. *Plast Reconstr Surg*. 1997;100:509–513.
76. Baker DC. Minimal incision rhytidectomy (short scar face lift) with lateral SMASectomy: Evolution and application. *Aesthet Surg J*. 2001;21:14–26.
77. Saylan Z. The S-lift for facial rejuvenation. *Int J Cosmet Surg*. 1999;7:18–23.
78. Tonnard P, Verpaele A, Monstrey S, et al. Minimal access cranial suspension lift: A modified S-lift. *Plast Reconstr Surg*. 2002;109:2074–2086.
79. Stuzin JM. Restoring facial shape in face lifting: The role of skeletal support in facial analysis and midface soft-tissue repositioning. *Plast Reconstr Surg*. 2007;119:362–376; discussion 377–378.
80. Rohrich RJ, Ghavami A, Constantine FC, Unger J, Mojallal A. Lift-and-fill face lift: Integrating the fat compartments. *Plast Reconstr Surg*. 2014;133:756e–767e.
81. Barton FE Jr. The aging face: Rhytidectomy and adjunctive procedures. *Select Read Plast Surg*. 2001;6:
82. Baker DC, Stefani WA, Chiu ES. Reducing the incidence of hematoma requiring surgical evacuation following male rhytidectomy: A 30-year review of 985 cases. *Plast Reconstr Surg*. 2005;116:1973–1985; discussion 1986–1987.
83. Stuzin JM. MOC-PSSM CME article: Face lifting. *Plast Reconstr Surg*. 2008;121 (Suppl):1–19.
84. Wong WW, Gabriel A, Maxwell GP, Gupta SC. Bleeding risks of herbal, homeopathic, and dietary supplements: A hidden nightmare for plastic surgeons? *Aesthet Surg J*. 2012;32:332–346.
85. Palaia DA, Rosenberg MH, Bonanno PC. The use of DDAVP desmopressin reduces the incidence of microhematomas after faciolplasty. *Ann Plast Surg*. 2001;46:463–466.
86. Jones BM, Grover R. Avoiding hematoma in cervicofacial rhytidectomy: A personal 8-year quest. Reviewing 910 patients. *Plast Reconstr Surg*. 2004;113:381–387; discussion 388–390.
87. Grover R, Jones BM, Waterhouse N. The prevention of hematoma following rhytidectomy: A review of 1078 consecutive facelifts. *Br J Plast Surg*. 2001;54:481–486.
88. Baker DC, Chiu ES. Bedside treatment of early acute rhytidectomy hematomas. *Plast Reconstr Surg*. 2005;115:2119–2122; discussion 2123.
89. Riefkohl R, Wolfe JA, Cox EB, McCarty KS Jr. Association between cutaneous occlusive vascular disease, cigarette smoking, and skin slough after rhytidectomy. *Plast Reconstr Surg*. 1986;77:592–595.
90. Roland PS, Stroman DW. Microbiology of acute otitis externa. *Laryngoscope* 2002;112:1166–1177.
91. Ammerlaan HS, Kluytmans JA, Wertheim HF, Nouwen JL, Bonten MJ. Eradication of methicillin-resistant *Staphylococcus aureus* carriage: A systematic review. *Clin Infect Dis*. 2009;48:922–930.
92. Buehlmann M, Frei R, Fenner L, Dangel M, Fluckiger U, Widmer AF. Highly effective regimen for decolonization of methicillin-resistant *Staphylococcus aureus* carriers. *Infect Control Hosp Epidemiol*. 2008;29:510–516.
93. Warren RJ, Aston SJ, Mendelson BC. Face lift. *Plast Reconstr Surg*. 2011;128:747e–764e.
94. McGregaor M, Greenberg R. The unfavorable result in plastic surgery: Avoidance and treatment. In: Goldwyn R, ed. *Rhytidectomy*. Boston: Little, Brown; 1972.
95. Rees TD, Liverett DM, Guy CL. The effect of cigarette smoking on skin-flap survival in the face lift patient. *Plast Reconstr Surg*. 1984;73:911–915.
96. van Adrichem LN, Hovius SE, van Strik R, van der Meulen JC. The acute effect of cigarette smoking on the microcirculation of a replanted digit. *J Hand Surg Am*. 1992;17:230–234.
97. Sarin CL, Austin JC, Nickel WO. Effects of smoking on digital blood-flow velocity. *JAMA* 1974;229:1327–1328.
98. Krueger JK, Rohrich RJ. Clearing the smoke: The scientific rationale for tobacco abstinence with plastic surgery. *Plast Reconstr Surg*. 2001;108:1063–1073; discussion 1074–1077.
99. Knobloch K, Gohritz A, Reuss E, Vogt PM. Nicotine in plastic surgery: A review (in German). *Chirurg* 2008;79:956–962.
100. Chadwick CA, Keevil B. Measurement of cotinine in urine by liquid chromatography tandem mass spectrometry. *Ann Clin Biochem*. 2007;44:455–462.
101. Montalto NJ, Wells WO. Validation of self-reported smoking status using saliva cotinine: A rapid semiquantitative dipstick method. *Cancer Epidemiol Biomarkers Prev*. 2007;16:1858–1862.