

The background of the cover is a sepia-toned photograph of a large, ancient tree. The trunk is thick and textured, and its roots are exposed and spread out across the ground in the foreground. The background shows a grassy field and other trees in the distance.

CDA

Treatment Planning

Extraction

Occlusion

JOURNAL OF THE CALIFORNIA DENTAL ASSOCIATION VOL.33 NO.4

April 2005

Implant Dentistry

SAJID A. JIVRAJ, DDS, MSED



DEPARTMENTS

- 269** *The Editor/Bored of the Board?*
272 *Feedback/Saving the Teeth*
277 *Impressions/Dental Education Under Review*
358 *Dr. Bob/What's the Rush?*

FEATURES

- 289** **TREATMENT PLANNING IN IMPLANT DENTISTRY**
An introduction to the issue.
Sajid A. Jivraj, DDS, MSED
- 293** **AN INTERDISCIPLINARY APPROACH TO TREATMENT PLANNING IN IMPLANT DENTISTRY**
Sajid A. Jivraj, DDS, MSED; Paolo Corrado, MD, DDS; and Winston W.L. Chee, DDS
- 303** **IMMEDIATE IMPLANT PLACEMENT: DIAGNOSIS, TREATMENT PLANNING AND TREATMENT STEPS FOR SUCCESSFUL OUTCOMES**
William Becker, DDS, MSD
- 313** **TREATMENT PLANNING: IMPLANT-SUPPORTED PARTIAL OVERDENTURES**
Winston W. L. Chee, DDS
- 319** **TO EXTRACT OR NOT TO EXTRACT? FACTORS THAT AFFECT INDIVIDUAL TOOTH PROGNOSIS**
Nikitas Mordohai, DDS; Mamaly Reshad, BDS, MSc; and Sajid A. Jivraj, DDS, MSED
- 329** **ISSUES AND CONSIDERATIONS IN DENTAL IMPLANT OCCLUSION: WHAT DO WE KNOW AND WHAT DO WE NEED TO FIND OUT?**
C.M. Stanford, DDS, PhD
- 337** **IMMEDIATE LOADING OF DENTAL IMPLANTS: OVERVIEW AND RATIONALE**
Krikor Derbabian, DDS, and Krikor Simonian, DDS

Bored of the Board?

In a sweeping move during his State of the State address last January, Gov. Arnold Schwarzenegger called for the incorporation of the functions of more than 80 licensing boards and regulatory commissions, including the Dental Board of California, into the Department of Consumer Affairs. His reasoning appeared to be one step in making "government more responsive and accountable to the people it serves." Recently, the governor rescinded this decision and will not attempt to eliminate the Dental Board. That he even thought to do so makes one ponder the implications of such an action and raises the question of the necessity for the board. Are dental health professionals needed to regulate dentistry? Let us be contemplative in the consideration of these issues.

At first blush, the reaction might be one of muted elation by some members of our profession. To be sure, through the years, the board has had a difficult time in fulfilling some of its legislated functions and many of us have been, at a minimum, frustrated with the concept of the board regulating dentistry in California. For that group, the elimination of this body could be seen as a blessing.

A word of caution might be in order. To assess the impact of this potential abolition of the Dental Board, one must consider the functions it serves or is intended to serve. It is purported that these responsibilities would have been transferred to the Department of Consumer Affairs for administrative (read: bureaucratic) performance of the tasks being executed by the present board, such as happened with the Environmental Protection Agency and Department of Health Services.

The most obvious function, and one in which all of us have been involved, is the

testing of dental health professionals for licensure. It is clear the state already has begun to ease the requirements for licensure through the completion of an examination developed by the Dental Board of California. The passage of legislation that allows participation in the Western Regional Board with acceptance in California has (or will) minimize the need for test development and administration by our present board. Couple this with the licensure-by-credential regulations that are in-place as well as the CDA proposal to enact a PGY-I model, and it is easy to see that the need for examination development and administration should be decreasing. Contracting the examination to other agencies could be accomplished quite easily by administrators.

If one considers the legislative mandate that the overriding responsibility of the board is to protect the public, not the betterment of dental health professionals, then enforcement becomes the *sine qua non* of their existence. In prior years, there was a significant backlog of enforcement cases, only recently resolved by a hard-working board staff. Enforcement will continue to be problematic, and adequate resources need to be allocated for this important function. Lack of sufficient numbers of investigators, poor funding, organizational hoops, and an overabundant agenda for high-level tasks impacts the board in fulfilling this mission. One would hope that consumer complaints would be judiciously resolved in a timely manner. Enforcement activities such as policing of licensees could be overseen by an administrative body, but it is imperative that one must not eliminate professional input into decision



Are dental health professionals needed to regulate dentistry? Let us be contemplative in the consideration of these issues.

We must hope that there will always be dental professional input into the decisions that affect our daily practice and the overall safety and quality of patient care.

making. To allow bureaucrats or administrative law judges to adjudicate malfeasance without educated input from doctors serves little purpose in protecting the public. It is extremely important that adequate dental health professional participation be obtained to set standards and make judgments as to inadequate or dangerous care.

The need to counsel and rehabilitate impaired dentists through diversion programs is a highly sensitive and specialized form of enforcement. This, too, could be administered by an agency with appropriately trained professionals that oversee this function for all health professionals — not only dentists. The ultimate decisions on enforcement for dental health professionals should be made in consultation with highly qualified dentists who pledge to serve the best interests of the public, but have an understanding of all aspects of practice.

The licensing of second offices, issuing of fictitious name permits, verification of continuing education, issuing of anesthesia and sedation permits, and many other administrative functions could be done by nonprofessionals or contracted out to communities of interest. There will be occasions when the professional advice is essential, and this could be sought from a series of consultants.

Another area of responsibility for the board is in the development, recommendation and enforcement of policy and regulation affecting dental care. This should imply that the board could be proactive in these areas and support rational regulations through the Legislature and oversee implementation. More realistically, the Legislature develops regulations and laws, and then transmits them to the board for enactment. While policy development would be a reasonable function for the board, very little of this has transpired in recent years.

It is not tenable that all functions of the board could become purely administrative and overseen by nonprofessionals. We must hope that there will always be dental professional input into the decisions that affect our daily practice and the overall safety and quality of patient care. Dentists who serve as consultants to the board or any entity that ensures the quality of dental care in California should be qualified and appointed not as a result of their political contributions or connections, but rather on their education, experience, and merit. Diversity, practice style, locations, and years of experience should be considered as well; one would expect nothing less to maintain the highest standards of care in our state.

While some of us are not comfortable with the current structure of the Dental Board of California, eliminating it for inappropriate reasons is hardly the best course of action. This might be an excellent application of the adage about not throwing out the baby with the bath water. Is the board perfect as it functions today? Probably not. Could the process be improved? By all means. The governor, the Legislature and the administration need to take care not to eliminate the ability to ensure quality of care in our state. The elimination of all 88 boards and commissions may save the state a few million dollars, which hardly makes the effort worthwhile from a fiscal standpoint.

Government should consider and make changes carefully, and recognize the functions that are critical to patient safety and good clinical practice *must* be overseen by dental health professionals and not lay personnel. Do not make it more difficult for dentists to have input in the regulatory and administrative processes that affect the dental health of the people of California. Change for its own sake is not the best thing. **CDA**

Saving the Teeth

What is that new paradigm? In a few words, saving teeth may not be the best thing for our patients.



I felt it necessary to comment on Dr. Cho's article in the December 2004 *Journal of the California Dental Association*.

In his review, "Evidence-Based Approach for Treatment Planning Options for the Extensively Damaged Dentition," Dr. Cho discusses current modalities for saving and or replacing diseased natural teeth. He spends most of his time reviewing fixed partial dentures, endodontic treatment, root resections/hemisections, and other ways of saving teeth. At the end of the article, he makes a case for the implant alternative. While I applaud the general thrust of the article, I feel he understates his prime point: Implants are changing the way we save teeth in dentistry.

The reality is that implant therapy is introducing a new paradigm that is going to have some major impacts on at least two major specialties in dentistry: endodontics and periodontics. What is that new paradigm? In a few words, saving teeth may not be the best thing for our patients.

This represents a major philosophical change that is hard, even for implant dentists, to embrace. Dr. Cho inadvertently illustrates this with a radiograph (Figure 4, Page 985. Here, the picture shows the lower left quadrant of a patient who originally had a four-unit bridge from Nos. 18 to 21. The bridge evidently failed for some reason, but the abutments were salvageable as individual crowns (Nos. 21 and 18), and implant/crown combos were placed at the Nos. 19 and 20 sites. All well and good. But the picture shows the No. 21 was now failing (previous endo/post, and now vertical root fracture). This is the classic error in "save the teeth" mentality. Had the treating dentist been aggressive enough with the new paradigm, he or she would have removed No. 21 at the time of the initial bridge failure, placed implants in the Nos. 21 and 19 sites only, and placed a three-unit, implant-

supported bridge, saving the patient the cost of the No. 20 fixture. (Certainly, the placement of No. 20 implant gives the patient the ultimate in 1:1 tooth replacement, eliminating the need to thread floss under the bridge, but with a price.) This is the part of the new paradigm that's hard for us die-hard "save the teeth" dentists to swallow. I know, I struggle with this everyday.

Perhaps the first, real penetration of the new paradigm will be experienced with bicuspid teeth, especially those with small, slender roots.

A patient presents with an MO, DO, MOD, or maybe even an occlusal amalgam on tooth No. 5. The amalgam is 15 years old, the tooth is sensitive to percussion and biting pressure. You make the diagnosis of an incomplete crown fracture, and discuss the need for endodontic treatment, maybe a post, and certainly a crown. In the new paradigm, you discuss extracting the tooth, placing an implant at the same appointment, and placing a crown in two months or so, depending on the surface of the implant. The cost is several hundred dollars more than the "traditional" treatment (about \$600 in our office), but the long-term success is vastly different. With the traditional treatment, everything is "successful" for awhile. My observation shows an average life of the above of maybe seven years. Then a post lets go. Or a root splits. Or the patient gets some recurrent decay. And the \$1,500-\$2,000 the patient spent on the tooth is down the drain. With the implant, we have a 95 percent success during the first six months, and a bit higher than that if the implant makes it past the first six months. No chance ever of recurrent decay, and the implant is mostly impervious to periodontal disease.

This new paradigm has some consequences for the endodontist. He or she's out of the equation completely. If you apply the

Continued on Page 274

Continued from Page 272

new paradigm to moderately periodontally involved teeth, you extract teeth that would otherwise need regenerative periodontal surgery, stopping bone loss with the placement of the implant. And the periodontist gets cut out of that equation (unless he or she is placing implants).

Will we cease to use endodontics? No, but we will use the modality less. Will we cease using the traditional services of the periodontist? No, but we will use them less. Heroic regeneration/membrane procedures will be limited to critical abutment teeth of multi-unit FPDs, where the cost of saving the tooth significantly outweighs the cost of replacing the FPD. How many of those situations do you run into in a year? Not many.

This new way of thinking is radical and it's hard to accept. But implants are vastly more reliable than most of what we've done in the past. Dr. Cho gives us an introduction to the change, but the total impact of the new paradigm is actually tsunami-like in nature.

Guy G. Giacomuzzi, DDS
Cedar Glen, Calif.

Licensure Process Needs Live Patients

We read with great interest your editorial in the January *CDA Journal*. We digested all the information on licensure from the House of Delegates, read numerous licensure-based literature, and discussed the subject matter with a great many dentists in practice and academia. What this all boils down to is a simple question: Can minimum clinical competence be determined without using live patients? We don't think so. Knowing what to do and being able to do it are two entirely different things. How is the elim-

ination of live patient exams going to objectively prove the graduates possess minimum clinical skills? We feel there must be objective third-party oversight of dental education. How can licensure by graduation or any examination model that does not test minimum clinical skills by an objective third party be valid and reliable? Even researchers who oppose a one-shot State Board Examination are not opposed to live patient examination if such examinations can be designed to be valid and reliable.

We agree that anyone completing a one-year approved internship, as is required in medicine or completing a residency in an approved postgraduate program, should not have to take our board exam. We do not agree, based on our experience and conversations with our medical colleagues, that dental students are any more qualified to treat patients after graduation than medical students.

Regarding dental students: Is it the dental students or the deans pushing for all these changes?

Maybe the current exam is not valid and reliable. Maybe we need a dental internship or some other means of evaluation, objective third-party evaluation of the clinical skills of the graduates. But we firmly believe that evaluation, however it is structured, should include live patients.

You write "the quality of our schools, and our graduates in general, mandate that alternative means of licensing can be considered." Does this mean the recent decline in passing percent on the State Board Examination is related to the quality of the graduates being graduated? Does this mean that because of this decline, the board examination must be made even less challenging by eliminating clinical

testing? Does this mean that CDA is not willing to work with the State Board of Dental Examiners to make the exam more valid and reliable? What do you mean?

Robert E. Reed, DDS
Bakersfield, Calif.

Robert G. Tupac, DDS
Bakersfield, Calif.

Revamp the Licensure Process

Your editorial in the January 2005 *CDA Journal* was right on target. Our profession has lagged behind our medical colleagues for too long in licensure. I originally came to California via the Navy and had to jump through all the hoops to get my dental license even though I had completed a general practice residency and was licensed in another state. This was 10 years ago, and our system is still antiquated even though we have allowed reciprocity and credentialing. I feel that the State of New York has thrown down a challenge to all the other states with their licensure protocol. California, who trains a great many more dentists every year than any other state, should be the next state to revamp the old licensure process.

Let us be a leader in this trend toward national licensure and not continue to be considered stuck in the old way of thinking by other states. I am proud to be a member of the California Dental Association and hope that the rest of the country will look to us to continue the push to bring dental licensure in the 21st century the way medicine has already done.

I want to thank you for bringing this topic to the forefront as I believe most of the dentists in our state feel the same way about licensure.

Kurt Stormberg, DDS, MS
La Mesa, Calif.



Illustration: Lee Ann Engle

Dental Education Under Review



With the surgeon general designating dental disease as a “silent epidemic” and nationwide oral health care access issues, a group of 60 leaders in dentistry and other health care professions met to examine an emerging crisis in American dental education, and to plan strategies for major reforms.

Salon participants included dental school deans such as Harold Slavkin, DDS, of the University of Southern California School of Dentistry; the president of the ADA; the assistant U.S. surgeon general; the country’s chief dental officer, as well as numerous representatives ranging from dental practitioners to officers of public policy organizations. The objective of the

“Dentistry must get students more engaged in communities where they are needed, and our students need to become more representative of the populations they serve.”

LARRY MESKIN, DDS, MSD, MPH, PHD


salon, which met in late 2004 at the University of the Pacific Arthur A. Dugoni School of Dentistry, was to create a system that produces a new type of oral health professional.

The leaders said they believe a closer integration with medical training is essential, noting that society’s needs have changed. Among the factors are aging and associated chronic diseases, increasing disparities in health and access to care, and immigration. Participants also said that graduates of U.S. dental schools must change to reflect these new realities.

The surgeon general’s report documented that oral and systemic problems often are associated, and oral disorders and diseases can compromise one’s health and well-being over a lifetime. The report also concluded that solutions are hindered by issues involving oral health disparities, the erosion of the dental work force, barriers to care for growing segments of the population, and the relative inability of the public to benefit from scientific advances. While dental schools are in a position to attack these problems, the participants said the current dental education system is threatened by escalating costs of education, mounting student indebtedness, among other things.

“Because dental schools are not providing the kind of education modern practitioners need to function competently in today’s biologically, pharmacologically, and technologically driven health care environment, the dental delivery system cannot keep pace with, nor be responsive to shifting population demographics, changing patient expectations, evolving interdisciplinary practice requirements, emerging technologies and demands for quality improvement,” said Dominick P. DePaola, DDS, PhD, president and CEO of the Forsyth Institute.

Participants said the single most important factor responsible for the crisis in American dental education is the “silo” approach that traditionally has been the hall-



mark of the curriculum. In opting for an isolated, insular approach to training future dentists instead of for integration of dentistry within a comprehensive interdisciplinary health care education and training system, dental schools have created a gap between advances and incorporation into dental education and clinical practice.

Slavkin noted that while the salon is the first step in what is planned as a broad-based national effort to overhaul dental education in the United States, certain imperatives already have emerged. For example, there was consensus that status quo in dental education and practice no longer is desirable or acceptable; that dentists should be leaders in the health care community; that thought leaders in dentistry need to be developed; that collaboration among the health professions is more important than ever; and that a mechanism is required to make the credentialing process, including a National Dental Board Examination, more relevant to technological and scientific advances, and to society’s expectations and needs.

“The fact that 80 percent of dental disease occurs in 20 percent of the population, that 110 million Americans lack dental insurance, and that there is a growing shortage of dentists to treat the needs of certain populations — especially children — obligates us to move quickly toward reform,” Slavkin said.

Larry Meskin, DDS, MSD, MPH, PhD, president of the Santa Fe Group, a nonprofit, nonpartisan organization that seeks to

advance the shape the future of health care, said "Meeting the challenges facing dental education and embracing the astonishing advances in genomics, proteomics, pharmacotherapy, and systems biology will require not simply a change in curriculum, but a reform of the entire dental education process, including changes in prerequisites, admissions, credentialing, and quality assurance. Dentistry must get students more engaged in communities where they are needed, and our students need to become more representative of the populations they serve."

A "revolution from within, our objective is to act as a catalyst to influence change by providing a forum in which health care professionals, policy leaders, and decision makers from multidisciplinary backgrounds can come together in a

neutral environment to share opinions freely, without institutional constraints," Meskin said. He added that the timing is right for reform since the first surgeon general's report on the country's oral health, published in 2000, highlighted the growing crisis and provided a social rationale for taking action.

Dushanka V. Kleinman, DDS, MScD, chief dental officer for the U.S. Public Health Service, emphasized the need for the conference. "It is good that thought leaders are beginning to consider the reformation of dental education, because there is much that the dental profession must accomplish in the coming years."

The salon ended with a series of recommendations for strategic actions which dental schools, governmental agencies, for example, could implement.



Dental X-rays Can Identify Osteoporosis in Women

A study published in the *American Journal of Roentgenology* last December shows that panoramic dental radiographs may be utilized to identify post-

menopausal women with low skeletal bone mineral density.

That means screening for spinal osteoporosis could begin in the dentist's office, said Akira Taguchi, DDS, PhD, Department of Oral and Maxillofacial radiology at Hiroshima University Hospital in Japan, and one of the study's authors.

Dental X-rays, by showing the width of the jaw and cortical shape, can be a good indicator for additional bone mineral density testing, Taguchi said, noting that the best way to determine whether a patient has spinal osteoporosis is through standard questionnaires.

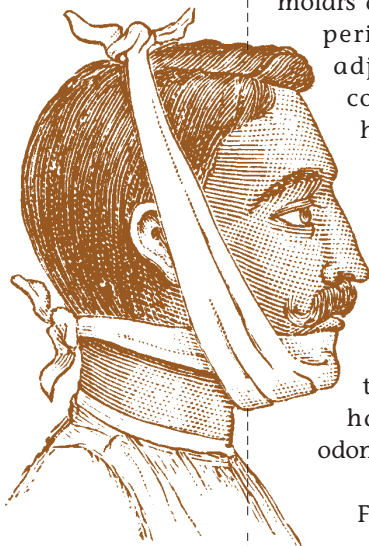The study is available in full and for free at the American Roentgen Ray Society's website, www.ajronline.org/cgi/content/full/183/6/1755.

Nominations Accepted

New York University College of Dentistry is accepting nominations for the 2005 Irwin Smigel Prize in esthetic dentistry. The award recognizes Smigel's pioneering achievements in the field as well as others' significant contributions to esthetic dentistry.

The honor, which includes a \$5,000 stipend and an award designed by Calvin Klein, will be presented at a future symposium sponsored by the university's Continuing Dental Education Program. The first recipient of the award was Ronald E. Goldstein, DDS, followed by K. William "Buddy" Mopper, DDS.

Nominations, support letters, and a curriculum vitae must be sent by May 1 to the Smigel Prize Committee, NYU College of Dentistry, 345 E. 24th St., New York, N.Y., 10010, attn: Kendall Beacham, assistant dean. Submissions also may be sent via e-mail to: kendall.beacham@nyu.edu.



Study Shows Negative Impact of Third Molars

People over the age of 52 with visible third molars are 1.5 times more likely to suffer periodontal disease in the area adjacent to the second molar compared to similar adults who have had their third molars removed.

An ongoing study, sponsored by the American Association of Oral and Maxillofacial Surgeons and the Oral and Maxillofacial Surgery Foundation, appeared to confirm previous research that the presence of third molars may have a negative impact on periodontal health well later into one's life.

The study, published in the February issue of the *Journal of Oral and Maxillofacial Surgery*, looked at more than 6,700 adults between the ages of 52 and 74 from North Carolina, Maryland and Minnesota. They were participants in the Dental Arteriosclerosis Risk in Communities substudy. Of the group, 30 percent retained one or more third molars.

Researchers from the University of North Carolina Chapel Hill School of Dentistry

measured the periodontal probing depth surrounding the existing third molar to determine whether periodontal disease was present. A probing depth of 5 mm or greater with 2 mm or more attachment loss on the distal of a second molar or around the adjacent third molar was a determining factor for periodontal disease. The team also considered the presence of gingival bleeding on the adjacent second molar, as compared to those patients without a visible third molar.

Of the patients, third molars were not present in 4,758 or 30 percent of the patients. Of the 30 percent with at least one visible third molar, probing depths of 5 mm or greater were likely to occur 1.5 times more than in the control group whose third molars had been removed. A correlation was found in the area of gingival bleed on the adjacent second molar, where patients with at least one visible third molar were 1.3 times more apt to be affected than those in the control group.

Researchers said their findings lend credence to the ongoing negative impact of visible third molars on periodontal health, and the issue should be studied further.

Brushing Devotees Are Healthier, Slimmer

Frequent toothbrushing may keep fat at bay.

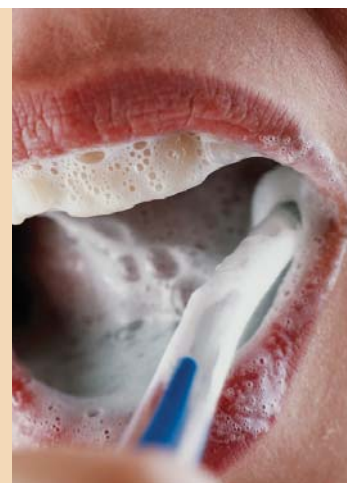According to a recent survey of the daily habits of nearly 14,000 people in their mid-40s, researchers found that those who brushed their teeth after every meal managed to be slimmer than those who didn't.

Overweight men sometimes went more than a day without brushing their teeth, according to Takashi Wada, whose study was published in the *Journal of the Japan Society for the Study of Obesity*.

Wada, director of the Health and Medical Science Center at Jikei University School of Medicine, and his team compared the lifestyles of people whose body mass exceeded 25, the level doctors define as overweight, with the habits of their slimmer counterparts. The survey included the habits for eating, drinking, sleeping, working, and exercising.

"It's a sign that these people are careful about their health," the study said about the frequent brushers. "They want to maintain the appearance of their teeth and prevent bad breath. We think actively encouraging the habit of toothbrushing would play a role in maintaining health and would help prevent obesity."

The authors noted the results do not mean that brushing in itself constitutes a fat-burning exercise.



New Treatment for Gum Disease

A new procedure utilizing lasers can now replace scalpels as a method of treating periodontal disease, which affects more than 50 percent of adults.

In the fall 2004 issue of *General Dentistry*, the Academy of General Dentistry's peer-reviewed journal, a laser-assisted new attachment procedure offers a scalpel-free way for treating diseased gums. The procedure works by using the lasers to zap diseased tissue. The lasers only seek out their target, leaving healthy gum tissue behind. The lasers are used again to heat the area until a clot is created to protect the gum tissue wound by keeping it closed. Once the clot heals, new tissue is left behind.

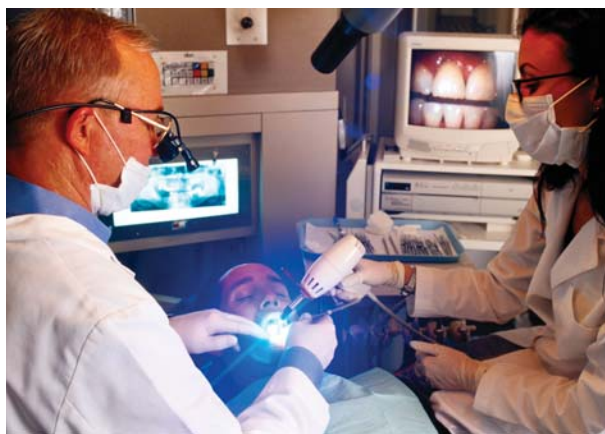"This is the first ever stand-alone procedure for the laser to replace surgical methods," said Robert H. Gregg, DDS, co-

author of the study.

"The data shows you can treat periodontal disease without using sutures or amputating the gums."

Gregg said that although stitches are not needed with the new procedure and may result in fewer follow-up trips for care, patients still must receive a local anesthetic.

"These findings are very interesting," said Eugene Antenucci, DDS, and spokesman for the Academy of General Dentistry. "Lasers have been proven to be extremely effective for many purposes in the dental office. As additional research is done on this procedure and similar procedures, we'll learn more about how lasers can improve periodontal health."





Cafeteria Bandit Leaves Toothy Proof

There was no need for Swedish police to take a bite out of crime, the suspect did it himself.

A man who broke into a cafeteria in southern Sweden left compelling and incriminating evidence of his visit: his false teeth, which also included his Social Security number. Police simply used dental records to identify the man.

After being presented with the evidence, the 43-year-old man admitted to breaking into a hospital cafeteria in Karlshamm, about 370 miles south of Stockholm. He told police he left the cafeteria after not finding anything valuable. He dropped his teeth while fleeing the building.

Correction

The article "Enhanced Periodontal Debridement with the Use of Micro Ultrasonic, Periodontal Endoscopy," by John Y. Kwan, DDS, in the March 2005 issue contained a few errors.

Figure 2 should read: Screw-in tips (not recyclable)

Figure 8 was not labeled accurately, and one of the photos was incorrectly printed in the *Journal*. The correct legend for Figure 8 is: (top) scaler, probe and micro ultrasonic insert, (bottom) angled insert, modified curved/angled insert, and furcation probe.

The legend for Figure 13a is: Patient No. 2 before treatment, and Figure 13b: Patient No. 2, 14 months after treatment.

The legend for Figure 15a is: Patient No. 3 before treatment, and Figure 15b: Patient No. 3, 18 months after treatment. Additionally, below is the correct image for Figure 15b.

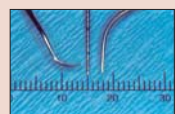


Figure 8 (top).



Figure 8 (bottom).



Figure 15b.

Upcoming Meetings 2005

April 6-9	Academy of Laser Dentistry 12th Annual Conference and Exhibition, New Orleans, (954) 346-3776.
April 12-16	International Dental Show, Cologne, Germany, www.koelnmesse.de
May 12-15	CDA Spring Session, Anaheim, (866) CDA-MEMBER (232-6362).
Aug. 17-20	Sixth Annual World Congress of Minimally Invasive Dentistry, San Diego, (800) 973-8003.
Sept. 9-11	CDA Fall Session, San Francisco, (866) CDA-MEMBER (232-6362).
Oct. 6-9	ADA Annual Session, Philadelphia, (312) 440-2500.
Dec. 3-6	International Workshop of the International Cleft Lip and Palate Foundation, Chennai, India, (91) 44-24331696

2006

April 27-30	CDA Spring Session, Anaheim, (866) CDA-MEMBER (232-6362).
Sept. 15-17	CDA Fall Session, San Francisco, (866) CDA-MEMBER (232-6362).
Oct. 16-19	ADA Annual Session, Las Vegas, (312) 440-2500.

To have an event included on this list of nonprofit association meetings, please send the information to Upcoming Meetings, *CDA Journal*, P.O. Box 13749, Sacramento, CA 95853 or fax the information to (916) 554-5962.



Treatment Planning in Implant Dentistry

SAJID A. JIVRAJ, DDS, MSED

The clinical replacement of lost natural teeth by osseointegrated implants has represented one of the most significant advances in restorative dentistry. Two decades ago, a vocal majority of dentists were skeptical about implants and rejected them entirely. Today, it is rare to find a practitioner who does not work with dental implants or who is not actively participating in one of the many seminars or courses offered by universities, professional societies and implant manufacturers.¹

Compared to all other dental disciplines, implant dentistry has enjoyed far more innovation and progressive development in recent years. Included in this regard are the developments of new implant systems, the propagation of new and improved diagnostic procedures, the introduction of novel surgical techniques, quantum leaps forward in prosthodontic precision of fit, as well as exploitation of state-of-the-art industrial technologies such as CAD/CAM.

Today's patients have high expectations regarding esthetics and providing functional and comfortable restorations alone may not be sufficient to satisfy many of them.² With heightened esthetic expectations, it becomes imperative the restorative dentist understand the

patient's desires and expectations prior to embarking upon any irreversible therapy. Moreover, emphasis should be placed on diagnosis and treatment planning because in most situations, the proper diagnosis will dictate the appropriate treatment plan. Inadequately planned treatment, even when well executed, will result in less than ideal treatment.

Esthetics is one of the main reasons why restorative dentists embrace implant technology. Naturally, many implant manufacturers attempt to identify their systems as esthetic. From an objective viewpoint, implant parts, in of themselves, are not esthetic. There is not a single implant component that is the perfect esthetic replacement for a central incisor.³ Esthetic outcomes are dependent on many variables, including initial site integrity, preoperative assessment, the success of augmentation procedures, the artistry of the dental technician and finally, components. It is not the specific implant design, surface characteristics or type of abutment that will guarantee an esthetic result. It is, rather, the time spent on data collection in reaching a correct diagnosis that pays dividends in terms of function and esthetics.

Diagnosis and treatment planning must have a proven scientific basis if consistency of results is to be achieved. Without science as our guiding light, any implant success is limited to initial

gratification and ignores the far greater elements of a problematic outcome yet to occur.⁴ As practicing clinicians, we must critically evaluate clinical procedures and seek reliable data to substantiate their use. The importance of long-term follow up cannot be overemphasized. Strong evidence comes from prospective, randomized double-blinded clinical trials. Retrospective case studies and case reports, while possibly suggesting certain trends, are still open to question and should not be relied upon as the "benchmark," upon which to make clinical decisions.⁵

The replacement of missing teeth with dental implants remains a difficult task under most conditions. With comprehensive treatment planning and proper surgical and restorative protocols, satisfactory results can be achieved. The articles in this issue have been assembled to address diagnosis and treatment planning considerations as the cornerstone to success in implant dentistry.

In the first article, Paolo Corrado, MD, DDS, Winston W.L. Chee, DDS, and I outline the blueprint for a com-



Guest Editor / Sajid A. Jivraj, DDS, MSED, is chairman of the Section of Fixed Prosthodontics and Operative Dentistry at the University of Southern California School of Dentistry. He also maintains a private practice limited to prosthodontics in Burbank, Calif.



prehensive interdisciplinary treatment philosophy designed for developing the foundation for optimal esthetics in implant dentistry. William Becker, DDS, MSD, will look at the evidence behind immediate implant placement and the role it plays in hard and soft tissue preservation. Dr. Chee discusses treatment planning parameters for implant-supported partial overdentures. Some cases will be presented.

Nikitas Mordohai, DDS, and Mamaly Reshad, DDS, MSc, will critically evaluate the literature and give guidelines as to when a tooth should be kept or extracted in favor of an implant replacement. Clark Stanford, DDS, PhD, explores the evidence behind implant

occlusion and decipher what we know, what we don't know, and what we still need to know. Lastly, Krikor Derbabian, DDS, and Krikor Simonian, DDS will address the subject of immediate loading and discuss the factors that need to be considered in order to optimize both surgical and prosthodontic success.

Although new components offering improved esthetic potential are constantly being introduced by different manufacturers, it is the process of pre-operative evaluation and diagnosis which determines the esthetic and functional outcome. We live in an age where technology continues to improve. However, in spite of these technical improvements, a diagnostic perspective

is still required for long-term success.

My intention with this issue is to look at the thought process behind treatment planning in implant dentistry. I sincerely hope the articles in this issue inspire readers to seek further knowledge in this ever-developing field. **CDA**

References / 1. Spiekerman H, Color atlas of dental medicine. Thieme Medical Publishers, Inc. Implantology: 5-6, 1995.

2. Derbabian K, Esthetics: A fundamental component of prosthodontics. *Calif Dental Assoc J* 31(7):535, July 2003.

3. Sullivan RM, Perspective on esthetics in implant dentistry. *Compend Contin Educ Dent* 22(8): 685-92, August 2001.

4. Nowzari H, Aesthetic periodontal therapy: Introduction. *J Periodontol* 27:7, 2000.

5. Laskin DM, Learning to read it right. *Int J Oral Maxillofac Implants* 17(6): 767, 2002.



An Interdisciplinary Approach to Treatment Planning in Implant Dentistry

SAJID A. JIVRAJ, DDS, MSED; PAOLO CORRADO, MD, DDS;
AND WINSTON W.L. CHEE, DDS

ABSTRACT

The practice of implant dentistry requires an interdisciplinary approach that integrates the knowledge, skills, and experience of all the disciplines of dentistry into a comprehensive treatment plan. The team must examine the anticipated restorative site to determine the suitability of the existing hard and soft tissues for implant placement. Deficiencies in hard and soft tissue, which prevent ideal implant placement, must be recognized and addressed to ensure a more predictable esthetic outcome. This article outlines a comprehensive interdisciplinary treatment philosophy designed for developing the foundation of optimal esthetics in implant dentistry. Cases are presented to illustrate the utility of interdisciplinary treatment in which specialists are recruited to enhance and improve a patient's dental function and esthetics.

Esthetics is an inseparable part of today's dental treatment. However, the consistency of the results, reliability of treatment modalities, and long-term prognosis require scientific approaches to therapeutic procedures.¹ In recent years, implant dentistry has been increasingly influenced by esthetic considerations.² The primary reason for this is the



Guest Editor / Sajid A. Jivraj, DDS, MSED, is chairman of the Section of Fixed Prosthodontics and Operative Dentistry at the University of Southern California School of Dentistry.



Authors / Paolo Corrado, MD, DDS (not pictured), is in private practice in Verona, Italy.

Winston W.L. Chee, DDS, is the Ralph and Jean Bleak Professor of Restorative Dentistry director of implant dentistry at the University of Southern California School of Dentistry.

Acknowledgements / The authors would like to thank M. Rostello and D. Lanzarotto of Verona Italy, for the technical assistance and David Hochwald, DDS, for the implant placement in Case No. 1; Hessam Nowzari, DDS, PhD, and Daniel Teboul, DDS, for the implant placement in Case No. 2; and Alessandro Arciadacono for the technical work in Case No. 2.



patient's demand for naturally appearing restorations.

With the elevated expectations of patients and increased experience and knowledge of clinicians, there is no doubt an interdisciplinary approach that integrates the knowledge, skills, and experience of all the disciplines of dentistry into a comprehensive treatment plan can yield better results.

Diagnosis and treatment planning must have a proven scientific basis for long-term success. Diagnosis is a prerequisite to successful interdisciplinary therapy.

The goal of modern implant dentistry is no longer represented solely by successful osseointegration. In order to claim success, the definitive restorations must be surrounded by a soft and hard tissue environment in harmony with the existing dentition.³ Talented ceramists can fabricate restorations that mimic the adjacent teeth. However, if reconstruction of the surrounding tissue is not realized, the result will not be esthetically pleasing. It remains the responsibility of the implant team to consider all the variables that can influence the final outcome prior to embarking upon treatment.⁴

Well-executed, implant-supported restorations can offer exceptional satisfaction to both the patient and dentist. It can transform an unhealthy, unat-

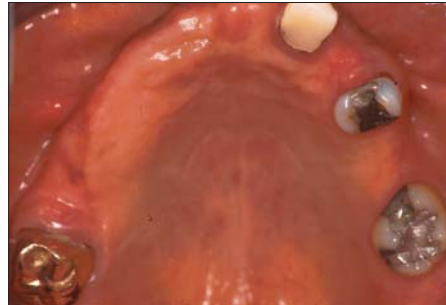

Figure 1. Maxillary occlusal view.

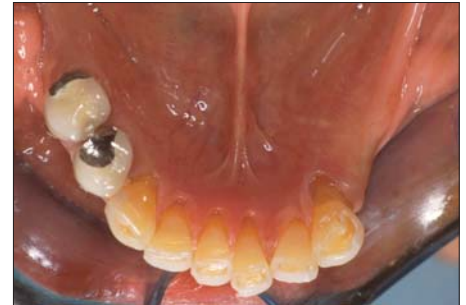

Figure 2. Mandibular occlusal view.

tractive dentition to one that is esthetically pleasing to the patient. In addition, implant-supported restorations can improve comfort and function. The longevity of implants is well documented, and in many situations where posterior support is lacking, implant-supported restorations are the only method of predictably providing this support for occlusion in the long term.⁵

To obtain optimal results, attention must be paid to a myriad of details. The process starts with the patient interview and assessment. Meticulous treatment planning and precision in active treatment will lead to a more predictable result.

The objectives are to improve oral health, establish proper occlusal function, and to create the most ideal esthetic result possible. Diagnoses are made based on data collected, problem lists

and the patient's chief complaint. It is only through an organized and systematic approach that appropriate diagnoses can be made. Additionally, based on these diagnoses, functional and esthetic problems can be addressed predictably.

The delivery of a successful esthetic-oriented treatment plan requires the coordination of many practitioners who need to have similar treatment philosophies. It is imperative the team leader appropriately selects a team of practitioners. The selection process can either have a positive or a negative impact on the overall treatment. Each provider on the team must have an optimal level of skill in his or her area of expertise to be a positive factor.⁶

The complex nature of interdisciplinary therapy necessitates a highly organized method of communication between the team members so that all

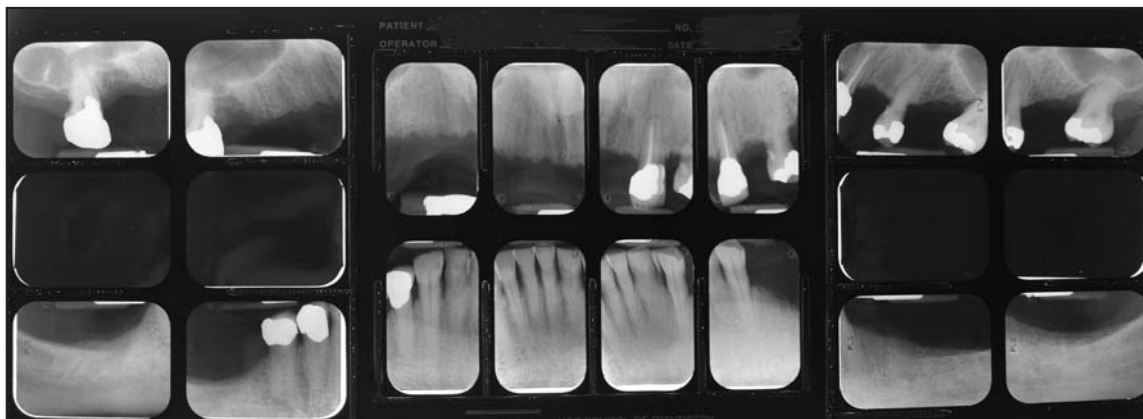

Figure 3. Radiographic full-mouth series.

aspects of treatment can be equally voiced. It is through this communication an interdisciplinary treatment plan can be formulated prior to generation of a joint treatment letter. This letter should include a discussion of the treatment provided by each team member, the time frame of the proposed treatment, the inherent risks involved, treatment alternatives, informed consent, and the financial responsibilities of the patient. It can be said that the quality of treatment is dependent upon the quality of the communication. It is critical the team leader maintains communication between the specialists both during treatment and once it has been completed. It is only through this approach that optimal care can be delivered and regular planned follow-up care can be implemented. The team leader in this respect should be the restorative dentist since he or she is responsible for the definitive appearance of the prostheses to be seated on the implant.

Following a preoperative evaluation, it is the restorative dentist who must define the ideal morphology of each element to ensure the prostheses blends seamlessly into the existing oral environment.⁷ Therapy must begin with a detailed clinical and radiographic evaluation. Mounted diagnostic casts are critical in all phases of prosthodontics and permits discussion of proposed treatment between team members. Diagnostic casts allow analysis of the occlusion, assessment of edentulous ridge relationships, and evaluation of the position of natural abutments to calculate space requirements. Interarch space can be determined and the opposing dentition can be observed for any encroachment on the anticipated prosthetic space. The casts can be duplicated and used to fabricate a diagnostic wax up that can assist with implant site selection and angulation requirements during the

surgical phase of treatment. Most often, the diagnostic wax up is the blueprint from which a surgical guide is fabricated. This guide serves as a reference for the entire team. Every effort should be made to attain prosthetic contours that have proper intrinsic proportions, as well as proportions consistent with the adjacent teeth.

To achieve optimal esthetics, each phase of treatment must be well executed from the initial evaluation and the preparation of the implant recipient site, to the provisional phases prior to implant placement, through provisionalization following implant integration, and the fabrication of the definitive prostheses.

The following cases illustrate all of these considerations that have led to predictable esthetic treatment results.

Case No. 1

A 67-year-old woman was seeking replacement of her current removable partial denture with fixed restorations. Her specific complaint was the instability of the denture as well as the Class III tooth relationship of her mandibular anterior teeth (**Figures 1, 2**).

On clinical and radiographic examination, a diagnosis of lack of posterior support was made (**Figure 3**). There was also insufficient bone in the posterior

maxillary and mandibular areas for direct placement of implant-supported restorations.

The objectives of treatment included providing the patient with implant-supported restorations in both the maxilla and mandible, as well as orthodontically retracting the mandibular anterior teeth to provide for a more Class I horizontal and vertical tooth relationship.

When significant numbers of teeth are missing, the orthodontist is at a disadvantage because of lack of anchorage to effect the desired tooth movement. The literature has shown that dental implants can be used as anchors for both orthodontic and orthopedic movement.⁸⁻¹⁰ By utilizing an interdisciplinary approach, implants can be used to provide anchorage, and then restored as implant-supported restorations.

With these objectives in mind, a treatment plan was formulated that required communication between the surgeon, orthodontist, and prosthodontist.

The first stage was to complete a bilateral maxillary sinus lift with bone augmentation, as well as onlay grafting of the mandibular posterior sextants.

Implants are usually placed prior to the start of orthodontic treatment, which can be difficult since the post-orthodontic position of the teeth needs

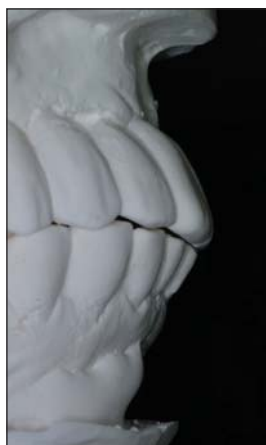

Figure 4.
Preorthodontic
-mounted diag-
nostic casts.



Figure 5.
Orthodontic
set up,
mandibular
anterior teeth
retracted. Note
amount of hor-
izontal overlap.



to be determined beforehand. An orthodontic set up was completed on the cast to determine the final position of the teeth (Figures 4, 5). Using this set up, a surgical template was fabricated to communicate the positioning of the implants to the surgeon (Figures 6, 7). The maxillary and mandibular implants were placed (Figures 8, 9).¹¹ The implant

in position of tooth No. 21 could not be ideally positioned due to the distal root inclination of tooth No. 22.

Once osseointegration had been established, provisional restorations fabricated from polymethylmethacrylate were placed on the implants (Figure 10). These restorations simplified the attachment of the orthodontic appli-

ance, restored occlusal function, improved esthetics, provided posterior vertical support, and served as blueprints for the definitive implant-borne restorations.¹²

Orthodontic brackets were attached directly to the provisional restorations using polymethylmethacrylate resin and orthodontic treatment was begun immediately. Using nickel titanium wires, a sustained orthodontic load was applied to effect lingual movement of teeth Nos. 22 to 26 (Figure 11). On completion of the orthodontic treatment, a second set of provisional restorations was fabricated since the vertical and horizontal relationships of the anterior teeth were now a more Class I relationship (Figures 12, 13). The existing provisional restorations facilitate the fabrication of the definitive prostheses in that they are the blueprint for the final design. These restorations were used to communicate esthetic and functional information to both the patient and laboratory technician for a predictable outcome (Figures 14-16).

Communication between the allied specialists is essential to achieve optimal results. Without adequate communication, the treatment provided will fall short of the desired results, regardless of the initial planning. A systematic planned and executed treatment protocol will meet the desired goals and inevitably will result in a satisfied patient.

Case No. 2

A 28-year-old woman presented with congenitally missing lateral incisors. These edentulous spaces had been restored previously with resin-bonded fixed partial dentures, which had not provided a successful outcome. The patient also felt the maxillary central incisors were narrow and requested a more dominant appearance (Figure 17).



Figure 6. Mandibular surgical guide.

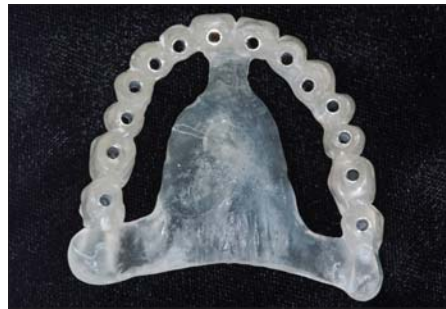

Figure 7. Maxillary surgical guide.

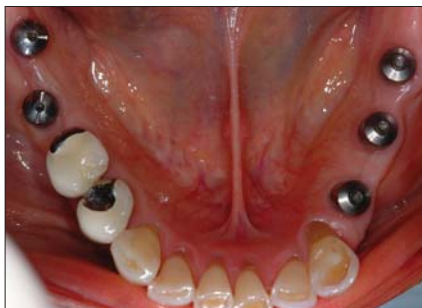

Figure 8. Mandibular implant placement. Note nonideal placement of implant in region of tooth No. 20 as a result of the distal inclination of the root of No. 22.

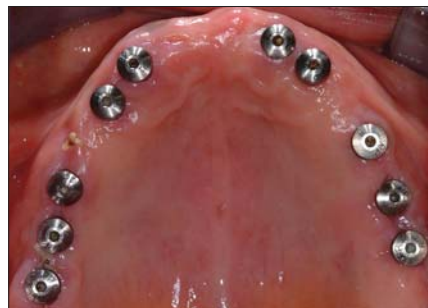

Figure 9. Maxillary implant placement.

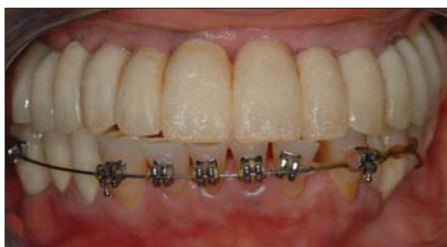

Figure 10. First set of provisional restorations on implants. Orthodontic brackets bonded to mandibular anterior teeth and implant provisional restorations in the posterior mandible.

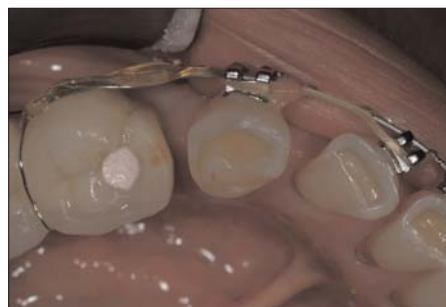

Figure 11. Retraction of mandibular anterior teeth, using implant provisionals as anchorage.

Clinical and radiographic examinations indicated a number of issues that could be corrected to improve the overall esthetics. These included relative tooth dimensions, prosthetic replacement of the lateral incisors, color and smile symmetry.¹³ To confirm the analysis matched the perceptions of the patient, a diagnostic wax pattern was

formed and an acrylic resin template of the wax pattern fabricated. This template served to communicate the desired result to the patient. Approval from the patient was sought and obtained. The treatment plan was formulated and put into action.

Radiographic examination revealed inadequate interradicular space for

placement of the implants without damaging the adjacent teeth. Computer-aided tomography revealed inadequate buccolingual osseous dimensions for insertion of implants (Figures 18, 19).

A treatment plan was formulated, which included communication between the orthodontist, surgeon and prosthodontist. The first phase of treatment included orthodontic therapy to provide sufficient interradicular place for placement of implants. The space for the prosthetic restorations was communicated to the orthodontists by means of a diagnostic wax up. The patient was informed that following orthodontic therapy, the incisal edges of teeth Nos. 8 and 9 would be irregular, and as a result, would require restoration (Figure 20).

Following orthodontic therapy, an

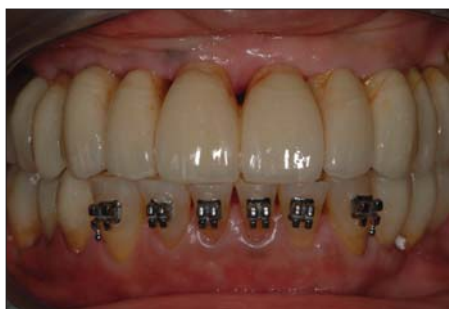

Figure 12. Second set of provisional restorations following orthodontic movement of mandibular anterior teeth.

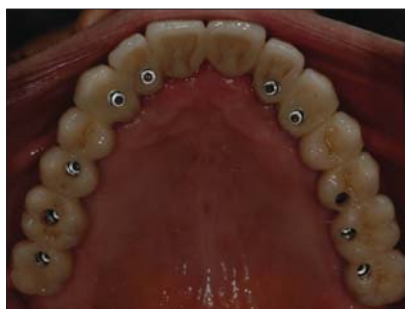

Figure 13. Maxillary occlusal of provisional restorations.

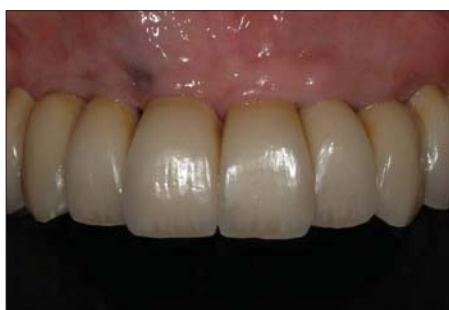

Figure 14. Definitive metal ceramic prostheses.

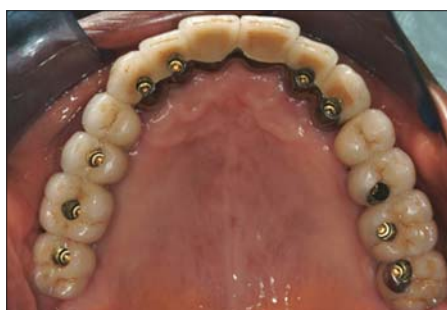

Figure 15. Maxillary occlusal of definitive restorations.

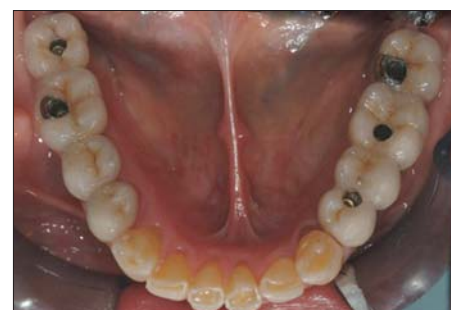

Figure 16. Mandibular occlusal of definitive restorations.

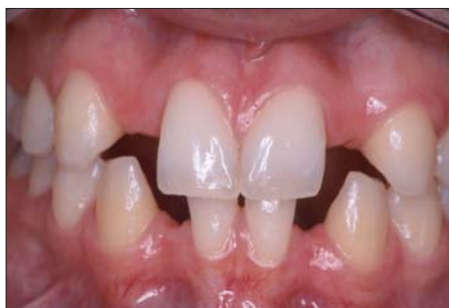

Figure 17. Preoperative condition. Patient presents with congenitally missing lateral incisors.

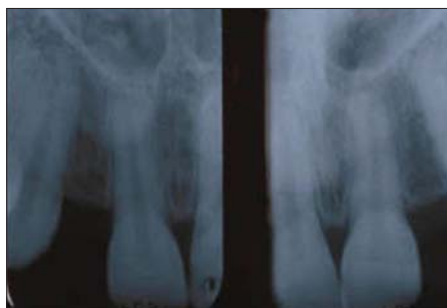

Figure 18. Periapical radiographs displaying inadequate interradicular space for implant placement.

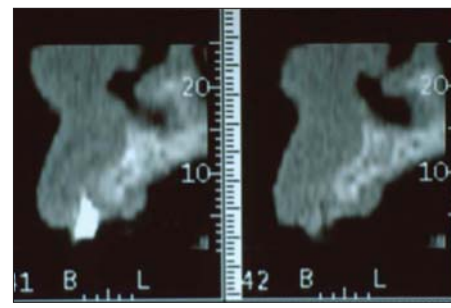


Figure 19. CT scan showing inadequate osseous volume faciolingually for implant placement.



autogenous bone graft was performed to restore the osseous volume in the regions of teeth Nos. 7 and 10. Bone was harvested from the mandibular symphysis, providing a cortical graft. Advantages of this type of transplant are a short healing period, maintenance of osseous density, intraoral access, proximity to the recipient site, low morbidity, and no cutaneous scarring (**Figure 21**).¹⁴

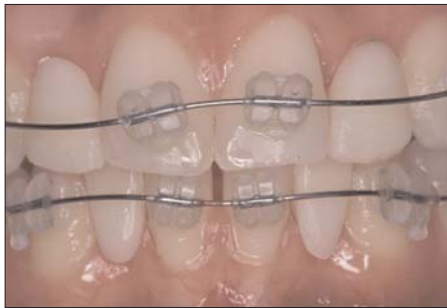


Figure 20. Orthodontic movement to create interradicular space for implant placement.

To attain the optimal morphology of the prosthetic restorations, accurate 3-D positioning of the implant fixtures is critical. A diagnostic wax up was completed and used to fabricate a surgical template, which served to communicate the implant position to the surgeon. The mesiodistal positioning of the implant required at least 1.5 mm of clearance from the adjacent teeth. This clearance was necessary to develop and maintain the integrity of the papilla.¹⁵ Faciolingually, the implants were placed for screw-retained restorations with the screw access holes emerging from the cingulum of the definitive restorations. Apicocoronally, the fixtures were placed 2 mm apical to the adjacent cemento-enamel junction. This allowed for the adequate transition from the cross section of the implant

to the natural contours of the replacement tooth. An implant level impression was obtained immediately after implant insertion (**Figure 22**). This impression was used to fabricate provisional restorations, which were delivered after uncovering the implant (at Stage II) to develop appropriate soft tissue contours (**Figure 23**).¹⁶

After preparation of Nos. 8 and 9 for porcelain-bonded restorations, the implant provisional restorations were used as impression copings and incorporated into the impression (**Figure 24**).¹⁷ A soft tissue cast was poured against the provisional restoration to provide a good replication of the soft tissue. Provisional restorations were provided for the patient and definitive restorations were fabricated (**Figures 25, 26**).

The definitive restorations satisfied the functional and esthetic goal of

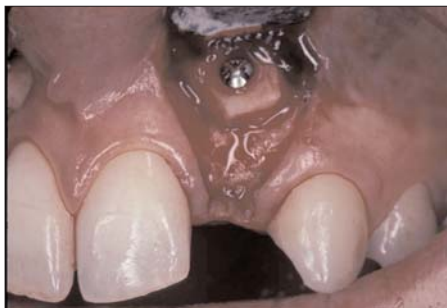

Figure 21. Autogenous bone transplant in region of No. 10.

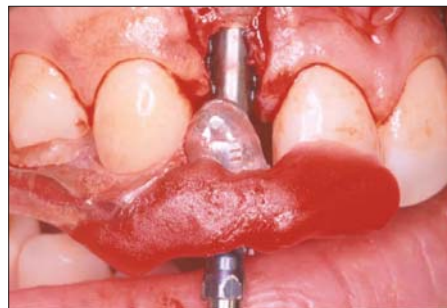

Figure 22. Fixture level impression with surgical template and resin.

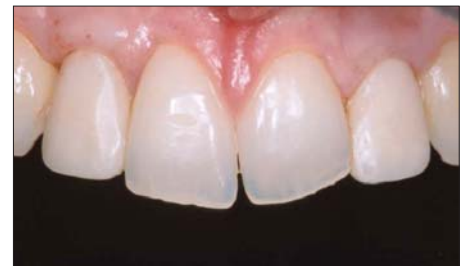

Figure 23. Provisional restorations on Nos. 7 and 10 two weeks following uncover.

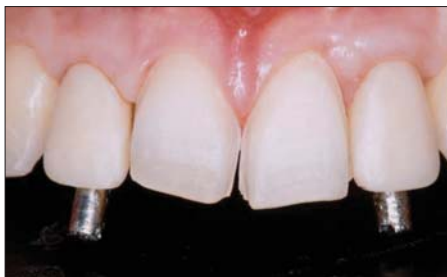

Figure 24. Provisional restorations on Nos. 7 and 10 used as impression copings.

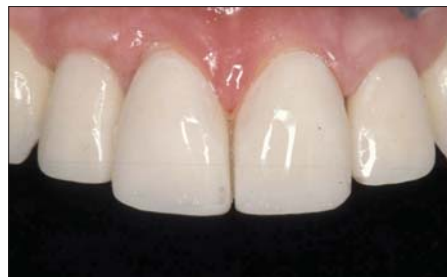

Figure 25. Implants and veneer preparations provisionalized.

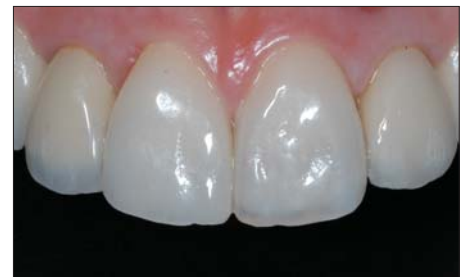

Figure 26. Definitive metal ceramic implant supported restorations on Nos. 7 and 10. Bonded porcelain restorations on Nos. 8 and 9.

treatment. This was a result of coordinated efforts between the surgeon, orthodontist, prosthodontist, and laboratory technician. Restoration of tooth position and optimal bone volume were essential to ensure that only minor adjustments were required at the time of implant placement. Careful observation of the chronology of treatment stages and constant communication between the allied specialists ensured an optimal esthetic and functional outcome.

Summary

This article illustrated the advantages of an interdisciplinary approach to the management of patients who

require complex treatment utilizing implants. Treatment planning must begin through a visualization of the end result. By paying attention to details, systematically analyzing each factor that affects the esthetic result, and recognizing inadequacies in osseous and gingival contour, the restorative dentist can take advantage of the benefits of orthodontic and periodontal treatment to enhance the esthetic and functional outcomes. Without an interdisciplinary approach, the final outcome can be compromised. With a team approach to the management of patients who require implants, fewer compromises will occur and more ideal restorations can be developed with predictable results.

CDA

References / 1. Nowzari H, Aesthetic periodontal therapy: introduction. *Periodontol 2000* (27): 7, 2001.

2. Rufenacht CR, Fundamentals of esthetics, Chicago, IL: Quintessence Publishing Co. Inc., 1990.

3. Phillips K, Kois JC, Aesthetic peri-implant site development. The restorative connection. *Dent Clin North Am* 42: 57-70, 1998.

4. Schincaglia GP, Nowzari H, Surgical treatment planning for the single-unit implant in esthetic areas. *Periodontol 2000* 27: 162-82, 2001.

5. Adell R, Eriksson B, Lekholm U, et al. A long-term follow-up study of osseointegrated implants in the treatment of totally edentulous jaws. *Int J Oral Maxillofac Impl* 5(4): 347-59, 1990.

6. Roblee RD, interdisciplinary dentofacial therapy, a comprehensive approach to optimal patient care. Quintessence Publishing Co. Inc., 17-43, 1994.

7. Chiche FA, Leriche MA, Multidisciplinary implant dentistry for improved esthetics and function. *Pract Periodont Aesthet Dent* 10(2): 177-86, 1998.

8. Smalley W, et al Osseointegrated titanium implants for maxillofacial protraction in monkeys. *Am J Orthod Dentofac Orthop* 94: 285-95, 1988.

9. Douglas J, Killinay D, Dental implants used as orthodontic anchorage. *J Oral Implantol* 13: 28-38, 1988.

10. Kokitch V, Managing complex orthodontic problems. The use of implants for anchorage. *Semin Orthodont* 2: 153-60, 1996.

11. Smalley WM, Implants for tooth movement. Determining implant location and orientation. *J Esthet Dent* 7: 62-72, 1995.

12. Smalley WM, Implants for tooth movement. A fabrication and placement technique for provisional restorations. *J Esthet Dent* 7: 150-4, 1995.

13. Magne P, Belser U, Bonded porcelain restorations in the anterior dentition: a biomimetic approach. Quintessence Publishing Co. Inc., 57-99, 2002.

14. D'Addona A, Nowzari H, Intramembranous autogenous osseous transplants in aesthetic treatment of alveolar atrophy. *Periodontol 2000* 27: 148-61, 2001.

15. Jansen C, Weisgold A, Presurgical treatment planning for the anterior single tooth implant restoration. *Compend Cont Educ Dent* 16(8): 746-62, 1995.

16. Hochwald DA, Surgical template impression during stage one surgery for fabrication of a provisional restoration to be placed at stage two surgery. *J Prosthet Dent* 66: 796-8, 1991.

17. Chee WWL, Treatment planning and soft-tissue management for optimal implant esthetics. A Prosthodontic perspective. *J Calif Dent Assoc* 31(7): 559-63, July 2003.

To request a printed copy of this article, please contact / Sajid A. Jivraj, DDS, MSED, University of Southern California School of Dentistry, Room 4375, University Park, Los Angeles CA 90089-0641.



Immediate Implant Placement: Diagnosis, Treatment Planning and Treatment Steps for Successful Outcomes

WILLIAM BECKER, DDS, MSD

ABSTRACT

Diagnosis and treatment planning are key factors in achieving successful outcomes after placing and restoring implants placed immediately after tooth extraction. The efficacy of immediate implant placement has been established and shown to be predictable if reasonable guidelines are followed. Some or all of the following suggestions, depending on individual circumstances should be considered when evaluating a patient for dental implants: thorough medical and dental histories, clinical photographs, study casts, periapical and panoramic radiographs, as well as a linear tomography or computerized tomography of the proposed implant sites. Reasons for tooth extraction include, but are not limited to, insufficient crown to root ratios, remaining root length, periodontal attachment levels, periodontal health of teeth adjacent to the proposed implant sites, unrestorable caries, root fractures with large endodontic posts, root resorption, teeth with deep furcation invasions being considered as abutments for fixed partial dentures, and questionable teeth in need of endodontic retreatment. Teeth requiring root amputations, hemisections or advanced periodontal procedures may have a questionable prognosis, and patients should be given the implant option before these procedures are implemented. Similarly, nonvital teeth, fractured at the gingival margin with roots shorter than 13 mm should be considered for the implant option. This review will describe the steps for immediate implant placement at the time of extraction as well as the "gap" and socket preservation.

Placement of endosseous implants has made it possible to restore patients who are fully or partially edentulous.¹⁻⁵ Original protocols required placement of implants into healed edentulous ridges. Lizzara placed implants at the time of extraction.⁶ These implants were augmented with barrier membranes to preserve ridge width and height and to decrease total treatment time. Becker et al. reported a 93.3 percent implant survival rate for implants placed at the time of extraction and augmented with barrier membranes after one and five years after loading.^{7,8} Over the last 16 years, numerous studies have confirmed the predictability of placing implants at the time of extraction.⁹⁻¹⁴ Small osseous defects are frequently found adjacent to implants placed at the time of extraction. These defects can be implanted with small autogenous grafts taken from edentulous ridges or other sites.^{15,16} A prospective clinical trial placed implants immediately after tooth extraction.⁵ Defects

Author / William Becker, DDS, MSD, is a clinical professor in the Department of Periodontics at the University of Southern California School of Dentistry.



were grafted with small autologous bone chips harvested from adjacent edentulous ridges. One year after implant loading, the survival rates were 93.3 percent with clinically insignificant crestal bone loss. Others have used various materials and methods including demineralized freeze-dried bone and barrier membranes to augment edentulous ridges and small defects adjacent to dental implants.¹⁷⁻²⁸ The stability of the implant can be verified using resonance frequency analysis.²⁹⁻³⁶ This method required placement of an electronic transducer onto the implant head or prosthetic abutment with a retaining screw, and passing a low-voltage current through the transducer. The current is not detected by the patient. Resistance to vibration of the transducer to the surrounding bone was registered in a small, special small computer. The original research measurements were made in hertz. Hertz measurements were calibrated for each transducer and converted to implant stability quotient units by the computer. Measurements were recorded as implant stability quotient values.

A recent study evaluated stability of implants placed at the time of extraction with resonance frequency analysis.³⁷ Stability measurements were taken at the time of implant placement and after healing. The average interval between implant insertion and abutment connection was 5.6 months (SD 2.05). Two implants were lost between implant insertion and one year. At two to three years, the cumulative survival is 97.2 percent. Resonance frequency measurements at implant placement showed a mean primary stability of 62.0 ± 9.8 implant stability quotient (range 43 to 83) and a mean secondary stability after one year of 64.0 ± 9.8 implant stability quotient (range 40 to 98) for all implants. The increase was not statisti-

cally significant. The primary stability in the maxilla was significantly lower ($p < 0.05$) than in the mandible, while no difference was seen for secondary stability. Initial average stability measurements were high. Measurements taken after healing were not significantly higher than those recorded initially. Studies indicated that implants with a resonance frequency analysis greater than 50 are stable. Sites which receive

The most important step in treatment planning is determining the prognosis for the dentition and, in particular, prognosis for the tooth in question.

implants at the time of extraction or within a short time after extraction demonstrate slight decreases in crestal bone width.^{38,39}

It is the purpose of this paper to review the concept of immediate implant placement and to expand the indications, limitations, anatomic, prosthetic and esthetic requirements for placement of implants at the time of extraction. Further, the concept of "socket preservation" for sites that might receive dental implants will be discussed.

Diagnosis and Treatment Planning

Diagnosis and treatment planning are key factors in achieving successful outcomes after placing and restoring implants placed immediately after

tooth extraction. Following some or all of the subsequent suggestions, depending on individual circumstances, should be considered when evaluating a patient for dental implants: thorough medical and dental histories, clinical photographs, study casts, periapical and panoramic radiographs, as well as a linear tomography or computerized tomography of the proposed implant sites.

The most important step in treatment planning is determining the prognosis for the dentition and, in particular, prognosis for the tooth in question. Reasons for tooth extraction may include, but are not limited to, insufficient crown to root ratios, remaining root length, periodontal attachment levels, status of furcations, periodontal health of teeth adjacent to the proposed implant site, unrestorable caries, root fractures with large endodontic posts, root resorption and questionable teeth in need of endodontic retreatment.⁴⁰ Teeth requiring root amputations, hemisections or advanced periodontal procedures may have a questionable prognosis and patients should be given reasonable options before these procedures are implemented. Similarly, the option for implant placement for non-vital teeth fractured at the gingival margin with roots shorter than 13 mm should be considered as the treatment of choice.⁴¹ If treated, these teeth will require crown lengthening procedures, endodontic treatment, posts and crowns. Removal of three or more millimeters of periodontal attachment during crown lengthening results in root length with less than optimal attachment. These factors are critical when teeth are being considered for abutments for fixed partial dentures. The risk to cost benefit ratio must also be considered.

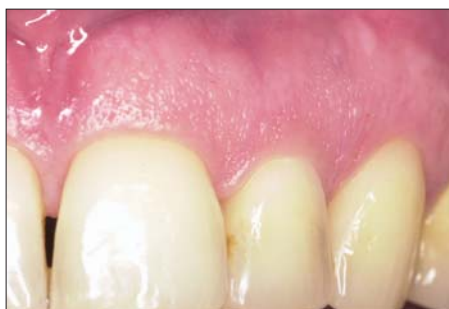

Figure 1a. The maxillary left lateral incisor has a blunted short root with a severe palatal infection related to a nonvital tooth.

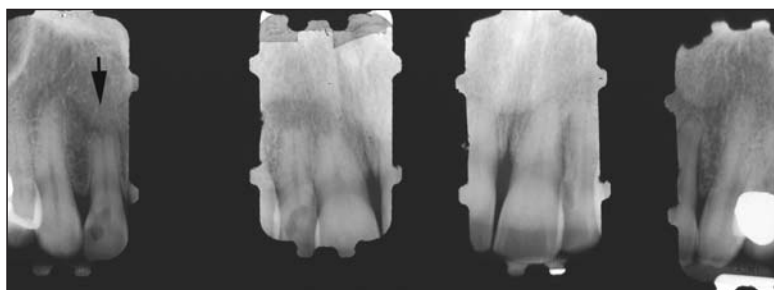


Figure 1b. Left maxillary lateral incisor (arrow) has a blunted apex, possible coronal fracture and a draining abscess.

In the esthetic zone bone morphology, scallop of the periodontium, level of crestal and interproximal bone, smile line, morphology of the gingival tissues (flat, scalloped, pronounced scalloped) must be considered before initiating treatment.⁴²⁻⁴⁵ Proposed interimplant distance as well as existing contact relationships and interproximal bone must be analyzed prior to implant placement.^{46,47} Patients with a thin or moderately thin periodontium will have soft tissue recession at the implanted sites. In these situations, it is advisable to use orthodontic forced eruption procedures prior to tooth removal and implantation. This allows bone and soft tissues to move coronally, thereby assuring adequate mucosal tissue adjacent to the implant. Where there is a soft tissue deficiency, subepithelial connective tissue grafting can further augment tissue height and thickness, thereby enhancing the esthetic results.^{48,49} This procedure compensates for the slight soft tissue recession which usually occurs after tooth extraction.

Radiographic evaluation should consider the availability of native bone, bone shape, quality, quantity, bone width and height. A minimum of 4 to 5 mm of bone width at the crest and 10 mm or greater from the alveolar crest to

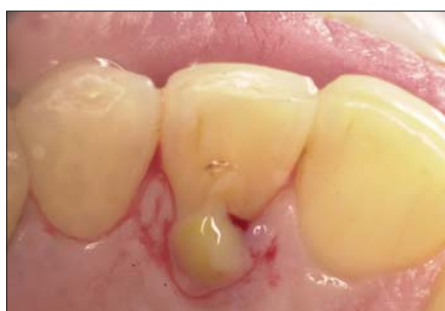

Figure 1c. Suppuration expressed from palatal aspect of maxillary left lateral incisor.

a safe distance above the mandibular canal is recommended.⁵⁰ Sufficient distance must be available coronal to the maxillary sinus and floor of the nose. For a satisfactory esthetic result on the esthetic zone, the interproximal bone height should be 5 mm or less when measured from the contact point of the adjacent tooth.⁴⁷ As the distance from the contact point to the interproximal bone increases, the likelihood of retention of the interproximal papillae post implant placement diminishes.

Once the decision has been confirmed that the patient is a candidate for immediate implant placement, a surgical guide should be used to assure proper implant placement. A provisional appliance with an ovate pontic should be available for insertion after implant placement.⁵¹⁻⁵⁷

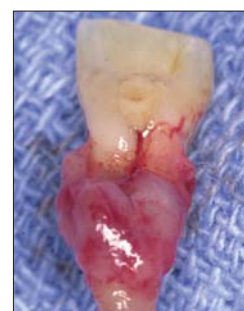

Figure 1d. Extensive palatal granulation tissue.

Tooth Extraction and Implant Placement Procedure

The patient is anesthetized and various flap procedures can be utilized to gain access for tooth extraction.⁵⁸ **Figures 1a through 1l** represent the author's routine surgical sequence for placement of a single tooth in the esthetic zone after immediate implant placement. With experience, the surgeon can displace the marginal tissues buccal/lingually to gain access to the surgical site (**Figure 1e**). A Molt C2 (HuFriedy, Chicago, Ill.) can be used to luxate the root mesial-distally. Care must be exercised not to luxate buccal-lingually. Excessive force in this direction can damage the buccal plate. After tooth removal, a curette is used to explore the location of the buccal plate and confirm the plate is present. The surgical guide is

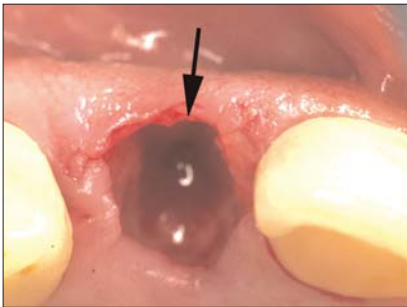


Figure 1e. Tooth has been extracted. Arrow points to socket.

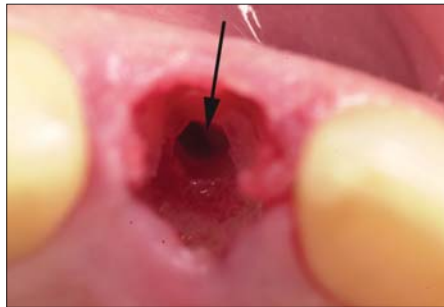


Figure 1f. Osteotomy has been prepared in palatal aspect of extraction socket.

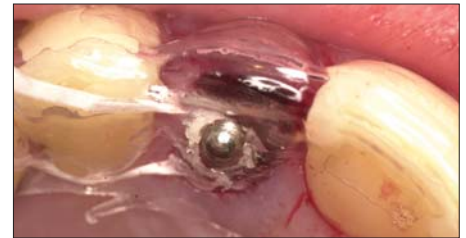

Figure 1g. Guide pin within palatal aspect of surgical guide.

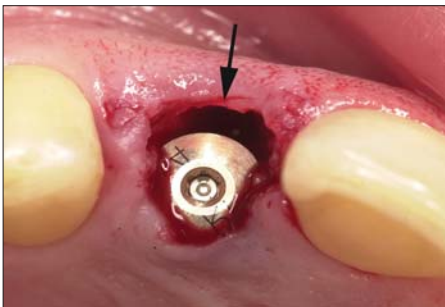


Figure 1h. Implant has been inserted into osteotomy and a 4 mm healing abutment has been placed onto the implant. Arrow points to gap between mucosal tissue and healing abutment.

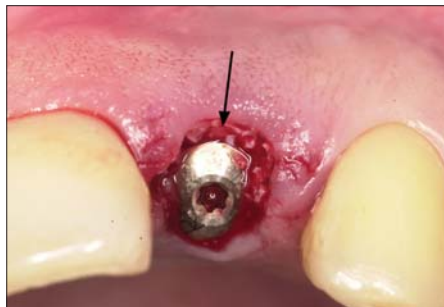

Figure 1i. Bovine bone has been layered into gap between mucosal tissue and abutment (arrow).

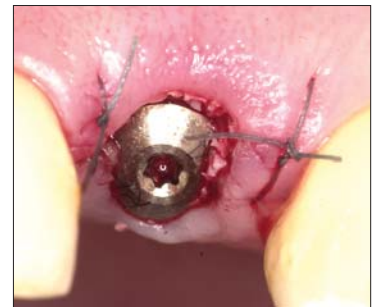

Figure 1j. Tissues sutured with no attempt to advance flap over bovine bone particles.

placed over the surgical site and a sharp drill (Nobel Biocare, Yorba Linda, Calif.) is used to penetrate the palatal wall of the extraction socket¹⁶ (Figure 1g). In the maxillary anterior region, it is important to avoid placing the implant directly into the extraction socket. Placement of the implant (Nobel Biocare) in this position will invariably cause the implant to perforate the buccal plate and jeopardize the survival of the implant. The axis of the implant must be even with the incisal edges of the adjacent teeth or slightly palatal to this landmark. A direction indicator should be used to verify the correct angulation and trajectory of the proposed implant (Figure 1h). Standard drilling procedures are performed according to the manufacturer's instructions. In the esthetic zone, the implant

head should be a minimum of 3 mm apical to an imaginary line connecting the cemento-enamel junctions of the adjacent teeth, and apical to the interproximal and crestal bone.⁵⁹ This will assure proper implant emergence profile and facilitates proper implant restoration. The stability of the implant can be verified using resonance frequency analysis. Studies indicated that implants with a resonance frequency analysis greater than 50 are stable. The torque registered on the drilling console can also be a good indicator of initial implant stability. Torque resistance of 40 Ncm is indicative of initial implant stability. Excessive torque should not be applied to the implant as this may strip the implant threads or exert excessive compression on the adjacent bone. This has the potential to result in bone necro-

sis and implant loss. Fixture level impressions are frequently made immediately after implant placement. This facilitates fabrication of prosthetic abutments and provisional restorations. After healing has occurred, the abutments and provisional restorations can be inserted onto the implants. These are inserted once osseointegration has been verified after a proper healing interval. A healing abutment can be inserted on top of the implant (Figure 1h). The abutment should be even with or slightly apical to the adjacent marginal tissues. Interproximal papillae adjacent to the implant can be adapted with interrupted sutures under minimal tension. The provisional is then inserted and evaluated, making certain the pontic is clear of the healing abutment. The provisional restoration should have an ovate pontic

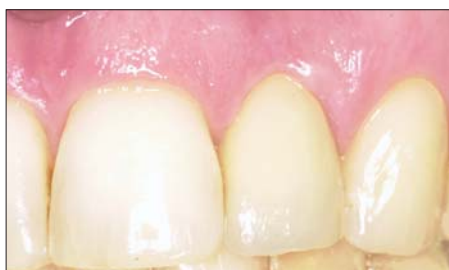

Figure 1k. Two-year follow-up photograph. Note how interdental papillae fill entire embrasure spaces. There is slight, soft tissue inflammation between lateral and canine.

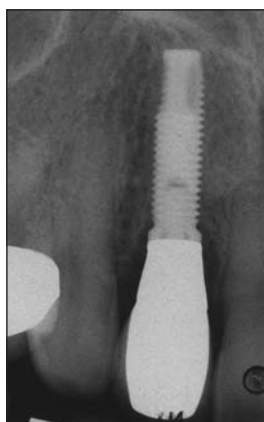


Figure 1l. Two-year follow-up X-ray. Note stable interproximal bone.

to support the adjacent tissues and help preserve soft tissue anatomy adjacent to the implant. The patient is instructed in proper after-surgery care and sutures are removed in seven to 10 days. Restoration of the implant can take place once osseointegration has been confirmed (maxillary anterior region, four to six months). In the event an immediate implant encroaches upon the maxillary sinus, it might be prudent to delay implant placement, augment the sinus, allow for bone healing, and then place the implant.

The Gap

On occasion, the marginal tissues do not adapt to the healing abutment. In experimental studies, if the gap is too wide, connective tissue forms between the coronal implant aspect and surrounding bone.^{60,61} A series of animal and human studies has demonstrated that small gaps between implants and bone will fill with bone with or without grafting materials or barriers.⁶²⁻⁶⁶ Botticelli et al. created circumferential defects in dogs (1.0 to 2.5 mm).⁶² At a few sites, the labial bone adjacent to the socket was reduced. Over a four-month healing period, the circumferential defects healed with bone. Sites where the labial bone was reduced, proper bone healing occurred at the mesial,

distal and lingual defect aspects, but reduced bone volume on the labial surface. The same authors repeated the study.⁶³ Special implants were inserted into the defects, leaving a 1.0 to 2.5 mm gap between the implants and surrounding bone. Bovine bone alone, or with a resorbable barrier, was used to augment some sites, while others were left to spontaneously heal. It was demonstrated that at four months, all defects were filled with the newly formed bone and the biomaterial placed in the marginal defect, in conjunction with implant installation, became incorporated in the newly formed bone tissue. A high degree of contact was established between the bovine bone particles and the newly formed bone. In the model used, bovine bone did not enhance the process of bone formation and defect closure.

In practice, when the gap is present, no effort is made to surgically advance the flap (**Figure 1h**). A small amount of allograft or alloplast is layered between the margin and implant abutment (**Figure 1i**). This material is left exposed. Within a few weeks, some of the material will be exfoliated and gingival mucosa will migrate over the exposed materials, and healing is uneventful.

Bovine bone (BioOss, Switzerland)

has been used to augment small gaps adjacent to immediately placed implants.^{68,69} Results from these studies demonstrates that the bovine bone does not affect the survival of implants. It is important to recognize that placement of bovine bone, allografts or other substances with or without barrier membranes may support or improve soft tissue contours; however, these materials cannot be relied upon to enhance osseointegration.

Socket Preservation

Socket preservation is a relatively new term to implant dentistry. It implies that placement of varying implantable materials within the sockets alone or with barrier membranes maintains socket anatomy. To date, there is inconclusive evidence this procedure maintains original socket dimensions. There is some evidence that placement of foreign materials into extraction sockets will interfere with normal bone formation.⁷⁰⁻⁷² Iasella et al. compared normal socket healing with those grafted with demineralized freeze-dried bone and covered with a collagen barrier membrane. Unaugmented or grafted sockets decreased in width by an average of 1.7 mm, while grafted sites decreased by 1.2 mm (difference of 0.5 mm). The quantity of bone observed on histologic analysis was slightly greater in preservation sites, although these sites included both vital and nonvital bone. Others compared ridge dimensions and histologic characteristics of ridges preserved with two different graft materials.⁷³ Twenty-four subjects, each requiring a nonmolar extraction and delayed implant placement, were randomly selected to receive ridge preservation treatment with either an allograft in an experimental putty carrier, plus a calcium sulfate barrier or a bovine-derived xenograft, plus a collagen membrane.



Horizontal and vertical ridge dimensions were determined using a digital caliper and a template. At four months postextraction, a trephine core was obtained for histologic analysis. Allograft, mixed with an experimental putty carrier, produced significantly more vital bone fill than did the use of a xenograft with no carrier material. Ridge width and height dimensions were similarly preserved with both graft materials. Placement of materials into extraction sockets might be termed osseointerference.

There is evidence that resorbable barriers, without grafting reduces alveolar ridge resorption after tooth extraction.⁷⁴ Following elevation of buccal and lingual full-thickness flaps and extraction of teeth, experimental sites were covered with bioabsorbable membranes; control sites did not receive any membrane. Titanium pins served as fixed reference points for measurements. Flaps were advanced in order to achieve primary closure of the surgical wound. There was no membrane exposure during the course of healing. Re-entry surgeries were performed at six months. Results showed that experimental sites presented with significantly less loss of alveolar bone height, more internal socket bone fill, and less horizontal resorption of the alveolar bone ridge. This study suggests that treatment of extraction sockets with membranes made of glycolide and lactide polymers are valuable in preserving alveolar bone in extraction sockets and preventing alveolar ridge defects. Use of these materials may minimize crestal resorption, and may be indicated to minimize ridge resorption if dental implants are not part of the treatment plan. Placement of implants into these materials may limit osseointegration. Until there is sufficient evidence that these materials maintain socket anat-

omy and do not interfere with osseointegration, caution should be exercised.

Conclusion

The purpose of this paper was to review the history, predictability, rationale and treatment planning steps for implant placement immediately after tooth extraction. Multicenter studies have validated the predictability of

Until there is
sufficient evidence
that these materials
maintain socket
anatomy and do
not interfere with
osseointegration, caution
should be exercised.

placing implants at the time of extraction provided these procedures are appropriately treatment planned.^{7,75-77} To date, evidence for placement of bone substitutes adjacent to small bone defects related to immediately placed implants appears safe, although these materials do not appear to predictably promote osseointegration. There is insufficient evidence that "socket preservation" procedures predictably maintain socket anatomy without crestal resorption. Bone substitutes implanted into extraction sockets may interfere with normal bone healing and ultimately osseointegration. **CDA**

References / 1. Brånemark PI, Hansson BO, Adell R, et al, Osseointegrated implants in the treatment of the edentulous jaw. Experience from a 10-year period. *Scand J Plast Reconstr Surg Suppl* 16:1-132, 1977.

2. Adell R, Lekholm U, Brånemark PI, A 15-

year study of osseointegrated implants in the treatment of the edentulous jaw. *Int J Oral Surg* 10: 387-418, 1985.

3. van Steenberghe D, Brånemark PI, Quirynen M, et al, The rehabilitation of oral defects by osseointegrated implants. *J Clin Periodontol* 18: 488-93, 1991.

4. Brånemark PI, Svensson B, van Steenberghe D, Ten-year survival rates of fixed prostheses on four or six implants ad modum Brånemark in full edentulism. *Clin Oral Implants Res* 6: 227-31, 1995.

5. Brånemark PI, Engstrand P, Öhrnell LO, et al, Brånemark Novum: A new treatment concept for rehabilitation of the edentulous mandible. Preliminary results from a prospective clinical follow-up study. *J Clin Implant Dent and Related Research* 1: 2-16, 1999.

6. Lazzara RJ, Immediate implant placement into extraction sites: surgical and restorative advantages. *Int J Periodontics Restorative Dent* 9:332-43, 1989.

7. Becker W, Dahlin C, Becker BE, et al, The use of e-PTFE barrier membranes for bone promotion around titanium implants placed into extraction sockets: a prospective multicenter study. *Int J Oral Maxillofac Implants* 9: 31-40, 1994.

8. Becker W, Dahlin C, Lekholm U, et al, Five-year evaluation of implants placed at extraction and with dehiscences and fenestration defects augmented with ePTFE membranes: results from a prospective multicenter study. *Clin Implant Dent Relat Res* 1: 27-32, 1999.

9. Gelb DA, Immediate implant surgery: three-year retrospective evaluation of 50 consecutive cases. *Int J Oral Maxillofac Implants* 8:388-99, 1993.

10. Lang NP, Bragger U, Hammerle CH, et al, Immediate transmucosal implants using the principle of guided tissue regeneration. I. Rationale, clinical procedures and 30-month results. *Clin Oral Implants Res* 5:154-63, 1994.

11. Rosenquist B, Grenthe B, Immediate placement of implants into extraction sockets: implant survival. *Int J Oral Maxillofac Implants* 11: 205-9, 1996.

12. Schwartz-Arad D, Chaushu G, Placement of implants into fresh extraction sites: Four to seven years' retrospective evaluation of 95 immediate implants. *J Periodontol* 68:1110-6, 1997.

13. Schwartz-Arad D, Chaushu G, The ways and wherefores of immediate placement of implants into fresh extraction sites: a literature review. *J Periodontol* 68: 915-23, 1997.

14. Schwartz-Arad D, Grossman Y, Chaushu G, The clinical effectiveness of implants placed immediately into fresh extraction sites of molar teeth. *J Periodontol* 71: 839-44, 2000.

15. ten Bruggenkate C, Kraaijenhagen H, van der Swast W, et al, Autogenous maxillary bone grafts in conjunction with placement of ITI endosseous implants. AS preliminary report. *Int J Oral Maxillofac Surg* 21: 81-4, 1996.

16. Becker W, Becker BE, Polizzi G, et al, Autogenous bone grafting of bone defects adjacent to implants placed into immediate extraction sockets in patient: A prospective study. *Int J Oral Maxillofac Implants* 9: 389-96, 1994.

17. Nevins M, Mellonig JT, Enhancement of the damaged edentulous ridge to receive dental implants: a combination of allograft and the GORE-TEX membrane. *Int J Periodontics Restorative Dent* 12: 96-111, 1992.

18. Mellonig JT, Triplett RG, Guided tissue

regeneration and endosseous dental implants. *Int J Periodontics Restorative Dent* 13: 108-19, 1993.

19. Nevins M, Mellonig JT, The advantages of localized ridge augmentation prior to implant placement: a staged event. *Int J Periodontics Restorative Dent* 14: 96-111, 1994.

20. Mellonig JT, Nevins M, Guided bone regeneration of bone defects associated with implants: an evidence-based outcome assessment. *Int J Periodontics Restorative Dent* 15: 168-85, 1995.

21. Buser D, Ruskin J, Higginbottom F, et al, Osseointegration of titanium implants in bone regenerated in membrane-protected defects: a histologic study in the canine mandible. *Int J Oral Maxillofac Implants* 10: 666-81, 1995.

22. Buser D, Dula K, Belser UC, et al, Localized ridge augmentation using guided bone regeneration. II. Surgical procedure in the mandible. *Int J Periodontics Restorative Dent* 15: 10-29, 1995.

23. Buser D, Dula K, Hirt HP, et al, Lateral ridge augmentation using autografts and barrier membranes: a clinical study with 40 partially edentulous patients. *J Oral Maxillofac Surg* 54: 420-32, 1996.

24. Buser D, Dula K, Lang NP, et al, Long-term stability of osseointegrated implants in bone regenerated with the membrane technique. 5-year results of a prospective study with 12 implants. *Clin Oral Implants Res* 7: 175-83, 1996.

25. Buser D, Hoffmann B, Bernard JP, et al, Evaluation of filling materials in membrane-protected bone defects. A comparative histomorphometric study in the mandible of miniature pigs. *Clin Oral Implants Res* 9: 137-50, 1998.

26. Gotfredsen K, Nimb L, Buser D, et al, Evaluation of guided bone generation around implants placed into fresh extraction sockets: an experimental study in dogs. *J Oral Maxillofac Surg* 51: 879-84, 1993.

27. Buser D, Bragger U, Lang NP, et al, Regeneration and enlargement of jaw bone using guided tissue regeneration. *Clin Oral Implants Res* 1: 22-32, 1990.

28. Hermann JS, Buser D, Guided bone regeneration for dental implants. *Curr Opin Periodontol* 3:168-177, 1996.

29. Meredith N, Alleyne D, Cawley P, Quantitative determination of the stability of the implant-tissue interface using resonance frequency analysis. *Clin Oral Implants Res* 7: 261-7, 1996.

30. Meredith N, Book K, Friberg B, et al, Resonance frequency measurements of implant stability in vivo. A cross-sectional and longitudinal study of resonance frequency measurements on implants in the edentulous and partially dentate maxilla. *Clin Oral Implants Res* 8: 226-33, 1997.

31. Meredith N, Shagaldi F, Alleyne D, et al, The application of resonance frequency measurements to study the stability of titanium implants during healing in the rabbit tibia. *Clin Oral Implants Res* 8:234-43, 1997.

32. Rasmusson L, Meredith N, Sennerby L, Measurements of stability changes of titanium implants with exposed threads subjected to barrier membrane induced bone augmentation. An experimental study in the rabbit tibia. *Clin Oral Implants Res* 8: 316-22, 1997.

33. Rasmusson L, Meredith N, Kahnberg KE, et al, Stability assessments and histology of titanium implants placed simultaneously with autogenous onlay bone in the rabbit tibia. *Int J Oral Maxillofac Surg* 27: 229-35., 1998.

34. Sennerby L, Meredith N, Resonance fre-

quency analysis: measuring implant stability and osseointegration. *Compend Contin Educ Dent* 19: 493-8, 500, 502; quiz 504, 1998.

35. Rasmusson L, Meredith N, Kahnberg et al, Effects of barrier membranes on bone resorption and implant stability in onlay bone grafts. An experimental study. *Clin Oral Implants Res* 10: 267-77, 1999.

36. Sennerby L, Friberg B, Linden B, et al, A comparison of implant stability in mandibular and maxillary bone using RFA. Gothenburg, Sweden, *Vasastadens Bokbinderi AB*, 2000.

37. Becker W, Sennerby L, Bedrossian E, et al, Implant stability measurements for implants placed at the time of extraction: P A Cohort, Prospective Clinical Trial. *J Periodontol* 76: 2005.

38. Nir-Hadar O, Palmer M, Soskolne WA, Delayed immediate implants: alveolar bone changes during the healing period [In Process Citation]. *Clin Oral Implants Res* 9: 26-33, 1998.

39. Becker W, Hujoel P, Becker BE, Effect of barrier membranes and autologous bone grafts on ridge width preservation around implants. *Clin Implant Dent Relat Res* 4: 143-9, 2002.

40. Becker W, Becker BE, Hujoel P, Retrospective case series analysis of the factors determining immediate implant placement. *Compend Contin Educ Dent* 21: 805-8, 810, 814 passim; quiz 820, 2000.

41. Lovdahl P, Endodontic retreatment. *Dent Clin North Am* 47:3-90, April 1992.

42. Ochsenein C, S R, A re-evaluation of osseous surgery., in *Dental Clinics of North America*, Philadelphia, PA, W.B. Saunders, pp 87-102, 1969.

43. Becker W, Ochsenein C, Tibbetts L, et al, Alveolar bone anatomic profiles as measured from dry skulls. Clinical ramifications. *J Clin Periodontol* 24: 727-31, 1997.

44. Kois JC, Predictable single tooth peri-implant esthetics: five diagnostic keys. *Compend Contin Educ Dent* 25:895-905; quiz 905, 2004.

45. Kan JYK, Rungcharassaeng K, Kiyotaka U, et al, Dimensions of peri-implant mucosa: an evaluation of maxillary anterior single implants in humans. *J Periodontol* Accepted for publication, 2003.

46. Tarnow DP, Magner AW, Fletcher P, The effect of the distance from the contact point to the crest of bone on the presence or absence of the interproximal dental papilla. *J Periodontol* 63: 995-6, 1992.

47. Tarnow D, Elian N, Fletcher P, et al, Vertical distance from the crest of bone to the height of the interproximal papilla between adjacent implants. *J Periodontol* 74: 1785-8, 2003.

48. Langer B, The esthetic management of dental implants. *Dent Econ* 85: 86-7, 1995.

49. Langer B, The regeneration of soft tissue and bone around implants with and without membranes. *Compend Contin Educ Dent* 17: 268-70, 272 passim; quiz 280, 1996.

50. Worthington P, Injury to the inferior alveolar nerve during implant placement: a formula for protection of the patient and clinician. *Int J Oral Maxillofac Implants* 19: 731-4, 2004.

51. Miller MB, Aesthetic anterior reconstruction using a combined periodontal/restorative approach. *Pract Periodontics Aesthet Dent* 5: 33-40; quiz 42, 1993.

52. Johnson GK, Leary JM, Pontic design and localized ridge augmentation in fixed partial den-

ture design. *Dent Clin North Am* 36: 591-605, 1992.

53. Miller MB, Ovate pontics: the natural tooth replacement. *Pract Periodontics Aesthet Dent* 8: 140, 1996.

54. Dylina TJ, Contour determination for ovate pontics. *J Prosthet Dent* 82:136-42, 1999.

55. Zitzmann NU, Marinello CP, Berglundh T, The ovate pontic design: a histologic observation in humans. *J Prosthet Dent* 88: 375-80, 2002.

56. Berman F, The creation of an ovate pontic at the time of extraction. *Dent Today* 22:48-9, 2003.

57. Levine RA, Makrauer Z, The use of periodontal plastic surgery procedures in aiding esthetic restorative results. *Compend Contin Educ Dent* 24: 729-34, 736, 738 passim; quiz 741, 2003.

58. Becker W, Becker BE, Flap designs for minimization of recession adjacent to maxillary anterior implant sites: a clinical study. *Int J Oral Maxillofac Implants* 11: 46-54, 1996.

59. Langer B, Sullivan DY, Osseointegration: its impact on the interrelationship of periodontics and restorative dentistry. Part 3. Periodontal prosthesis redefined. *Int J Periodontics Restorative Dent* 9: 240-61, 1989.

60. Carlsson L, Rostlund T, Albrektsson B, et al, Implant fixation improved by close fit. Cylindrical implant-bone interface studied in rabbits. *Acta Orthop Scand* 59: 272-5, 1988.

61. Akimoto K, Becker W, Donath K, et al, Formation of bone around titanium implants placed into zero wall defects: pilot project using reinforced e-PTFE membrane and autogenous bone grafts. *Clin Implant Dent Relat Res* 1: 98-104, 1999.

62. Scipioni A, Bruschi GB, Giorgia M, et al, Healing at implants with and without primary bone contact. An experimental study in dogs. *Clin Oral Implants Res* 8: 39-47, 1997.

63. Botticelli D, Berglundh T, Lindhe J, Hard-tissue alterations following immediate implant placement in extraction sites. *J Clin Periodontol* 31: 820-8, 2004.

64. Botticelli D, Berglundh T, Lindhe J, The influence of a biomaterial on the closure of a marginal hard tissue defect adjacent to implants. An experimental study in the dog. *Clin Oral Implants Res* 15: 285-92, 2004.

65. Botticelli D, Berglundh T, Lindhe J, Resolution of bone defects of varying dimension and configuration in the marginal portion of the peri-implant bone. An experimental study in the dog. *J Clin Periodontol* 31: 309-17, 2004.

66. Botticelli D, Berglundh T, Buser D, et al, The jumping distance revisited: An experimental study in the dog. *Clin Oral Implants Res* 14: 35-42, 2003.

67. Botticelli D, Berglundh T, Buser D, et al, Appositional bone formation in marginal defects at implants. *Clin Oral Implants Res* 14: 1-9, 2003.

68. van Steenberghe D, Callens A, Geers L, et al, The clinical use of deproteinized bovine bone mineral on bone regeneration in conjunction with immediate implant installation. *Clin Oral Implants Res* 11: 210-16, 2000.

69. Zitzmann NU, Naef R, Scharer P, Resorbable versus nonresorbable membranes in combination with Bio-Oss for guided bone regeneration [published erratum appears in *Int J Oral Maxillofac Implants* 1998 Jul-Aug;13(4):576]. *Int J Oral Maxillofac Implants* 12: 844-52, 1997.

70. Becker W, Becker BE, Caffesse R, A comparison of demineralized freeze-dried bone and autologous bone to induce bone formation in human



extraction sockets [published erratum appears in *J Periodontol* 1995 Apr;66(4):309] [see comments]. *J Periodontol* 65: 1128-33, 1994.

71. Becker W, Clokie C, Sennerby L, et al, Histologic findings after implantation and evaluation of different grafting materials and titanium micro screws into extraction sockets: case reports. *J Periodontol* 69: 414-21, 1998.

72. Iasella JM, Greenwell H, Miller RL, et al, Ridge preservation with freeze-dried bone allograft and a collagen membrane compared to extraction alone for implant site development: a clinical and histologic study in humans. *J Periodontol* 74: 990-9, 2003.

73. Vance GS, Greenwell H, Miller RL, et al, Comparison of an allograft in an experimental putty carrier and a bovine-derived xenograft used in ridge preservation: a clinical and histologic study in humans. *Int J Oral Maxillofac Implants* 19: 491-7, 2004.

74. Lekovic V, Camargo PM, Klokkevold PR, et al, Preservation of alveolar bone in extraction sockets using bioabsorbable membranes. *J Periodontol* 69: 1044-9, 1998.

75. Becker W, Becker BE, Handelsman M, et al, Guided tissue regeneration for implants placed into extraction sockets and for implant dehiscences: surgical techniques and case report. *Int J Periodontics Restorative Dent* 10: 376-91, 1990.

76. Becker W, Dahlin C, Lekholm U, et al, Five-year evaluation of implants placed at extraction and with dehiscences with ePTFE membranes: Results from a prospective multicenter study. *Clin Implant Dent Related Res* 1: 27-32, 1999.

77. Becker B, Becker W, Ricci A, et al, A prospective clinical trial of endosseous screw-shaped implants placed at the time of tooth extraction without augmentation. *J Periodontol* 69:920-6, 1998.

To request a printed copy of this article, please contact / William Becker, DDS, MSD, 801 N. Wilmot, B-2, Tucson, Ariz., 85711.



Treatment Planning: Implant-Supported Partial Overdentures

WINSTON W.L. CHEE, DDS

ABSTRACT

When multiple anterior teeth are missing, many options of replacement are available. Traditionally, the choice was between a fixed or removable prostheses. Today, with the predictability of dental implants, the options of tooth replacement range from removable partial dentures to implant-supported fixed prostheses.^{1,2}

The choice of which restoration that will best provide occlusion and esthetics depends on multiple factors including the number and location of missing teeth, the residual ridge form in relation to the replacement teeth, the relationship of the maxillary and mandibular anterior teeth, the condition of teeth adjacent to the edentulous span, the amount of bone available for implant placement, the patients "smile line" and display of teeth, lip support, and financial constraints.³⁻⁶

When there is minimal loss of the ridge contour, restorations that emerge from the ridge are the most functional and esthetic restorations, adhesive-type fixed partial dentures, conventional fixed partial dentures, and implant-supported restorations can be indicated with the choice of restoration dependent on a risk benefit and cost benefit analysis. When there is a loss of ridge contour due to residual

ridge resorption or trauma, the decision becomes more complex as not only does the tooth structure need to be replaced, the ridge form also has to be replaced. (Figures 1 and 2). This can be assessed clinically as illustrated by Figures 1 and 2 where a discrepancy in arch form and ridge form in relation to the adjacent teeth and/or opposing arch can be observed. Other considerations are lip support and display of the teeth when smiling.

This article presents a case and rationale for implant-supported partial overdentures. Many authors have written on the merits of complete overdentures. The complete overdenture has proven to be an improvement over conventional complete prostheses with respect to chewing efficiency, patient comfort and satisfaction.⁷⁻¹⁰ In partial edentulism, the implant-supported overdenture has several advantages, some in common with a removable partial denture.



Author / Winston W.L. Chee, DDS, is the Ralph and Jean Bleak Professor of Restorative Dentistry director of implant dentistry at the University of Southern California School of Dentistry.



Factors that are similar to removable partial dentures as a choice would be unrestored abutment teeth, poor condition of abutment teeth, and long edentulous spans. Many patients prefer not having their abutment teeth prepared for fixed partial denture retainers, especially if their abutment teeth are largely unrestored and not in need of restorative care. Specific to anterior edentulous areas, excessive residual ridge loss from trauma or residual ridge resorption are also factors to consider since esthetics can be paramount in the anterior area (Figures 3-5). The relationship of the edentulous ridge areas to the opposing occlusion will dictate the length and inclination of the prosthetic teeth. The teeth, in turn, can impact lip support and lip esthetics. In order to reconstruct residual ridge deficiencies, grafting procedures have been described to improve residual ridge forms.¹¹⁻¹⁴ Unfortunately, these procedures are not always completely successful. Increasing ridge width is often accomplished with more certainty than increasing the height of the ridge. Distraction osteogenesis is a method to accomplish increased height of the ridge, however, increased width may also be required and a bone graft may have to be performed.^{15,16} There also remain some patients who are resistant to multiple surgical procedures and protracted treatment times. For these patients, removable partial dentures or implant-supported overdentures can be an esthetic, functional restoration with the denture flange compensating for the missing ridge tissues.

Partial overdentures supported by natural dentition are not new to dentistry. Many authors have described tissue bars attached to teeth adjacent to

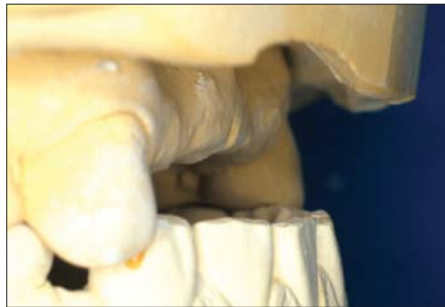

Figure 1. Articulated casts indicating severe ridge resorption and deficiency replacement pontics would have to procline severely to obtain horizontal overlap of the maxillary incisors.

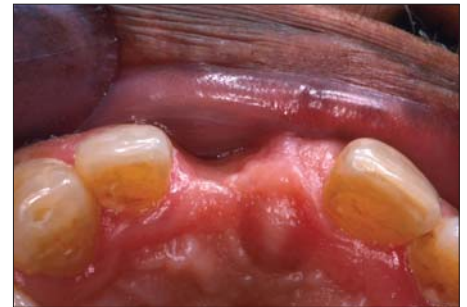

Figure 2. Occlusal view illustrating loss of ridge tissue, which also requires replacement for esthetics.

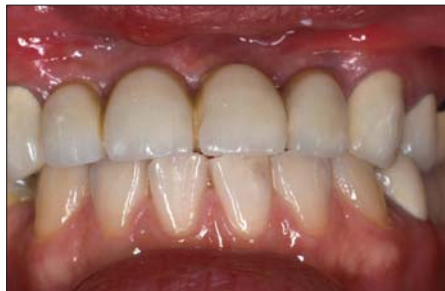

Figure 3. Anterior view of fixed partial denture replacing teeth Nos. 7-10. Note proclination of maxillary incisors.

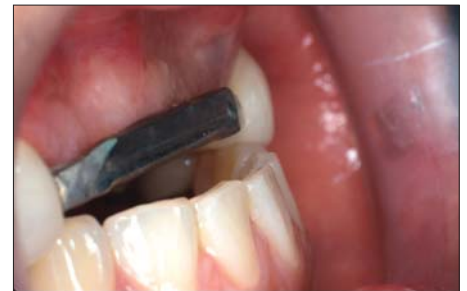

Figure 4. Tissue bar in place of patient in Figure 3.

the edentulous span and having the pontic section clip onto the tissue bar. The pontic section incorporates a flange, thus allowing the teeth and missing tissue to be restored.¹⁷⁻²¹ This type of restoration is complex and difficult to maintain. Failure of any part of the restoration is difficult to manage and often will result in a remake of the restoration to include the fixed portion (Figure 6).

Implant-supported overdentures, in many situations, may provide all the benefits of a removable partial denture and conventional partial overdenture while reducing the maintenance requirements and having the prostheses independent from the rest of the dentition. This also allows unrestored teeth adjacent to the edentulous

span to remain intact and the overdenture prostheses to be maintained separately. Moreover, the implant-supported overdenture uses the implants as support for the restoration and not the remaining teeth or mucosa. When seated, the prostheses is rigidly attached to the implants, providing a more secure restoration for the patient. Another advantage is that the surgical placement of the implants for this type of restoration is less demanding as the implants do not have to be related to individual teeth. The only requirements for use of the implant-supported partial overdenture are that sufficient inter-occlusal space exists to accommodate the restoration and sufficient bone is available to receive the implants.

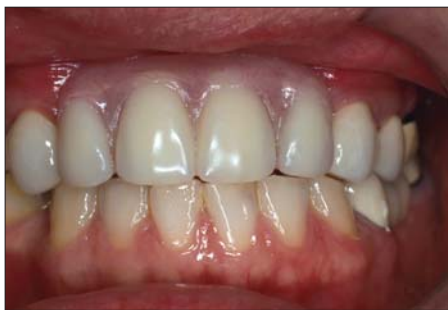

Figure 5. Improved esthetics with reorientation of pontics and a flange to replace missing ridge tissue.

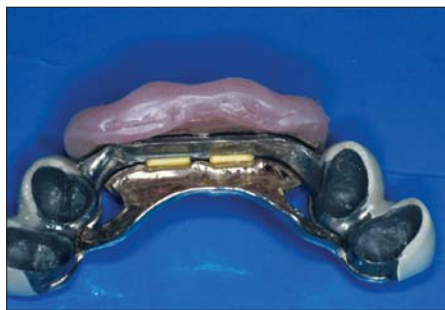

Figure 6. Assembled restoration in Figure 5 prior to insertion. Note thickness of flange replacing lost ridge tissue and the complexity of the restoration making maintenance difficult.

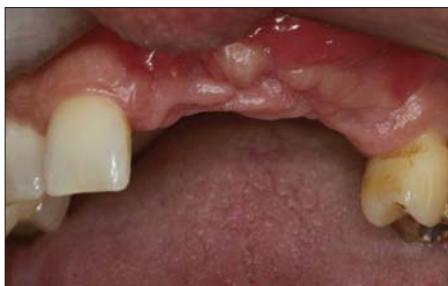

Figure 7. Initial presentation of patient with teeth Nos. 9 to 12 missing and severe ridge defect.

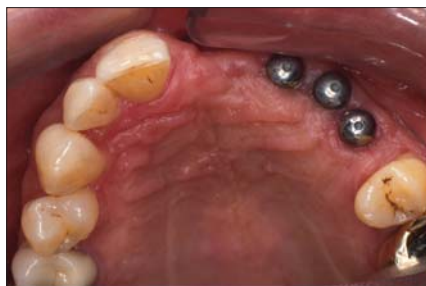

Figure 8. Implants in position.

Case Presentation

A patient presented with a history of trauma to the maxilla. Teeth Nos. 9 to 12 were avulsed and significant ridge loss resulted as evidenced clinically (Figure 7). The patient presented with a removable partial denture and was satisfied with the esthetics of the restoration. However, he desired a more stable prosthesis that would provide similar esthetics. The patient was provided with treatment options to restore the missing alveolar ridge tissue, which would require multiple surgeries. He elected to have an implant-supported overdenture to restore the missing teeth and tissue. Sufficient implants were planned to support a fixed prosthesis as the occlusal forces would be borne by the implants alone and not shared with tissues. The

distribution of the implants was planned to maximize stability of the prosthesis to avoid an axis of rotation (Figure 8). After a suitable time to allow implant integration, a substructure bar was fabricated. The substructure was verified for passivity to the implants with a screw test where one screw was placed on one of the terminal implants and the fit of the bar evaluated radiographically. Then, the superstructure bar and overdenture were fabricated to fit over the tissue bar. When seated, the restoration was rigidly fixed to the underlying tissue bar by way of locking swivel clips (Figure 10). While seated, and with swivel clips locked, the prosthesis was rigidly fixed to the substructure bar and implants, but could easily be removed when the clips were unlatched. The arch form and dentition

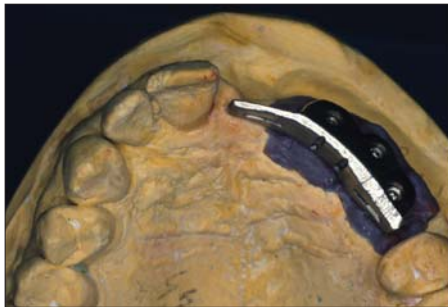


Figure 9. Substructure on cast, occlusal view.

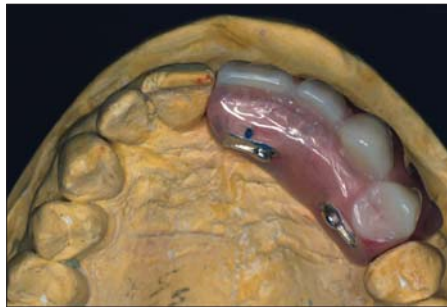


Figure 10. Overdenture in place over substructure, note how the flange compensates for the severe ridge defect.

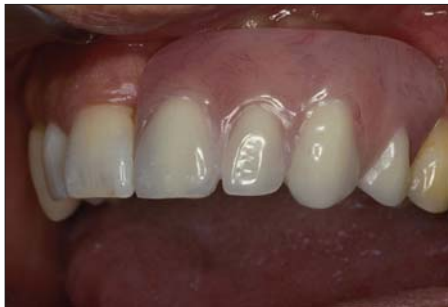

Figure 11. Intraoral view of prostheses in place.

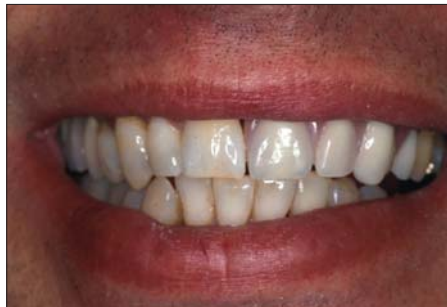

Figure 12. Extraoral view of prostheses. It is always difficult to manage the tooth-prostheses interface when there is severe tissue loss and the tooth is left unrestored.

implant overdentures: Part I – retention, stability, and tissue response. *J Prosthet Dent* 73: 354-63, 1995.

9. Cune MS, dePutter C, Hoogstraten J, Treatment outcome with implant-retained overdentures: Part I - Clinical findings and predictability of clinical treatment outcome. *J Prosthet Dent* 72: 144-51, 1994.

10. Cune MS, dePutter C, Hoogstraten J, Treatment outcome with implant-retained overdentures: Part II - Patient satisfaction and predictability of subjective treatment outcome. *J Prosthet Dent* 72: 152-8, 1994.

11. D'Addona A, Nowzari H, Intramembranous autogenous osseous transplants in aesthetic treatment of alveolar atrophy. *Periodontol* 2000 27: 148-61, 2001.

12. Schincaglia GP, Nowzari H, Surgical treatment planning for the single-unit implant in aesthetic areas. *Periodontol* 2000 27: 162-82, 2001.

13. Zeiter DJ, Ries WL, Sanders JJ, The use of a bone block graft from the chin for alveolar ridge augmentation. *Int J Periodontics Restorative Dent* 20(6): 618-27, December 2000.

14. Garg AK, Morales MJ, Navarro I, et al, Autogenous mandibular bone grafts in the treatment of the resorbed maxillary anterior alveolar ridge: rationale and approach. *Implant Dent* 7(3): 169-76, 1998.

15. Chin M. Distraction osteogenesis for dental implants. *Atlas Oral Maxillofac Surg Clin North Am* 7(1): 41-63, March 1999.

16. Uckan S, Dolanmaz D, Kalayci A, et al, Distraction osteogenesis of basal mandibular bone for reconstruction of the alveolar ridge. *Br J Oral Maxillofac Surg* 40(5): 393-6, October 2002.

17. de Carvalho WR, Barboza EP, Caula AL, Implant-retained removable prosthesis with ball attachments in partially edentulous maxilla. *Implant Dent* 10(4): 280-4, 2001.

18. Asvanund C, Morgano SM, Restoration of unfavorably positioned implants for a partially edentulous patient by using an overdenture retained with a milled bar and attachments: a clinical report. *J Prosthet Dent* 91(1): 6-10, January 2004.

19. Davodi A, Nishimura R, Beumer J III, An implant-supported fixed-removable prosthesis with a milled tissue bar and Hader clip retention as a restorative option for the edentulous maxilla. *J Prosthet Dent* 78(2): 212-7, August 1997.

20. Nelson DR, von Gonten AS, Biomechanical and esthetic considerations for maxillary anterior overdenture abutment selection. *J Prosthet Dent* 72(2): 133-6, August 1994.

21. Elton WC, Hannon SM, The partial overdenture in management of anterior apertognathia: a clinical report. *J Prosthodont* 9(2): 99-101, June 2000.

To request a printed copy of this article, please contact / Winston W.L. Chee, DDS, 1156 E. Green St., Suite 102, Pasadena, Calif., 91106-2515.

was restored with the partial overdenture (Figures 9, 10). The bar and prostheses were delivered to the patient, who was satisfied with the stability and esthetics of the restoration.

Summary and Conclusions

Implant-supported overdentures can provide many of the same advantages of removable partial dentures when restoring lost teeth and alveolar tissue. Implant-supported overdentures have the added advantage of obtaining their support from the implants, and having minimal tooth and tissue coverage. These factors will often favor the use of implant-supported overdentures and should be considered when contemplating treatment options. **CDA**

References / 1. Adell R, Eriksson B, Lekholm U, et al, Long-term follow-up study of osseointegrated implants in the treatment of totally edentulous jaws. *Int J Oral Maxillofac Implants* 5(4): 347-59, Winter 1990.

2. Jemt T, Lekholm U, Adell R, Osseointegrated implants in the treatment of partially edentulous patients: a preliminary study on 876 consecutively placed fixtures. *Int J Oral Maxillofac Implants* 4(3): 211-7, Fall 1989.

3. Chee WW, Cho GC, Donovan TE, Restoration of an anterior edentulous space. *J Calif Dent Assoc* 25(5): 381-5, May 1977.

4. Chee WW, Donovan TE, Treatment planning and soft tissue management for optimal implant aesthetics. *Ann Acad Med Singapore* 24(1): 113-7, January 1995.

5. Chee WW, Cho GC, Achieving esthetics with removable partial dentures. *J Calif Dent Assoc* 18(1): 19-22, January 1990.

6. Breeding LC, Dixon DL, Prosthetic restoration of the anterior edentulous space. *J Prosthet Dent* 67(2): 144-8, February 1992.

7. Mericske-Stern R, Treatment outcomes with implant-supported overdentures: clinical considerations. *J Prosthet Dent* 79(1): 66-73, January 1998.

8. Burns DR, Unger JW, Elswick RK, et al, Prospective clinical evaluation of mandibular



To Extract or Not to Extract? Factors That Affect Individual Tooth Prognosis

NIKITAS MORDOHAJ, DDS; MAMALY RESHAD, BDS, MSC; AND SAJID A. JIVRAJ, DDS, MSED

ABSTRACT

A dentist evaluates a natural tooth for its quality of health. Once this is accomplished, the clinician obtains an estimate of longevity and decides whether to extract or to treat and maintain the tooth. There often are questions and doubts involved in the decision-making process in regard to the prognosis of an individual tooth. Unfortunately in dentistry, as in all biologic sciences, there are no straightforward answers to questions.

This article will look at the literature in this area to help the practitioner in the decision-making process with regard to the compromised tooth. The article will concentrate on the single tooth or implant restoration. Other factors, such as the strategic value of a tooth and financial limitations in relation to long-term prognosis, will also be discussed.

Periodontally involved teeth receive multiple therapeutic procedures to arrest the disease and hopefully gain some attachment. Nonsurgical and surgical endodontic therapy is performed on teeth with necrotic pulps to seal the tooth or re-seal the “already sealed” root canal. On occasion, a given tooth may require both periodontal and endodontic procedures followed by restoration to form and function. Today, implant dentistry has modified the treatment planning process; questionable teeth may be extracted more frequently in favor of implant placement. Heroic attempts should be discouraged when the prognosis is poor, or failure of treatment

Authors / Nikitas Mordohai, DDS, and Mamaly Reshad, BDS, MSc, are residents in advanced prosthodontics at the University of Southern California School of Dentistry.



Guest Editor / Sajid A. Jivraj, DDS, MSED, is chairman of the Section of Fixed Prosthodontics and Operative Dentistry at the USC School of Dentistry. He also maintains a private practice limited to prosthodontics in Burbank, Calif.



may result in inadequate bone for implant placement. Considerable thought has to be given to prognosis from both a periodontal and an endodontic perspective. Therapeutic decisions need to be made based on this prognosis so that success in the long term can be achieved.

Prognosis of Periodontally Involved Teeth

Attaining an accurate prognosis of periodontally involved teeth is problematic. Hirschfeld and Wasserman re-examined more than 15,000 teeth in 600 patients with advanced periodontitis, at least 15 years after receiving treatment. The patients were generally well motivated in their personal and professional dental care. They also had similar periodontal involvement at the onset and received the same treatment. However, the patients differed markedly in post-treatment course, with tooth loss ranging from 0 to 23 teeth per patient.¹ In other words, it is almost impossible to predict the chance of survival of a periodontally compromised tooth.

In an attempt to establish clinical parameters that would lead to consistently correct prognoses, McGuire, McGuire and Nunn published a series of papers. All articles were based on 100 patients with 2,509 teeth under maintenance care for up to 15 years. It became obvious that "projections relying on the commonly taught clinical parameters were ineffective in predicting any outcome other than good."² Although the regression model formulated predicted accurately 81 percent of the time, its accuracy dropped to approximately 40 percent when applied to teeth with an initial prognosis of less than good.³ The same applies to the Interleukin-1 (IL-1) status of the patient, where only little correlation existed between clinical pre-

sentation of the tooth (initial prognosis) and genotype status.⁴ McGuire and Nunn observed that substantially greater percentages of teeth lost had a poor or worse prognosis than surviving teeth. But the disturbing observation was that there was great variability in survival time for teeth lost. For example, teeth lost with an initial prognosis of good had a survival range of four months to 12 years. Clearly, initial prognosis did not adequately predict

Patients who
smoked or
were positive
for IL-1
had a three-fold
increased risk
of losing their teeth.

tooth survival and especially for posterior teeth "projections were no more predictable than a coin toss."^{2,5}

On the other hand, there is evidence to support the efficacy of some clinical criteria in deciding whether to extract or maintain a tooth. Increasing probing depth, furcation involvement, mobility, percent of bone loss, having a parafunctional habit and not wearing an occlusal splint, and smoking resulted in an increased risk of tooth loss.⁵ Lang et al. found a highly significant relationship between increasing probing depth and increasing bleeding on probing incidence, and a highly significant relationship between increasing bleeding on probing and loss of probing attachment. Specifically, the absence of bleeding on probing showed an almost a zero percent risk for periodontal breakdown, while pockets that

constantly bled during follow-up appointments had a 30 percent risk for losing probing attachment. Although this number is still low, bleeding on probing still represents the most reliable clinical predictor for disease "activity" during periodontal maintenance.⁶ Wasserman et al. confirmed the limited importance of bleeding on probing. Patients with periodontal breakdown had gingival inflammation more often than patients without breakdown. However, the teeth with the most inflammation did not necessarily correspond with the teeth with the most severe breakdown.⁷

The smoking habit and the IL-1 genotype of the patients seemed useful in predicting future risk for disease progress. Patients who smoked or were positive for IL-1 had a three-fold increased risk of losing their teeth. Patients who were IL-1 positive and heavy smokers were nearly eight times more likely to lose teeth.⁴

Success Rates of Periodontal Therapy

The results of most studies on the effectiveness of periodontal therapy are encouraging. Hirschfeld and Wasserman found that 7.1 percent of the teeth were lost for periodontal reasons. Fifty percent of the patients did not lose any teeth over a period of 22 years.¹ McFall, in a duplicate study, had very similar results.⁸ Becker et al. showed comparable failure rates. When the teeth with an initial hopeless prognosis were excluded, the failure rate dropped to half (2.94 percent).⁹

Even the tooth type has been shown to be a factor in the survival of the tooth.^{1,8,9} The tooth loss pattern was almost identical in Hirschfeld, Wasserman and McFall's studies. Maxillary molars are the teeth most likely to be lost, followed closely by mandibular molars. The maxillary

and mandibular canines were the teeth most resistant to periodontal breakdown.^{1,8,9}

McGuire concluded it is easier to predict the prognosis for single-rooted teeth.² Most studies seem to agree that anterior teeth respond better to periodontal treatment and are less likely to be lost due to periodontal reasons. None of the canines were lost in a well-maintained population after 22 years of follow up.¹ Maxillary molars on the other hand, had the worst prognosis.^{1,8} Ramfjord et al. found that the response of anterior teeth to periodontal treatment was marginally better than posterior teeth. The poorest results occurred for the maxillary bicuspid and molars, which may in part be related to furcation involvement and the time of the disease onset.¹⁰ In patients with mild periodontitis, the molar teeth were four times more likely to be affected than all other teeth combined.⁷ In patients with more advanced disease, 85 percent of the molar teeth presented with severe destruction.⁷ It follows that molars are "problem teeth" and the efficacy of different types of treatment must be explored.

Success Rates of Surgical and Nonsurgical Therapy on Molars

In the treatment of molar teeth, there are various aspects that have to be investigated in order to evaluate the effectiveness of therapy. Teeth with and without furcation involvement have to be studied separately. Additionally, there are different therapeutic approaches for furcated molars. The treatment modalities include either preservation of the furca and strict maintenance or elimination of it by root amputation and hemisection.

Absence of furcation involvement. The treatment outcome even in the absence of furcation involvement

is problematic. However, the results are far more favorable compared to teeth with destruction in the furca. Sixty-four percent of nonfurcated teeth with a questionable prognosis were lost over a course of 19 years.⁸ When 323 molar teeth without furca invasion were followed for 6.5 years, 78 percent remained unchanged while the remaining 22 percent developed a furcation problem.⁹

In patients with mild periodontitis, the molar teeth were four times more likely to be affected than all other teeth combined.⁷

Presence of furcation involvement without root resection or amputation. Wang et al. concluded that in the presence of furcation involvement, teeth were twice as likely to be lost.¹¹ Kalkwarf et al. observed that furcation sites tended to lose probing attachment levels regardless of the type of therapy provided. This may be a result of the inability to adequately instrument these areas during therapy.¹²

Without any root resection or hemisection procedure performed, Hirschfeld and Wasserman reported loss of nearly one-third of the teeth originally diagnosed as having furcation invasion.¹ McFall found that more than half of furca-involved teeth were lost when followed from 15 to 29 years.⁸

On the contrary, Ross and Thompson reported acceptable results

with nonsurgical intervention of maxillary molars with furcation involvement. After five to 24 years, 88 percent of the teeth were still functioning comfortably. However, the significance of these results is limited when one considers that an additional 11 percent showed increased bone loss and that the diagnosis of all furcations was done solely on radiographs.¹³ Becker et al. published very similar results with the status of 86 percent of furcated molars remaining stable. Their conclusion was that teeth with moderate furcation involvement can be treated successfully and maintained effectively for prolonged periods.⁹

Furcation-involved teeth receiving root resection or amputation. Unfortunately, most studies of surgical intervention with root resection or hemisection do not present very promising results either. Langer et al. evaluated 100 patients receiving root resection therapy at least 10 years prior to the study. Thirty-eight percent of these teeth failed, the majority occurring between the fifth and seventh year. Mandibular molars failed at a 2-to-1 ratio compared to maxillary molars. The latter failed primarily because of progressive periodontal disease, while mandibular molars succumbed most frequently to root fractures.¹⁴ Blomlöf et al. reported a very similar success rate of 68 percent at 10 years. Smokers seemed to have a three-fold risk compared to nonsmokers.¹⁵

A study that illustrated more promising results, was conducted by Carnevale et al. They examined 488 hemisected or root resected teeth. The possible failure mode could have been periodontal, endodontic or restorative. The failure rate was 5.7 percent and only 3.7 percent of all the teeth had to be extracted. The highest cause of failure was dental caries and root fractures, but not peri-

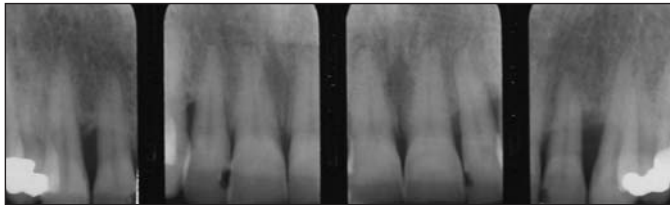


Figure 1. Status before periodontal treatment reveals mild to moderate involvement of the incisors.

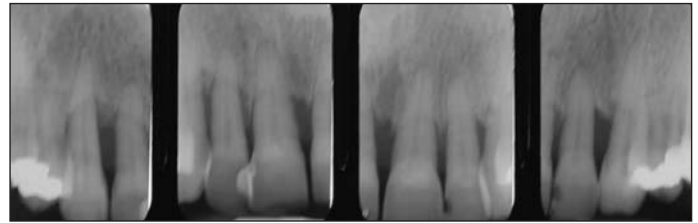


Figure 2. Three-year postop evidence of advanced periodontal destruction.

odontal disease. However, since this was a retrospective study, the number of furcated teeth that were initially extracted was not reported, and thus conclusions about the efficacy of surgical treatment of the furcated teeth should be made with extreme caution. The authors explained the higher success rates compared to other studies by the fact that resection therapy is very technique sensitive and proper case selection and restorative expertise are essential.¹⁶

Importance of Regular Maintenance

One aspect that all authors emphasize is the necessity for frequent recall appointments. The high success rates of Carnevale et al. are coupled with a three-month recall for 95 percent of his patients.¹⁶ A frequency of three to four appointments per year is advocated for the periodontally involved patients.^{1,2,8,9}

Achieving a proper maintenance program is not an easy task. Although recall appointments were sent every three to four months, patients attended every 5.2 months. Additionally, by the seventh year after treatment, there was a 22.1 percent dropout rate.⁹

Becker et al. reported that in a well-maintained population after 6.5 years, the annual tooth loss was 0.11 teeth per patient.⁹ The authors also examined another group of patients who did not return for recall for five years. Receiving treatment without maintenance had a negligible effect on reducing probing depths, and 25 percent of shallow pock-

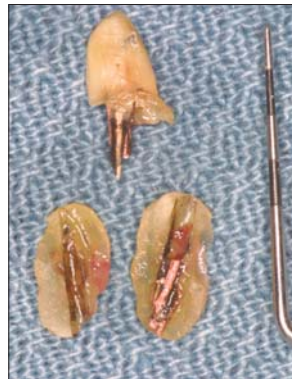

Figure 3. Horizontal and vertical root fractures of mandibular lateral incisor that was endodontically treated and restored with a cast dowel.

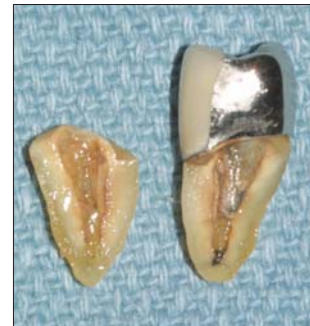

Figure 4. Maxillary first bicuspid are also prone to vertical fractures, especially if restored with wide diameter-dowels.

ets became deeper. There was a worsening of the furcation areas and statistically significant bone loss. Finally, the mean annual tooth loss doubled, reaching 0.22 teeth per patient.¹⁷

Conclusion on Periodontally Involved Teeth

It is evident that with the tools available today, accurate prognosis of periodontally involved teeth is unreliable. There are some guidelines that have prognosticating value, but they should be used with caution. Survival rates of anterior teeth exceed that of posterior teeth. It follows that anterior teeth can be maintained with lower risk. However, in rare circumstances, even teeth with excellent periodontal status show rapid degradation (**Figures 1, 2**). It is the multifactorial nature of the disease that makes prognosis and sometimes preservation of the teeth unpredictable.

Success Rates of Nonsurgical Endodontic Therapy

When a tooth is fractured, grossly carious or traumatized, the choice for a patient may be either endodontic therapy or loss of the tooth. It is important for the patient and the dental practitioner to be able to decide on a course of treatment through knowledge of potential success of various treatment modalities.

In a classical study on rats, Kakehashi et al. showed that in the absence of bacteria, complete healing of exposed dental pulps occurred.¹⁸ Sjogren et al. showed that when there was a periapical lesion present, endodontic success rates dropped by at least 10 percent.¹⁹ They also showed that an initial negative culture resulted in a 94 percent endodontic success rate, while an initial positive culture resulted in significantly reduced success rates (68 percent).²⁰ Fouad et al. demonstrated that "in cases with pre-

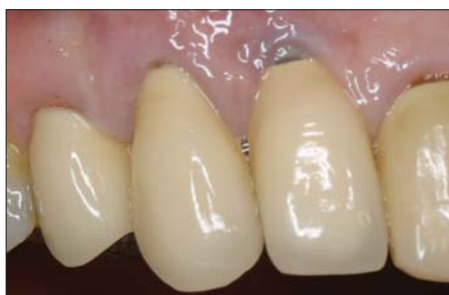

Figure 5. Implant-supported crown No. 7 that presents with esthetic problems. It is too long and metal display is evident in the cervical area.

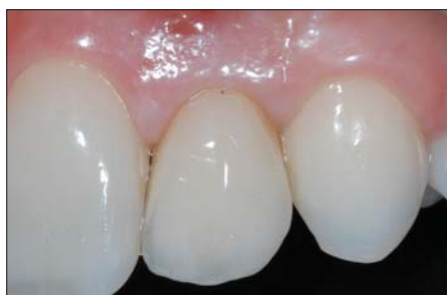

Figure 6. Harmonious esthetics can be achieved with implant restorations in region of tooth No. 10.

operative periradicular lesions, a history of diabetes was associated with a significantly reduced outcome."²¹ The data suggests that patients, who are diabetic and have an infected root canal, may have a significantly reduced chance of healing from an endodontic infection.

Eriksen et al. showed that endodontic specialists achieve higher success rates when compared to general practitioners. They also showed that endodontic success rates varied between 54 percent and 94 percent.²² In an investigation of nearly 2,500 teeth, Jonkinen et al. showed that success rates for endodontic therapy may be as low as 53 percent.²³ However in this study, the protocol for endodontic therapy differed from what is currently accepted as the norm. This may have had a negative influence on the success rates.

The real cause for confusion in survival studies seems to be the way in which the term "success" is defined. If a study has strict criteria for success, the results are negatively affected. On the other hand, if the criteria are less strict, the success rates may be positively affected.

The reporting of success rates in endodontic literature can be confused by the definition of "success/failure,"

the time period that the outcome was measured over, the type of endodontic procedure and the unit of measurement.

Much of the literature cited success rates are dependent on resolution of the periodontal ligament space with radiographic findings alone and clinical symptoms are not considered.²⁴⁻²⁶ Furthermore, study periods are often not adequate to allow classification of teeth displaying a reduction in periapical radiolucency but incomplete radiographic resolution, success rates from the longest period of follow up are extrapolated to that of the mean period, measurement of success are based on roots rather than teeth or have not included teeth extracted.^{24,27}

Friedman and Mor in 2004 defined success as root canal treatment that "has healed" or "is healing." They also proposed a new classification: "functional retention." Functional retention is the sum of the healed and the healing sites. They also suggest that functional retention includes a tooth with a normal clinical presentation, where radiolucency is present or absent, newly emerged or persisting.²⁸ In the opinion of the authors, although functional retention may result in higher apparent success rates, it may not lead to a predictable endodontic outcome.

Functional retention is a loose criterion for assessment of endodontic success and may mislead the reader into believing that success rates are actually higher than they really are.

Success Rates of Surgical Endodontic Therapy

Friedman and Mor pooled data from selected studies and showed that the chance of success ranged from 37 percent to 85 percent, with an average of 70 percent. The chance of functionality for surgical endodontic procedures was 86 percent to 92 percent.²⁸ Again, functionality increases the numerical value for success rate of surgical endodontics. But one needs to decide whether a functional tooth will result in a predictable outcome.

Restorability of Endodontically Treated Teeth

Another important issue is the restorability of endodontically treated teeth. Even if a tooth has been successfully treated with endodontics, one still needs to consider the restoration of the tooth. Goodacre et al., after reviewing 12 studies with 2,784 teeth and a six-year follow-up, 12 percent of teeth with dowels had complications.²⁹ Many of these complications may lead to tooth loss (Figures 3, 4). So, the practitioner needs to objectively assess the restorability of each endodontically treated tooth prior to commencement of treatment. The predictability of the treatment provided will be of benefit both to the patient and dentist.

Success Rates of Dental Implants

In an attempt to objectively quantify success with regard to dental implants and their restorations, many criteria have been defined. The implants should have a minimum of one year of loading, as most implant failures are detected in

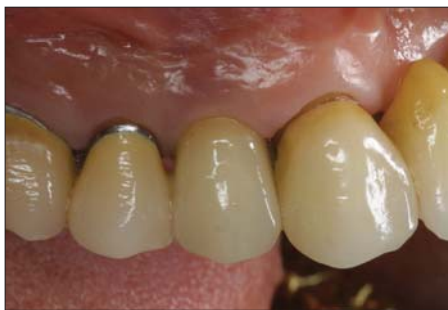

Figure 7. Single crown on an implant replacing No. 5, seven years postop.

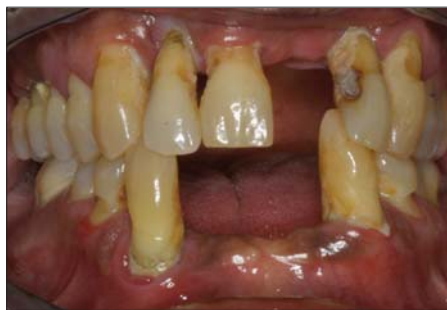

Figure 8. Poor oral hygiene habits can be detrimental, regardless of the level of treatment provided. This can be an overriding factor when treatment planning.

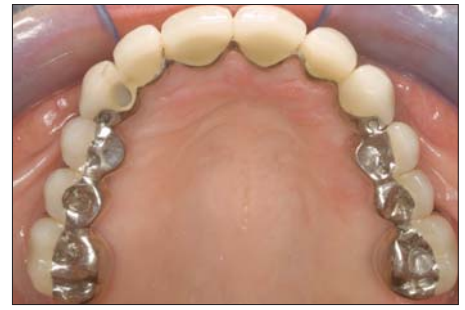

Figure 9. Cross-arch splinting reconstruction due to periodontal disease.

the first year of service.^{30,31} Implant failures should also be defined. It is suggested that if an implant cannot be used as support for prosthetic reconstruction, it should be labeled a "sleeping implant." These are labeled surviving implants at best, as they are not usable.³² Lindh et al. suggested these should really be classed as failures. If sleeping implants are osseointegrated, they should be regarded as "functional failures" because they are unrestorable.³²

Smith and Zarb have also suggested that the esthetic aspect of the implant position should also be incorporated as factors for a successful result.³³ Goodacre et al. showed that 47 out of 493 crowns/prosthesis produced aesthetic problems. They found that esthetic failures had a mean of 10 percent³⁰ (Figures 5, 6).

Gibbard and Zarb stated that "Long-term success for multiple splinted implants cannot be extrapolated to single implants."³⁴ In a meta-analysis of 66 studies over 10 years, Lindh et al. included 2,686 dental implants, and evaluated 570 single crowns and 2,116 implant fixed partial dentures in partially edentulous jaws. "Although the cumulative survival rate will decrease if 'sleeping implants' are considered as failed, the maximum difference is only 3.7 percent." Implant survival under

load after six to seven years was 93.6 percent for fixed partial dentures and 97.5 percent for single crowns²⁸ (Figure 7). The data from the Lindh et al. study suggests that implants and their restorations work extremely predictably for single teeth or fixed partial dentures. It also shows that even with strict inclusion criterion these restorations have excellent success rates.³²

Discussion

Unfortunately, there are no rules or formulas in dentistry that provide straightforward answers. The practitioner needs to use the knowledge from the literature along with common sense to derive a treatment plan. The picture is further complicated by a multitude of local, systemic and even psychological factors. The patient's medical conditions, the general condition of the oral environment and certainly the patient's motivation toward the treatment will influence the overall success (Figure 8). Thus, the actual longevity of a specific treatment modality cannot be applied to all patients indiscriminately.

Considering all these parameters, the clinician is often faced with a dilemma when deciding whether or not to extract a tooth with a poor prognosis. Traditional wisdom was based upon the concept of trying to

save the tooth by all means necessary. However, with the inception of dental implants, a completely new avenue has been opened in the treatment planning process. This has created a new topic for debate within the profession. There appears to be two schools of thought. One advocates the traditional approach while the other has adopted a more aggressive approach with treatment planning, and prefers to extract and replace a compromised tooth with a dental implant and restoration.

It is imperative to understand that each therapeutic modality has an inherent biological cost. Therefore, a risk analysis should be initiated prior to any definitive decisions. In the authors' opinion, a very stringent approach is required during this analysis. A treatment with a poor risk-to-benefit ratio has a greater probability of biological consequences. In treatment planning DeVan's statement should always be a cornerstone in the dentist's mind, "our goal should be the perpetual preservation of what remains rather than the meticulous restoration of what is missing."³⁵

Nyman and Lindhe have shown excellent results with the prosthetic rehabilitation of patients with advanced periodontal disease with very few prosthetic complications.³⁶ Figure 9 illus-

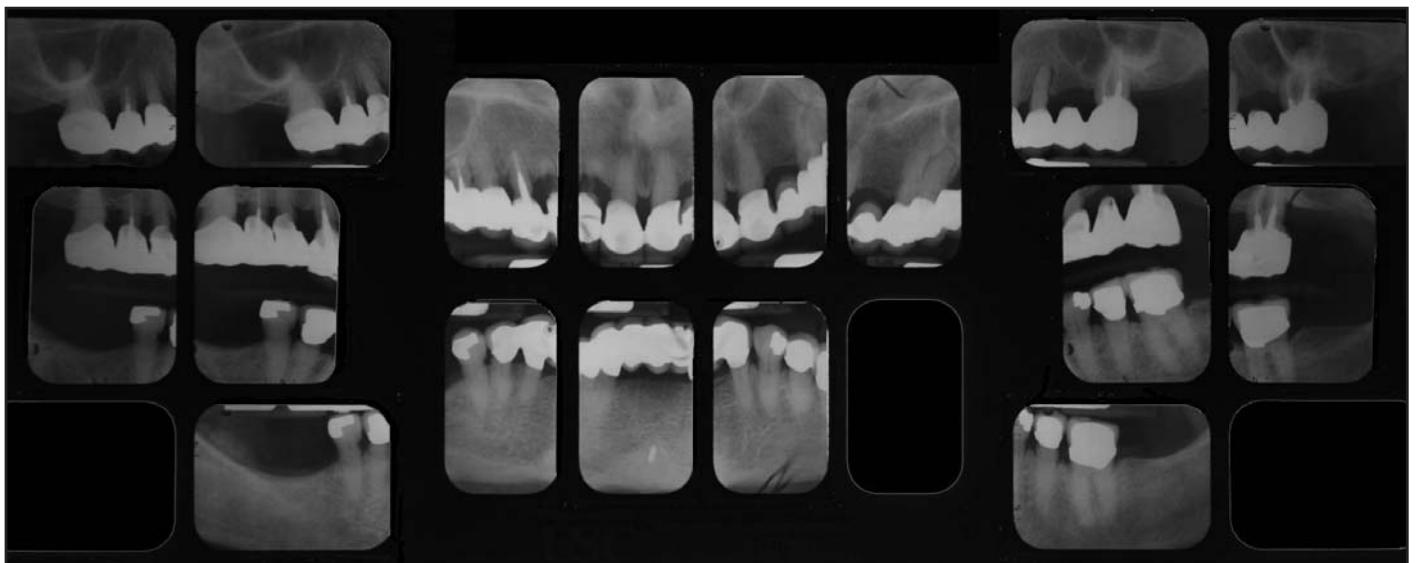


Figure 10. Full-mouth radiographs reveal caries on teeth Nos. 7 and 12, and very small roots.

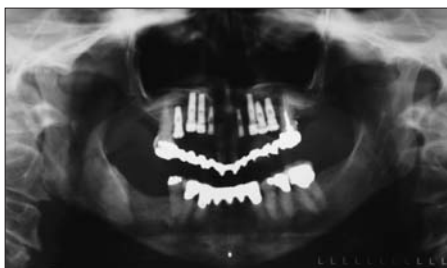

Figure 11. Implants were placed. The central incisors and first molars support a metal-reinforced fixed provisional restoration.

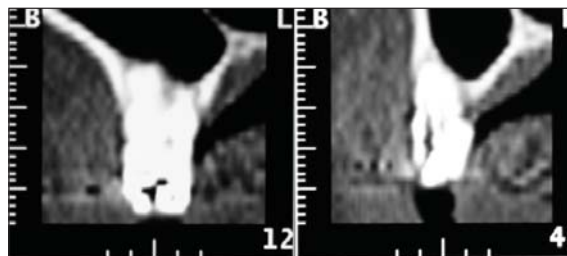


Figure 12. CT scan cuts of right and left first molar areas showing insufficient bone volume to house implants.

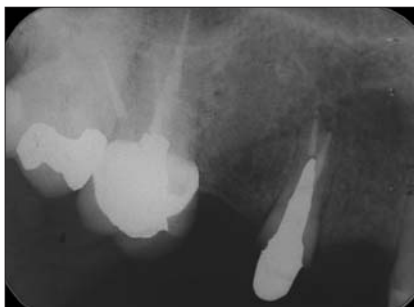


Figure 13. Tooth No. 5 has a large diameter post, periapical radiolucency, and needs a new crown.

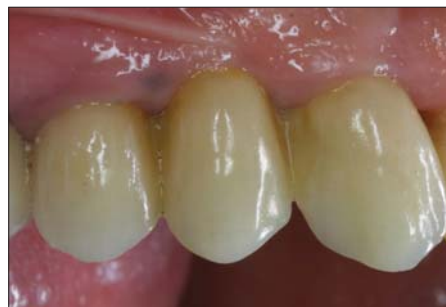

Figure 14. Implant-supported fixed partial denture on implants Nos. 4 and 6.

trates a patient who received full-mouth reconstruction in the maxilla due to moderate periodontal disease. After 25 years, the osseous support did not show significant changes with regular periodontal maintenance (**Figure 10**). Nevertheless, the patient's medical status changed and the salivary flow decreased significantly. The result was caries development on two abutment teeth. Considering the medical history, along with the success rates of different treatment modalities, it was decided to extract most of the maxillary teeth and place implants (**Figure 11**). Under no circumstances can the previous peri-

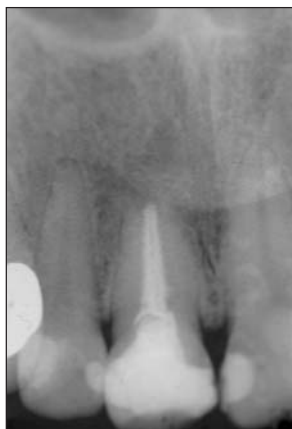

Figure 15. Failing endodontic therapy.

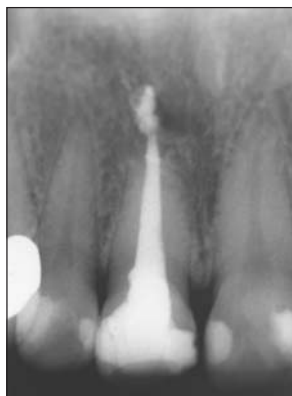

Figure 16. The endodontist decided to perform apical surgery and retrograde root filling.

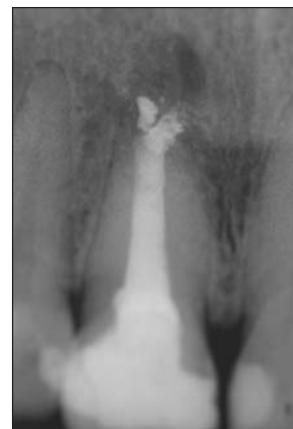

Figure 17. Second apical surgery and retrograde root filling.

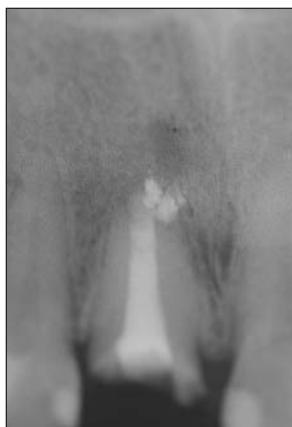


Figure 18. Third apical surgery and retrograde root filling. Despite the endodontist's effort, the tooth was still symptomatic.

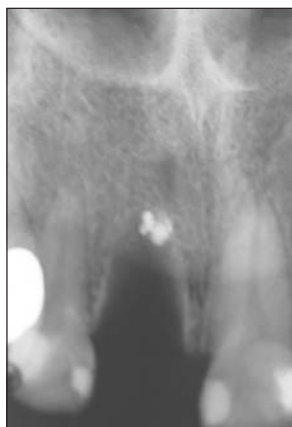

Figure 19. After the third surgery failed, the tooth was extracted. Remnants of the retrograde root filling can be observed on the radiograph.

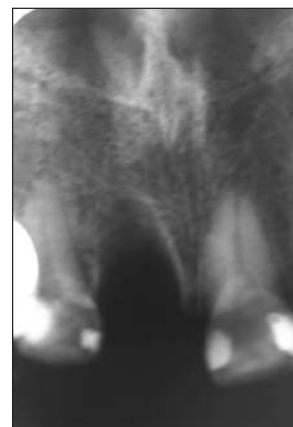

Figure 20. A fifth surgical procedure was necessary to remove the remnants.

odontal-prosthetic rehabilitation be considered a failure after 25 years of survival. An implant-supported restoration was chosen over a tooth-borne cross-arch splint. This decision was based on the obvious risk associated with splinting numerous teeth in a medically compromised patient.

The strategic value of the tooth must also be assessed. In the patient shown in **Figure 11**, the most distal molars were maintained. Extractions would have resulted in sinus lifting procedures, which the patient wished to avoid (**Figure 12**). Although the teeth had a guarded prognosis, their value as two additional occluding units

contradicted their removal. **Figure 13** shows tooth No. 5 has a large cast dowel and needs endodontic retreatment and a new crown. Implants are planned for the mesial and distal edentulous sites, while the existing teeth on the mesial and distal do not need restorations or replacement of restorations. Due to the risk involved and the low strategic value of the tooth, a three-unit implant-supported fixed partial denture was fabricated (**Figure 14**). It can be deduced that, teeth with higher strategic value will be amenable to more extensive procedures than teeth in less important positions in the arch.

Clinical Recommendations and Conclusions

Implant placement and restoration is not a technically demanding procedure.^{37,38} From the results available today, which are based on follow-up studies, it seems tooth replacement with dental implants is more predictable than surgical periodontal and endodontic techniques (**Figures 15-20**). This, however, should not automatically preclude these therapeutic modalities and lead to extraction of the affected teeth. It does justify though, a relatively more aggressive approach especially in younger patients where a significantly long-term prognosis is required.

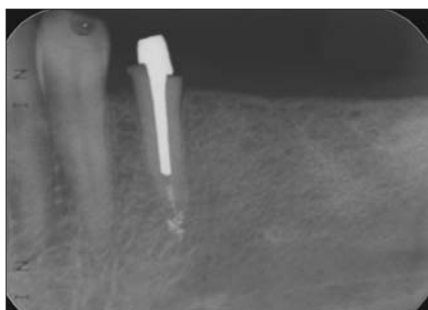


Figure 21. The root length was favorable and a narrow diameter for the dowel was intentionally maintained.

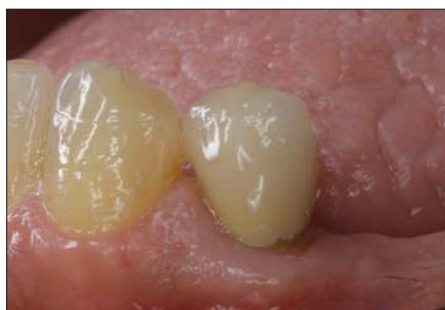

Figure 22. This tooth received root canal therapy, crown lengthening, cast dowel and core and a new crown.

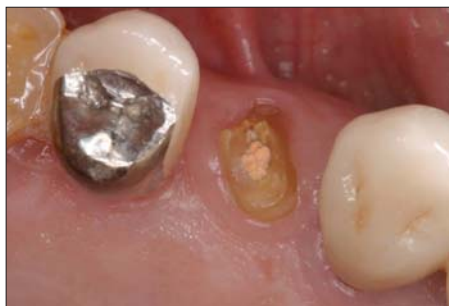

Figure 23. This tooth requires endodontic retreatment, crown lengthening, dowel and core and a crown. It was decided to extract the tooth as the patient was a bruxer and the root had unfavorable anatomy.

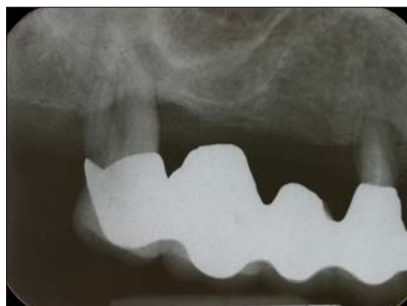

Figure 24. Advanced periodontal disease. The treatment of choice was extraction and implant placement.

what remains" should be extended to the precious osseous structure of the ridges.³³

Today, the clinician is blessed with an additional treatment modality. Incorporating dental implants into our treatment plans will only serve to improve the predictability and quality of care provided to our patients. **CDA**

References / 1. Hirschfeld A, Wasserman B, A long-term survey of tooth loss in 600 treated periodontal patients. *J Periodontol* 49(5): 225-37, 1978.

2. McGuire MK, Prognosis versus actual outcome: A long-term survey of 100 treated periodontal patients under maintenance care. *J Periodontol* 62(1): 51-8, 1991.

3. McGuire MK, Nunn ME, Prognosis versus actual outcome. II. The effectiveness of clinical parameters in developing an accurate prognosis. *J Periodontol* 67(7): 658-65, 1996.

4. McGuire MK, Nunn ME, Prognosis versus actual outcome. IV. The effectiveness of clinical parameters and IL-1 genotype in accurately predicting prognoses and tooth survival. *J Periodontol* 70(1): 49-56, 1999.

5. McGuire MK, Nunn ME, Prognosis versus actual outcome. III. The effectiveness of clinical parameters in accurately predicting tooth survival. *J Periodontol* 67(7): 666-74, 1996.

6. Lang NP, Joss A, et al, Bleeding on probing – A predictor for the progression of periodontal disease? *J Clin Periodontol* 13(6): 590-6, 1986.

7. Wasserman BH, Thompson RH Jr, et al, Relationship of occlusion and periodontal disease Part II. Periodontal status of the study population. *J Periodontol* 42(6): 371-8, 1971.

8. McFall WT Jr, Tooth loss in 100 treated patients with periodontal disease. A long-term study. *J Periodontol* 53(9): 539-49, 1982.

9. Becker W, Berg L, Becker BE, The long-term evaluation of periodontal treatment and maintenance in 95 patients. *Int J Periodontics Restorative Dent* 4(2): 54-71, 1984.

10. Ramfjord SP, Knowles JW, et al, Results of periodontal therapy related to tooth type. *J Periodontol* 51(5): 270-3, 1980.

11. Wang H-L, Burget FG, et al, The influence of molar furcation involvement and mobility on future clinical periodontal attachment loss. *J Periodontol* 65(1): 25-29, 1994.

12. Kalkwarf KL, Kaldahl WB, Patil KD, Evaluation of furcation region response to periodontal therapy. *J Periodontol* 59(12): 794-804, 1988.

13. Ross IF, Thompson RH, Long-term study of root retention in the treatment of maxillary molars with furcation involvement. *J Periodontol* 49(5): 238-73, 1978.

14. Langer B, Stein SD, Wagenberg B, An evaluation of root resections. A 10-year study. *J Periodontol* 52(12): 719-22, 1981.

15. Blomlöf L, Jansson L, et al, Prognosis and mortality of root-resected molars. *Int J Periodontics Restorative Dent* 17(2):190-201, 1997.

16. Carnevale G, Di Febo G, et al, A retrospective analysis of the periodontal-prosthetic treatment of molars with interradicular lesions. *Int J Periodontics Restorative Dent* 11(3): 189-205, 1991.

17. Becker W, Becker BE, Berg LE, Periodontal

One needs to decide on the most predictable strategy for restoring a severely broken down tooth. This may involve the combination of endodontic, periodontal and restorative procedures in order to save a tooth (Figures 21, 22). On the other hand, what has been considered successful prior to the inception of dental implants might not be acceptable today. If the tooth has minimal coronal tooth tissue remaining with unfavorable root structure, or if multiple procedures need to be performed, one is justified in extracting the tooth in favor of a dental implant (Figure 23). Multiple procedures, even if independently low risk, significantly increase the risk of failure. On the other hand, removal of all teeth that do not receive

a good prognosis is extremely aggressive and contraindicated.

Heroic attempts to maintain teeth with poor prognosis should be eradicated. Such attempts increase the risk for failure, as well as the cost for the patient in the long run. They may also jeopardize future treatment outcomes. For example, as periodontal destruction progresses, the risk of insufficient bone volume for implant placement increases. Historically, the teeth shown in Figure 24 would be maintained until they exfoliated from the patient's mouth. A more aggressive approach nowadays will save the patient from the high morbidity and lower predictability of bone grafting procedures. The authors believe that the interpretation of the "...preservation of



treatment without maintenance. A retrospective study in 44 patients. *J Periodontol* 55(9): 505-9, 1984.

18. Kakehashi S, Stanley HR, Fitzgerald RJ, The effects of surgical exposures of dental pulps in germfree and conventional laboratory rats. *J South Calif Dent Assoc* 34(9): 449-51, 1966.

19. Sjogren U, Hagglund B, et al, Factors affecting the long-term results of endodontic treatment. *J Endod* 16(10): 498-504, 1990.

20. Sjogren U, Figdor D, et al, Influence of infection at the time of root filling on the outcome of endodontic treatment of teeth with apical periodontitis. *Int Endod J* 30(5): 297-306, 1997.

21. Fouad AF, Diabetes mellitus as a modulating factor of endodontic infections. *J Dent Educ* 67(4): 459-67, 2003.

22. Eriksen HM, Endodontology-epidemiologic considerations. *Endod Dent Traumatol* 7(5): 189-95, 1991.

23. Jokinen MA, Kotilainen R, et al, Clinical and radiographic study of pulpectomy and root canal therapy. *Scand J Dent Res* 86(5): 366-73, 1978.

24. Morse D, Esposito JV, Pike C, Furst ML, A radiographic evaluation of the periapical status of teeth treated by the gutta-percha-eucapercha method: a one-year follow-up study of 458 root

canals- Part III. *Oral Surg* 1983; 56: 190-197.

25. Seltzer S, Bender IB, Factors affecting successful repair after root canal therapy. *J Am Dent Assoc* 1963; 67: 651-662.

26. Heling I, Bialla-Shenkman S, Turetzky A, Horwitz J, Sela J, The outcome of teeth with periapical periodontitis treated with nonsurgical endodontic treatment: a computerized morphometric study. *Quintessence Int* 2001; 32: 397-400.

27. Sjogren U, Hagglund B, Sundqvist G, Wing K, Factors affecting the long-term results of endodontic treatment. *J Endod* 1990; 16: 498-504.

28. Friedman S, Mor C, The success of endodontic therapy—healing and functionality. *J Calif Dent Assoc* 32(6): 493-503, 2004.

29. Goodacre CJ, Bernal G, et al, Clinical complications in fixed prosthodontics. *J Prosthet Dent* 90(1): 31-41, 2003.

30. Goodacre CJ, Kan JY, Rungcharassaeng K, Clinical complications of osseointegrated implants. *J Prosthet Dent* 81(5): 537-52, 1999.

31. Goodacre CJ, Bernal G, et al, Clinical complications with implants and implant prosthesis. *J Prosthet Dent* 90(2): 121-32, 2003.

32. Lindh T, Gunne J, et al, A meta-analysis of implants in partial edentulism. *Clin Oral Implants Res* 9(2): 80-90, 1998.

33. Smith DE, Zarb GA, Criteria for success of osseointegrated endosseous implants. *J Prosthet Dent* 62(5):567-7, 1989.

34. Gibbard LL, Zarb G, A five-year prospective study of implant-supported single tooth replacements. *J Can Dent Assoc* 68(2): 110-6, 2002.

35. DeVan MM, The nature of the partial denture foundation: suggestions for its preservation. *J Prosthet Dent* 22:210-8, 1952.

36. Nyman S, Lindhe J, A longitudinal study of combined periodontal and prosthetic treatment of patients with advanced periodontal disease. *J Periodontol* 50(4): 163-9, 1979.

37. Bell FA, Cavazos EJ, et al, Four-year experience with the placement, restoration, and maintenance of dental implants by dental students. *Int J Oral Maxillofac Implants* 9(6): 725-31, 1994.

38. Cummings J, Arbree NS, Prosthodontic treatment of patients receiving implants by predoctoral students: five-year follow-up with the IMZ system. *J Prosthet Dent* 74(1): 56-9, 1995.

To request a printed copy of this article, please contact / Nikitas Mordohai, DDS, 73 Ermou St., Thessaloniki, 54623, Greece; e-mail: nmordohai@hotmail.com.



Issues and Considerations in Dental Implant Occlusion: What Do We Know, *and* What Do We Need To Find Out?

C.M. STANFORD, DDS, PHD

ABSTRACT

Implant dentistry continues to struggle with what are the appropriate occlusal concept(s) for implant-supported restorations. The biological and mechanical consequences of the loading environment leads to establishing and maintaining an implant interface in a wide variety of bone quality and quantity, implant and prosthesis designs. To the restorative dentist, the role of occlusion is more focused on extending the service life of the restoration and the connecting abutment(s) than protecting the osseous integration of the implant(s). This study reviews the relevant issues regarding implant occlusion along with implant and prosthesis design in order to provide optimal patient care.

The routine use of dental implants for dental restorations has revolutionized patient care. Endosseous-style implants have achieved high success in wide spread practice — a measure of the effectiveness of care — as a function of appreciation for surgical handling of tissues, site development, implant designs with a high level of strength, precision and design, along with treatment planning using restorative options that allow for stable occlusion and predictable esthetics.¹ From the start, it should be clearly understood by the clinician that there is little evidence for or against one or another occlusal scheme.² Many authors provide seem-



Author / C.M. Stanford, DDS, PhD, is the Centennial Fund Professor, Dows Institute for Dental Research and Department of Prosthodontics, University of Iowa in Iowa City, Iowa.

Acknowledgment / This investigation was supported in part by USPH NIH NCRR MO1 RR00050-43.



ingly rational recommendations with statements of fear related to loss of implant integration due to mastication when most evidence-based studies don't support this. Prudence in this area of uncertainty is to use commonly accepted occlusal concepts and practices as the profession moves forward to address the relative role of occlusion on biological and mechanical outcomes of care.

The question of occlusion and its role in the biological and mechanical stability of implant therapy has been an ongoing controversy. The purpose of this review was to assess the current state of what is known, and to provide guidance for future studies. The predictability of prosthetic options available with today's implant systems have been brought about primarily by the application of enhanced machining technologies that have lead to the ability of manufacturers to provide implant abutment components that do not rely on the mating of flat-to-flat surfaces (external hexes) and therefore, a variety of internal conical designs are now on the market.^{3,4} These designs allow the restorative dentist to position an abutment into the implant and be assured of a tight, predictable connection. In a recent review of the literature on implant complications, it is instructive to note that occlusion and the resultant loading, does influence, especially the service life of the restoration, but has apparently little role in causing outright implant loss.⁵

Studies and opinions have suggested various forms of occlusal modifications aimed at reducing axial and/or lateral loads to the dental prosthesis (Table 1). Distinctions should be made based on the biomechanical design of the implant system used, the number of implants involved, the design and fit of the prosthesis and the nature of the opposing dentition, deformation of the supporting bone or arch and the nature of the

Table 1

Common Practices for Management of Implant Occlusion*

Single tooth restorations

- Light "infra-occlusion" with sliding 8 µm shim stock on firm clench
- Reduced occlusal table dimensions
- MI contacts along long axis

Fixed partial denture and fixed complete dentures

- Canine protected or mutually protected occlusion (natural teeth as the opposing dentition). Anterior teeth disclude posterior teeth in eccentric movements, increased potential for cusp length
- Lingualized occlusion (complete denture as the opposing dentition). Maxillary lingual cusp in shallow mandibular central fossa, no mandibular buccal cusp contact

*Most of these are based on various opinions with little evidence to support the concepts.

bolus of food. During occlusal function, a true axial load almost never occurs relative to the implant long axis, but instead function occurs on various areas of the prosthesis with the development of complex bending moments within the restorative implant components (implant body, abutment, crown) and within the surrounding bone.^{6,7} If the clinician feels it is important to reduce axial forces to the prosthesis, reducing the buccal-lingual width of the occlusal table and reduction in the area of contact in maximum cusptation with increased cuspal inclines has been suggested.⁸ Kaukinen et al. evaluated the influence of cuspal angulation using a cusplless versus a 33-degree cuspal tooth form demonstrating greater breakage force with the inclined tooth form but a strong potential for wedging food action that increases force transmission, a result in agreement with an earlier study comparing different occlusal surface materials for the prosthesis.^{9,10} In the design of the prosthesis, the clinician needs to consider both the load induced by the food bolus and where this is delivered onto the prosthesis, relative to

the central axis of the implant(s) connection. The distance from this point of loading relative to the central axis develops a bending moment within the prosthesis and implant assembly which can greatly exceed the measured bite forces on the prosthesis without food being present.⁷ The complex biomechanical issues involved in various prosthesis designs are beyond the scope of this review, but the reader is directed to recent published reviews.^{7,11} As outlined by Taylor, the role of food as a bolus involved in changing the masticatory load both in magnitude and direction cannot be underestimated.¹²

Biological Factors related to Occlusion

When discussing implant occlusion, the clinician often asks about the danger in excessive occlusal load leading to loss of a dental implant. The early dental implant literature has various opinions suggesting that implant "overload" will lead to loss of integration.¹³⁻¹⁵ Part of the issue is what constitutes "overload" (magnitude, position, angle, etc.) and what may be considered overload at one site or with one implant design

may be within an acceptable range with another.¹⁶ Failure can also be defined as either overt loss of the implant or ongoing crestal bone loss. It is instructive to consider some of the literature that deals with how bone responds to loading since it is important to the long-term outcomes of care.

Various studies have addressed the issues of implant integration and "overload" by using animal models with exaggerated axial and lateral loading. Most of these studies have been performed with dental prosthesis placed in "supra-occlusal contact," however that is defined, and clinical and histological outcomes evaluated following various periods of loading.¹⁷⁻²⁰ It has also been suggested that overloading can lead to progressive crestal bone loss once integration has been achieved on machined surface implants.^{21,22} It should be emphasized there is still significant controversy about the additive role of plaque-induced inflammation around implants and loading that may interact to induce this crestal bone loss.²³ The literature does have one study suggesting a role of implant loss in supra-occlusion (axial and lateral shear force). Isidor et al. used a primate model and created one point supra-occlusal (not quantified) axial and lateral loading with and without oral hygiene.²⁴ It is interesting to note that short and narrow implants were used (3.5 x 8 mm length). This often-cited paper should be viewed with caution since only a few implants were actually lost and significant, but not measured, lateral forces were created on the implants. Interestingly, the authors noted that the sites, with a combination of excessive inflammation, i.e. cotton cord tied around the implants, and overload were needed together to induce implant loss. In a more recent study, Heitz-Mayfield et al. addressed this issue using rough-surfaced implants in the

mandible of dogs and started loading these six months after placement.²⁵ After eight months of supra-occlusal contact, axially and laterally, clinical, radiographic and histological assessment demonstrated no difference between the loaded and nonloaded control implants placed on the contralateral side. Interestingly, there was no difference in crestal bone loss around these loaded versus nonloaded one-stage implants. In another

There is still significant controversy about the additive role of plaque-induced inflammation around implants and loading that may interact to induce this crestal bone loss.²³

animal study, Gottfredsen et al. applied static continuous loads, e.g., orthodontic forces, to integrated implants placed in a dog mandible and observed no crestal bone loss but enhanced bone density on the laterally loaded implants after six months.²⁶⁻²⁸ Duyck et al. observed in a rabbit model with static versus dynamic loading to integrated machined surface implants no effect of continuous static loading over a two-week period. But crater-like defects around the crestal region of the dynamically loaded implants suggesting repeated loading (2502 cycles of 14.7 N loads) in this animal model could result in crestal bone loss.²⁹ This later study may provide some evidence that loads calculated to come close to the maximum strain for bone

can cause bone loss within this model and implant design; the application of the results to other situations is unclear. Obviously, no clinician would intentionally create these types of situations with patients, but it is interesting that the interface is capable of transferring significant loads to bone without a loss of the interface. This may be one reason for the safe application of implants for orthodontic anchorage.³⁰

Over the life span of the patient, an implant interface is maintained by an ongoing remodeling process at the interface. The interface is maintained through a dynamic process of growth (modeling) and the more complex remodeling processes involved in replacing the interface (remodeling).^{11,16} These processes, modulated by a process referred to as the adaptive capacity of bone by Stanford and Brand allows bone to withstand the errors inherent in clinical procedures (e.g., prosthesis misfit), while creating a biological interface supporting clinical loads over long periods of time.¹¹ High implant survival rates are observed for various anatomic regions of the oral cavity assuming primary stability is assured.³¹ This is especially critical in immediate loading protocols where at least rigid prosthetic stability is needed during the healing period. (See Gapski et al. for an in-depth review on immediate loading.)³² In the edentulous posterior maxilla, there is often a thin cortex and sparse cancellous bone ("Type IV bone" as described by Lekholm and Zarb³³) which may reduce initial stability for implants. For instance, with machined surfaced implants, the poor structural and architectural properties of bone in the posterior maxilla tends to lead to reduced survival rates, 65 percent to 85 percent.³⁴⁻³⁸ With changes in implant surface technology, especially rough surface topographies, there have been significant improvements in the survival of



implants in this high-risk site such that reasonable predictability (>90 percent) can be observed.³⁹⁻⁴³

Shear strains at an implant interface are created during any axial or lateral occlusion on a prosthesis. Shear is one of the variety of stress that results in strains (strain being a deformation in response to a stress) that occurs and appears to play a predominant role in creating motion at the implant interface.^{7,11} A role for implant surface topography, roughness being one component of this, is to diminish the effects of shear strains by altering bone remodeling along the interface. Multiple studies have observed that biomechanical measurements of the interfacial strength of an implant after healing depend on the surface roughness.⁴⁴⁻⁵² For instance, Wong et al. observed that the pull-out resistance of an implant was highly correlated with 2-D measurements (R_a) of surface roughness ($r^2 = 0.90$).⁴⁵ Interestingly, the same author observed only a modest correlation of "percent bone contact" with surface roughness ($r^2=0.56$), which suggests that histomorphometric, as well as radiographic, measurements alone are poor predictors of the biomechanical stability of an implant interface. Now, the microscopic surface roughness alone will not control shear strains at an interfacial surface. Control of interfacial shear strains can be achieved by combining macroscopic levels of implant design (e.g., screw thread profiles) with microscopic levels of surface topography, e.g., surface pitting. To this end, a repeated pattern of 5 μm diameter "pits" on a titanium surface provides an optimal surface topography.⁵³⁻⁵⁵ Each pit should have an average depth of 0.5 μm and a sharp edge profile that allows bone to establish a microscopically stable osseous "knob." When this microscopic architecture is combined with a

low-profile macroscopic screw pattern, the interfacial shear strains are reduced creating surface roughness on the order of $S_a = 1.5 \mu\text{m}$.⁵⁶ In evaluating this combination, Gotfredsen et al. formed these surface topographies by blasting of the bulk cpTi metal with TiO_2 to produce significantly higher removal torque values when compared to the conventional machined surfaces.⁵⁷ In a series of studies, Wennerberg et al. demonstrat-

Multiple studies
have observed that
biomechanical
measurements of the
interfacial strength
of an implant after
healing depend on
the surface
roughness.⁴⁴⁻⁵²

ed that implant surface topography prepared with TiO_2 blasting could create a uniform, reproducible surface roughness, which significantly increased removal torque.^{46-48,58,59}

Why is a combination of optimal surface topography and macroscopic architecture important and relevant to a discussion concerning occlusion? First, in certain areas, such as the posterior maxilla, cortical bone is often very thin, 400-600 μm , necessitating a trabecular surface on most of the implant. Indeed, recent studies by Schneider and Stanford have shown at the molecular level that differences in the microtopography of an implant surface can affect the expression of key osteogenic transcription fac-

tors, such as *Cbfa1* that will enhance osteogenesis directly on an implant surface, a process described as contact osteogenesis.^{43,60-62} Second, there will be initial modeling/remodeling response to a newly placed implant along with the establishment of a biological seal around the neck of the implant. This seal, or biological "length," is a combination of a 1 to 1.5 mm junctional epithelium and a 1.5 to 2 mm connective tissue region that is established above the alveolar crest.⁶³⁻⁶⁷ Given that cortical bone will resorb (model) to establish this biological length, and that this modeling behavior typically occurs to the level where the screw threads start and/or surface topography is roughened, an implant designed for use in Type IV bone e.g., posterior maxilla, should maintain the maximal amount of cortical bone for primary stability which will establish and maintain a supporting trabecular interface.

Occlusal loading of the natural dentition has an inherent feedback loop with the proprioceptive fibers of the periodontal ligament to protect the radicular dentin, cementum, periodontal ligament and alveolar bone from undue trauma during mastication. This is not the case with the oral implant interface. In fact, studies by Carr and Laney, demonstrated that edentulous patients are able to deliver five-fold greater loads to their implant born prostheses relative to edentulous patients with complete dentures.⁶⁸ This is probably due to an inability to maintain neuromensory fine distinction, i.e., shape, contours, etc., and differentiation of occlusal loads during mastication.⁶⁹ Interestingly, even though there isn't a periodontal ligament-like proprioception with dental implants, there is a relative increase in sensation and neural capacity in the region surrounding an implant prosthesis. This adaptation was referred to as, "osseoperception."⁶⁹

Osseoperception, suggests that bone can compensate though an enhanced periosteal conduction of spatial and positional information following loading, stress-mediated changes in cortical shape conveyed to neuronal cell membranes as a strain or deformation. In the periosteum, mechanoreceptors are sensitive to vibration frequencies (100-300 Hz) stimulated by cortical bone strains distributed across the cortical bone's surface when the mandible or maxilla deform. In turn, the periosteum can act as a biological "strain gauge" that may allow the patient to develop a spatial and object-shape acuity previously thought impossible.⁷⁰

Bone is a composite viscoelastic material, in which the high rate of rapid loading that occurs in typical mastication, in essence an impact load, increases the effective functional stiffness (E) of the implant interface. This functional increase in interfacial stiffness leads to changes in local material properties e.g., increasing bone mass, as well as changes in the orientation and connectivity of trabecular struts in cancellous bone.⁷¹ Changes in stiffness has a number of implications for how tissues perceive the load at the interface, and the type of functional response in bone density and assembly of trabeculae (architecture or connectivity). Bone cells within bone play a role as mechanotransducers of forces and communicate these changes to the overlying periosteum.⁷¹ Thus, the physical properties of the matrix, in addition to direct cellular communication and/or by cytokines, act as part of the relaying signal mechanism that can lead to new bone formation.

How do the material properties of bone on implant surfaces influence biological responses to loading? The surface mechanical "bonding" of bone to an implant surface controls shear strains at the interface though a com-

bination of macroscopic and microscopic architecture, e.g., roughness, of the titanium oxide layer. The capacity of bone to respond to the impact forces derived from occlusion with high load magnitudes and a high frequency but short duration, as described by Stanford and Brand suggests that local interfacial physical properties change in a viscoelastic manner.¹¹ Apparently, the interface can increase its local external modulus

The primary concern has now shifted to the durability and lifespan of the prosthesis. Maintenance issues with implant-supported prosthesis are strongly related to occlusal loading.⁵

of stiffness during load transfer at the osseous interface. This is, in part, one of the underlying basis of clinical devices used to measure bone stiffness on an implant as a relative measure of implant "integration."⁷²⁻⁷⁷

Mechanical Issues Related to Occlusion

From a clinician's perspective, one aspect that must be considered is the relationship between occlusion, loading and mechanical complications with the dental restoration. These complications due to occlusion and prosthesis loading range from accelerated wear such as chipping and fracture of porcelain, abrasion of acrylics, to overt fracture of implants. Over the last two decades,

implant designs have evolved to the point that concerns and issues with screw loosening have become rare. This may be one reason for the increasing popularity of cemented restorations in implant therapy. The primary concern has now shifted to the durability and lifespan of the prosthesis. Maintenance issues with implant-supported prosthesis are strongly related to occlusal loading.⁵ In a comprehensive review of multiple studies in the literature reporting on implant complications, Goodacre et al. reviewed clinical implant studies performed between 1981 and 2001 with a range of different implant designs and applications.⁵ It is interesting to note that out of this review, they noted that implant therapy has a range of complications such as surgical, implant loss, bone loss, issues with soft tissue, mechanical as well as esthetic and phonetic issues, with wide differences in outcomes. Mechanical complications were noted especially with overdenture therapy with loss of retention, 30 percent; relines, 19 percent; and attachment fracture, 14 percent, the most common. Of the variety of complications affecting implant-supported fixed partial dentures and crowns, the loss of veneering acrylic, 22 percent, or porcelain, 12 percent, was reported. Screw loosening was reported to be 4 to 6 percent while reports of fractured implants was quite low, <1 percent. Given the range of studies and the difficulty in making direct comparisons, this review illustrates the need to discuss with the patient that mechanical complications can occur, e.g., wear, veneer fractures, and that the prosthesis will need to be periodically replaced or repaired. Knowing that a prosthesis will need to be replaced at some point in the life span of the patient, it would be prudent that the clinician utilize a commonly available implant system (with the hope



that replacement parts are available in the future, although there is no U.S. Food and Drug Administration regulation that requires implant manufacturers to maintain supplies of implant components when a model goes off the market or a company is sold or goes out of business), and that the clinician provide specific information to the patient as to the implant product used, such as model, catalog numbers, contact information on one's business card. This will assist a clinician in the future by knowing exactly what product was originally used and avoids guessing as to what was used. Given this, it is important that the clinician evaluate any implant system to be used to determine the maintenance outcomes of the implants, the abutments as well as the prosthesis.³

Occlusal loads, especially off axis torsional loads can lead to loosening of abutments and prosthetic screws.^{78,79} With the external hex implant designs, manufacturers addressed the issue of screw loosening with the creation of enhanced clamping forces, or preload, though multiple redesigns of screw threads and screw composition, e.g., gold-based, and lubrication mechanisms in order to convert more of a delivered torque into clamping force or preload. With the introduction of friction interference, fit internal conical designs, internal tapers of 2 to 11 degrees, there has been a reduced incidence of screw loosening and mechanical complications.³ Use of one- or two-piece abutments fitted into a conical interface have been shown to be extremely stable and strong joint systems.^{80,81} With the development of this stable joint interface, treatment planning concepts are evolving where two implants can be used to replace three teeth, using a three-unit fixed partial denture, allowing increased prosthetic flexibility and reduced costs for the patient (Figures 1-8).^{82,83}

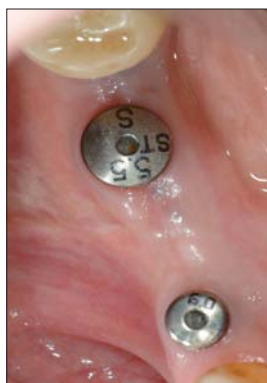

Figure 1. Patient presents with one-stage healing abutments in place six weeks following implant placement.

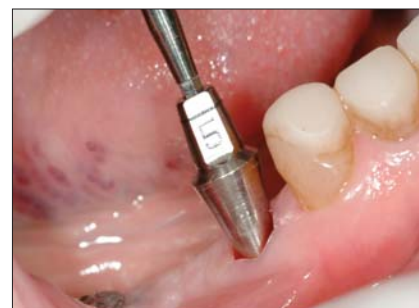

Figure 2. Healing abutments are removed and a solid prosthetic abutment placed in the area of first premolar (Direct Abutment, Astra Tech AB, Mölndal, Sweden).

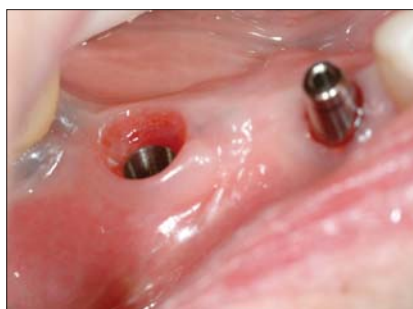

Figure 3. Healing abutment removed demonstrating gingival cuff above the exposed internal aspect of the implant body.

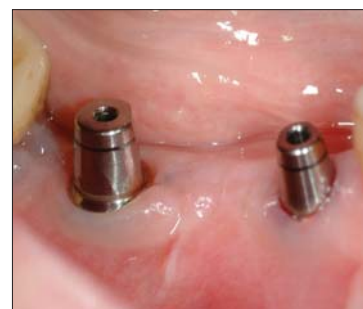

Figure 4. Both abutments in place.

Summary

Improving the understanding of occlusal loading on the outcomes of an implant restoration includes knowledge of multiple mechanical and biological factors making any generalization tenuous at best. This is probably one reason we still apply concepts of dentate occlusion to implant-supported restorations, while implants are not and do not function like teeth. From a clinician's perspective, implant restorations using concepts of dentate occlusion do have a reasonable success/survival rate. In fact, the literature is replete with serial case studies and a few well-done clinical trials demonstrating these outcomes.^{84,85} Failures do occur, as with any dental restoration, and are quite instructive in hindsight. We should encourage ongoing

studies of different occlusal concepts, testing these, and being logical in our treatment planning and restorative designs. In this way, we continue to provide optimal patient care in a constantly changing environment. **CDA**

- References** / 1. Roos J, Sennerby L, Albrektsson T, An update on the clinical documentation on currently used bone anchored endosseous oral implants. *Dent Update* 24(5):194-200, 1997.
2. Koh H, Robinson PG, Occlusal adjustment for treating and preventing temporomandibular joint disorders. Cochrane Oral Health Group. Cochrane Database of Systematic Reviews 4, 2004.
3. Binon PP, Implants and components: entering the new millennium. *Int J Oral Maxillofac Implants* 15(1): 76-94, 2000.
4. Jokstad A, Braegger U, Brunski JB, et al, Quality of Dental Implants. *Int J Prosthodont* 17(6): 607-41, 2004.
5. Goodacre CJ, Bernal G, et al, Clinical complications with implants and implant prostheses. *J Prosthet Dent* 90(2):121-32, 2003.
6. Sahin SM, Cehreli C, et al, The influence of functional forces on the biomechanics of implant-

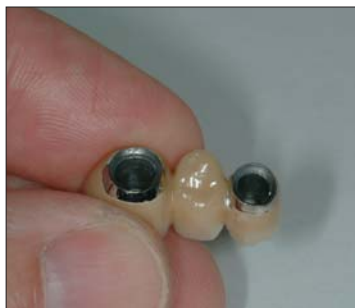

Figure 5. Intaglio side of completed three-unit PFM-fixed partial denture.

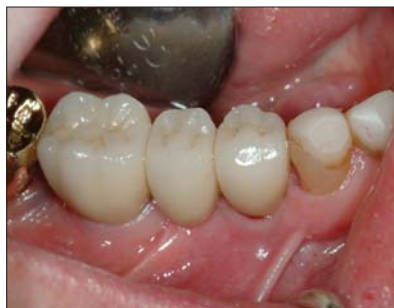

Figure 6. Occlusal view of fixed partial denture in place.

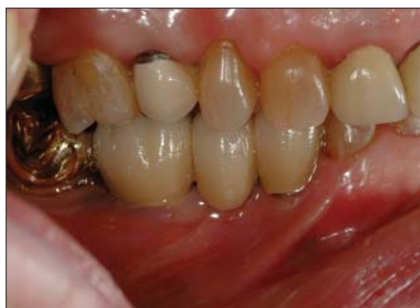

Figure 7. Anterior guidance maintained in laterotrusive movements.

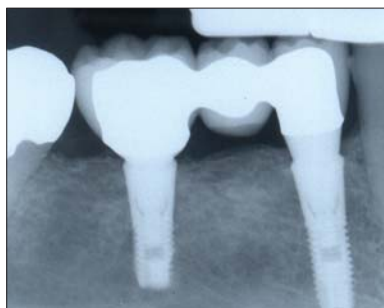

Figure 8. Radiograph at one-year recall demonstrating maintenance of bone around loaded three-unit fixed partial denture.

supported prostheses — a review. *J Dent* 30(7-8):271-82, 2002.

7. Brunski JB, Puleo DA, et al, Biomaterials and biomechanics of oral and maxillofacial implants: Current status and future developments. *Int J Oral Maxillofac Implants* 15(1): 15-46, 2000.

8. Lundgren D, Laurell L. Occlusal forces in prosthodontically restored dentitions: a methodological study. *J Oral Rehab* 11: 29-37, 1984.

9. Kaukinen JA, Edge MJ, et al, The influence of occlusal design on simulated masticatory forces transferred to implant-retained prostheses and supporting bone. *J Prosthet Dent* 76(1): 50-5, 1996.

10. Cibirka RM, Razzoog ME, et al, Determining the force absorption quotient for restorative materials used in implant occlusal surfaces. *J Prosthet Dent* 67(3): 361-4, 1992.

11. Stanford CM, Brand RA, Toward an understanding of implant occlusion and strain adaptive bone modeling and remodeling. *J Prosthet Dent* 81(5):553-61, 1999.

12. Taylor T, American College of Prosthodontist Prosthodontic Review Course, Role of Implant Biomechanics. Chicago IL., Nov. 19, 2004.

13. Brånemark PI, Osseointegration and its experimental background. *J Prosthet Dent* 50(3): 399-410, 1983.

14. Lindquist LW, Rockler B, Carlsson GE, Bone resorption around fixtures in edentulous patients treated with mandibular fixed tissue-inte-

grated prostheses. *J Prosthet Dent* 59: 59-63, 1988.

15. Skalak R, Osseointegration biomechanics. *J Oral Implantology* 12(3): 350-60, 1986.

16. Stanford CM, Biomechanical and functional behavior of implants. *Adv Dent Res* 13:88-92, 1999.

17. Ogiso M, Tabata T, et al, A histologic comparison of the functional loading capacity of an occluded dense apatite implant and the natural dentition. *J Prosthet Dent* 71(6): 581-8, 1994.

18. Celletti R, Pameijer CH, et al, Histologic evaluation of osseointegrated implants restored in nonaxial functional occlusion with preangled abutments. *Int J Perio Restorat Dent* 15(6): 562-73, 1995.

19. Asikainen P, Klemetti E, et al, Titanium implants and lateral forces. An experimental study with sheep. *Clin Oral Implants Res* 8(6): 465-8, 1997.

20. Miyata T, Kobayashi Y, et al, The influence of controlled occlusal overload on peri-implant tissue: a histologic study in monkeys. *Int J Oral Maxillofac Implants* 13(5): 677-83, 1998.

21. Adell R, Eriksson B, et al, Long-term follow-up study of osseointegrated implants in the treatment of totally edentulous jaws. *Int J Oral Maxillofac Implants* 5(4): 347-59, 1990.

22. Naert I, Quirynen M, et al, (1992). A six-year prosthodontic study of 509 consecutively inserted implants for the treatment of partial edentulism. *J Prosthet Dent* 67(2): 236-45, 1992.

23. Mombelli A, Prevention and Therapy of peri-implant infections. In: Lang NP, Karring T and Lindhe J. Eds. Proceeding of the third European Workshop on Periodontology, 281-303. Berlin: Quintessence 1999.

24. Isidor, F, Loss of osseointegration caused by occlusal load of oral implants. A clinical and radiographic study in monkeys. *Clin Oral Implants Res* 7(2): 143-52, 1996.

25. Heitz-Mayfield LJ, Schmid B, et al, Does excessive occlusal load affect osseointegration? An experimental study in the dog. *Clin Oral Implants Res* 15: 259-68, 2004.

26. Gottfredsen K, Berglundh T, et al, Bone reactions adjacent to titanium implants subjected to static load - A study in the dog (I). *Clin Oral Implants Res* 12(1): 1-8, 2001.

27. Gottfredsen K, Berglundh T, et al, Bone reactions adjacent to titanium implants with different surface characteristics subjected to static load. A study in the dog (II). *Clin Oral Implants Res* 12(3): 196-201, 2001.

28. Gottfredsen K, Berglundh T, et al, Bone reactions at implants subjected to experimental peri-implantitis and static load. A study in the dog. *J Clin Periodont* 29(2): 144-51, 2002.

29. Duyck J, Ronold HJ, et al, The influence of static and dynamic loading on marginal bone reactions around osseointegrated implants: an animal experimental study. *Clin Oral Implants Res* 12(3): 207-18, 2001.

30. Brunski JB, Slack JM, Orthodontic loading of implants: Biomechanical considerations. *Orthod Appl Osseointegrated Implants* 89-108, 2000.

31. Bryant SR, Zarb GA, Osseointegration of oral implants in older and younger adults. *Int J Oral Maxillofac Implants* 13(4):492-9, 1998.

32. Gapski R, Wang HL, et al, Critical review of immediate implant loading. *Clin Oral Implants Res* 14(5): 515-27, 2003.

33. Lekholm U, Zarb G, Patient Selection and Preparation. In: PI Brånemark, Zarb G, Albrektsson T, editors. Tissue Integrated Prostheses: Osseointegration in Clinical Dentistry. Chicago: Quintessence Publishing Co., Inc.; 199-209, 1985.

34. Jaffin RA, Berman CL, The excessive loss of Brånemark fixtures in type IV bone: a 5-year analysis. *J Periodontol* 62(1):2-4, 1991.

35. Jemt T, Lekholm U, Implant treatment in edentulous maxillae: a 5-year follow-up report on patients with different degrees of jaw resorption. *Int J Oral Maxillofac Implants* 10(3):303-11, 1995.

36. Blomqvist JE, Alberius P, et al, Factors in implant integration failure after bone grafting: an osteometric and endocrinologic matched analysis. *Int J Oral Maxillofac Surg* 25(1):63-8, 1996.

37. Lill W, Thornton B, et al, Statistical analyses on the success potential of osseointegrated implants: a retrospective single-dimension statistical analysis. *J Prosthet Dent* 69(2):176-85, 1993.

38. Lindh T, Gunne J, et al, A meta-analysis of implants in partial edentulism. *Clin Oral Implants Res* 9(2):80-90, 1998.

39. Buser D, Mericske-Stern R, et al, Clinical experience with one-stage, non-submerged dental implants. *Adv Dent Res* 13: 153-61, 1999.

40. Buser D, Nydegger T, et al, Interface shear strength of titanium implants with a sandblasted and acid-etched surface: a biomechanical study in the maxilla of miniature pigs. *J Biomed Mater Res* 45(2): 75-83, 1999.

41. Cochran DL, Buser D, et al, The use of



reduced healing times on ITI implants with a sand-blasted and acid-etched (SLA) surface: early results from clinical trials on ITI SLA implants. *Clin Oral Implants Res* 13(2): 144-53, 2002.

42. Li DH, Ferguson SJ, et al, Biomechanical comparison of the sandblasted and acid-etched and the machined and acid-etched titanium surface for dental implants. *J Biomed Mater Res* 60(2): 325-32, 2002.

43. Stanford C, Surface Modification of Implants. In: Buckley MJ and Keller JC, editors. *Emerging Biomaterials. Oral Maxillofac Surgery Clinics North Am.* Philadelphia: W.B. Saunders Company;14(1): 39-52, 2002.

44. Buser D, Schenk RK, et al, Influence of surface characteristics on bone integration of titanium implants. A histomorphometric study in miniature pigs. *J Biomed Mater Res* 25(7):889-902, 1991.

45. Wong M, Eulenberger J, et al, Effect of surface topology on the osseointegration of implant materials in trabecular bone. *J Biomed Mater Res* 29(12):1567-75, 1995.

46. Wennerberg A, Albrektsson T, et al, A histomorphometric and removal torque study of screw-shaped titanium implants with three different surface topographies. *Clin Oral Implants Res* 6(1):24-30, 1995.

47. Wennerberg A, Ohlsson R, et al, Characterizing 3-D topography of engineering and biomaterial surfaces by confocal laser scanning and stylus techniques. *Med Eng Phys* 18(7):548-556, 1996.

48. Wennerberg A, Albrektsson T, Lausmaa J, Torque and histomorphometric evaluation of c.p. titanium screws blasted with 25- and 75-microns-sized particles of Al₂O₃. *J Biomed Mater Res* 30(2):251-60, 1996.

49. Lundgren AK, Lundgren D, et al, Influence of surface roughness of barrier walls on guided bone augmentation: experimental study in rabbits. *Clin Implant Dent Relat Res* 1(1):41-48, 1999.

50. Wennerberg A, Albrektsson T. Suggested guidelines for the topographic evaluation of implant surfaces. *Int J Oral Maxillofac Implants* 15(3):331-44, 2000.

51. Sawase T, Wennerberg A, et al, Chemical and topographical surface analysis of five different implant abutments. *Clin Oral Implants Res* 11(1):44-50, 2000.

52. Wennerberg A, Johansson CB, et al, Enhanced fixation to bone with fluoride modified oral implants. In: IADR/AADR/CADR; 2000; Washington DC: IADR; 254, 2000.

53. Hansson S, Surface roughness parameters as predictors of anchorage strength in bone: a critical analysis. *J Biomechanics* 33(10):1297-1303, 2000.

54. Hansson S, The implant neck: smooth or provided with retention elements. A biomechanical approach. *Clin Oral Implants Res* 10(5):394-405, 1999.

55. Hansson S, Norton M, The relation between surface roughness and interfacial shear strength for bone-anchored implants. A mathematical model. *J Biomechanics* 32(8):829-36, 1999.

56. Albrektsson T, Wennerberg A, Oral Implant Surfaces: Part 1 - Review focusing on topographic and chemical properties of different surfaces and in vivo responses to them. *Int J Prosthodontics* 17: 536-43, 2004.

57. Gotfredsen K, Wennerberg A, et al, Anchorage of TiO₂-blasted, HA-coated, and machined implants: an experimental study with

rabbits. *J Biomed Mater Res* 29(10):1223-31, 1995.

58. Wennerberg A, Albrektsson T, Andersson B, Bone tissue response to commercially pure titanium implants blasted with fine and coarse particles of aluminum oxide. *Int J Oral Maxillofac Implants* 11(1):38-45, 1996.

59. Wennerberg A, Hallgren C, et al, A histomorphometric evaluation of screw-shaped implants each prepared with two surface roughnesses. *Clin Oral Implants Res* 9(1):11-19, 1998.

60. Stanford CM, Schneider G, et al, Biomedical implant surface topography and its effects on osteoblast differentiation in vitro. *Bio Implant Interface: Improving Biomaterials and Tissue Reactions.* CRC Press. Boca Raton, 141-64, 2003.

61. Schneider GB, Perinpanayagam H, et al, Implant surface roughness affects osteoblast gene expression. *J Dent Res* 82(5):372-6, 2003.

62. Schwitters C, Schneider G, et al, Bone sialoprotein expression in UMR 106-01b osteoblasts increases in vitro on roughened surfaces. *J Dent Res* 81(Special Issue):A-439, 2002.

63. Koka S, The implant-mucosal interface and its role in the long-term success of endosseous oral implants: a review of the literature. *Int J Prosthodont* 11(5):421-32, 1998.

64. King GN, Hermann JS, et al, Influence of the size of the microgap on crestal bone levels in non-submerged dental implants: a radiographic study in the canine mandible. *J Periodont* 73(10):1111-7, 2002.

65. Hermann JS, Buser D, et al, Biologic width around one- and two-piece titanium implants. *Clin Oral Implants Res* 12(6):559-71, 2001.

66. Hermann JS, Schoolfield JD, et al, Influence of the size of the microgap on crestal bone changes around titanium implants. A histometric evaluation of unloaded non-submerged implants in the canine mandible. *J Periodont* 72(10):1372-83, 2001.

67. Hermann JS, Schoolfield JD, et al, Crestal bone changes around titanium implants: a methodologic study comparing linear radiographic with histometric measurements. *Int J Oral Maxillofac Implants* 16(4):475-85, 2001.

68. Carr AB, Laney WR, Maximum occlusal force levels in patients with osseointegrated oral implant prostheses and patients with complete dentures. *Int J Oral Maxillofac Implants* 2(2):101-18, 1987.

69. Klineberg I, Murray G, Osseoperception: sensory function and proprioception. *Adv Dent Res* 13:120-9, 1999.

70. Rydevik B, editor, Amputation prosthesis and osseoperception in the lower and upper extremity. Chicago: Quintessence; 1997.

71. Mullender MG, Huijskes R, Osteocytes and bone lining cells: which are the best candidates for mechano-sensors in cancellous bone? *Bone* 20(6):527-32, 1997.

72. Meredith N, Alleyne D, et al, Quantitative determination of the stability of the implant-tissue interface using resonance frequency analysis. *Clin Oral Implants Res* 7(3): 261-7, 1996.

73. Meredith N, Book K, et al, Resonance frequency measurements of implant stability in vivo. A cross-sectional and longitudinal study of resonance frequency measurements on implants in the edentulous and partially dentate maxilla. *Clin Oral Implants Res* 8(3): 226-33, 1997.

74. Meredith, N. Assessment of implant stability as a prognostic determinant. *Int J Prosthodont*

11(5): 491-501, 1998.

75. Rasmusson L, Meredith N, et al, Stability assessments and histology of titanium implants placed simultaneously with autogenous onlay bone in the rabbit tibia. *Int J Oral Maxillofac Surg* 27(3): 229-35, 1998.

76. Sennerby L, and Meredith N, Resonance frequency analysis: measuring implant stability and osseointegration. *Compend Contin Educ Dent* 19(5): 493-8, 1998.

77. O'Sullivan D, Sennerby L, et al, Measurements comparing the initial stability of five designs of dental implants: a human cadaver study. *Clin Implants Dent Rel Res* 2(2): 85-92, 2000.

78. Brunski JB, Biomechanical considerations in dental implant design. *Int J Oral Implantology* 5(1): 31-4, 1988.

79. Binon PP and McHugh MJ, The effect of eliminating implant/abutment rotational misfit on screw joint stability. *Int J Prosthodont* 9(6): 511-9, 1996.

80. Cehreli MC, Akca K, et al, Dynamic fatigue resistance of implant-abutment junction in an internally notched morse-taper oral implant: influence of abutment design. *Clin Oral Implants Res* 15(4):459-65, 2004.

81. Norton MR, An in vitro evaluation of the strength of a one-piece and two-piece conical abutment joint in implant design. *Clin Oral Implants Res* 11(5): 458-64, 2000.

82. Stanford CM, Demands of the Restorative Dentist to Oral Implants. In: Booth PW, Schendel S. Hausamen JE. editors. *Maxillofacial Surgery.* 2nd Edition. Edinburgh: Churchill Livingstone; ch 96, 2005.

83. Stanford CM, Application of oral implants to the general dental practice. Practical Sciences section, *J Am Dent Assoc* November 2004.

84. Esposito M, Coulthard P, et al, Quality assessment of randomized controlled trials of oral implants. *Int J Oral Maxillofac Implants* 16(6): 783-92, 2001.

85. Esposito M, Worthington HV, et al, In search of truth: the role of systematic reviews and meta-analyses for assessing the effectiveness of rehabilitation with oral implants. *Clin Implants Dent Rel Res* 3(2): 62-78, 2001.

To request a printed copy of this article, please contact / C.M. Stanford, DDS, PhD, Dows Institute for Dental Research and Department of Prosthodontics, 447 Dental Science Building North, University of Iowa, Iowa City, Iowa, 52242.



Immediate Loading of Dental Implants: Overview and Rationale

KRIKOR DERBABIAN, DDS, AND KRIKOR SIMONIAN, DDS

ABSTRACT

Brånemark established the concept of osseointegrated dental implants as a predictable modality for treatment of edentulous patients. He defined osseointegration as bone-to-implant contact at the microscopic level. Osseointegration was a revolutionary concept in implant dentistry. While earlier pioneers never considered direct bone anchoring of the implant, and even established interposition of fibrous tissue between implant and bone as desirable to mimic periodontal ligament function, Brånemark et al. demonstrated that direct bone apposition at the implant surface was not only possible, but long lasting.^{1,2}

Several long-term studies demonstrated high success rates when a strict surgical and prosthodontic protocol was followed.^{2,3} One of the principal criteria for proper osseointegration was the need for unloaded submerged healing of the implants for a period of three to six months (two-stage approach).²⁻⁴ The concern was that premature loading would cause micromotion leading to fibrous encapsulation of the implant.^{2,3}

However, the long-term success and predictability with dental implants encouraged clinicians to reassess the



Authors / Krikor Derbabian, DDS, maintains a practice limited to prosthodontics. He is principal of the Center for Prosthetic

Dentistry, a prosthodontic group practice with locations in Burbank and Pasadena, Calif.

Krikor Simonian, DDS, is clinical associate professor, Advanced Education in Periodontology at the University of Southern California School of Dentistry. He also maintains a private practice limited to periodontics and implant dentistry in Pasadena, Calif.

Acknowledgements / Paolo Corrado, MD, DDS, Verona, Italy, for the restorative treatment for the patient No. 1, and Dr. Richard Lin (USC advanced prosthodontics) for the restorative treatment for patient No. 2.



original Brånemark protocol, since it was based primarily on clinical observations and not necessarily on biologic principles.⁵

The prolonged postoperative period following implant placement led to unavoidable difficulties in patient management. During this osseointegration period, several complications, including loose dentures, fractured prosthesis, sore spots and periodic provisional relines, plagued the clinician and the patient. In addition, the necessity for a removable prosthesis, even for a short period, was a deterrent in itself for some patients whose primary goal was to avoid a removable denture in the first place.

Thus, the concept of submerged healing was challenged first by Schroeder and then in animal and human studies by Ericsson et al. and Becker et al. who demonstrated that one- and two-stage approaches both led to similarly successful results.⁶⁻⁹

Rationale

One-stage implants, even without occlusal loading, unavoidably bear some functional stresses in the oral cavity due to forces exerted by the tongue, cheeks, lips and the inevitable masticatory forces. Additionally, animal studies have reported that implants with treated surfaces lead to an accelerated initial healing and increased bone-to-implant contact.¹⁰⁻¹³ These two findings led to the next phase of research that tested the viability of earlier loading with surface-treated implants. In a multicenter one-year study, Lazzara et al. loaded both maxillary and mandibular implants at two months postplacement, and achieved a 98 percent success rate.¹⁴

Albrektsson had postulated that early loading of implants would lead to fibrous encapsulation instead of osseointegration.¹⁵ In an early study, Henry and Rosenberg questioned the validity of this assessment by treating five edentulous

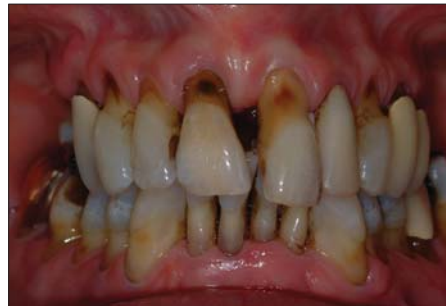

Figure 1. Pretreatment view of a patient diagnosed with chronic severe periodontitis.

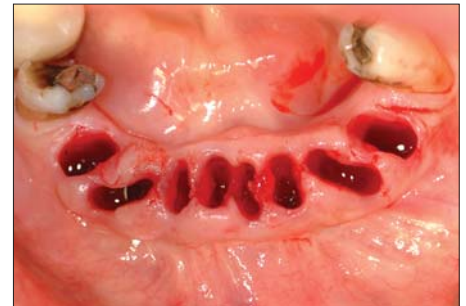

Figure 2. Terminal mandibular molars were maintained to stabilize the surgical guide.

patients using four implants as immediate overdenture abutments, and postulating that "controlled immediate loading" does not jeopardize the process of osseointegration. Schnitman followed 10 patients for 10 years after immediately loading some of the implants placed to retain provisional restorations, with the expectation that these implants would fail. Since most of the implants integrated without any problems, they were later incorporated in the final prostheses (Schnitman 1990, Schnitman 1997).¹⁶⁻¹⁸ The success rate of the immediately loaded implants were 86 percent compared to 100 percent for the submerged group. While there was a statistically significant difference in success rates, the authors suggested that the quality of bone was the primary factor in the failure rate. In a retrospective five-year multicenter study, 226 patients had four implants placed interforamina, and were restored with an implant bar supporting an overdenture. The reported success rate was 97 percent with most failures occurring during the first year.¹⁹

Tarnow et al. treated 10 patients with a minimum of 10 implants in edentulous maxillary or mandibular arches. At least five of the implants were immediately loaded with fixed provisional crossarch restorations.²⁰ The patients were followed for one to five years and both immediately loaded and submerged

implants had a 97 percent success rate. A number of other authors similarly demonstrated that implants placed with primary stability in the edentulous arches could be loaded immediately with high success rates, when crossarch splinting is provided.²¹⁻²⁴ Osseointegration in immediately loaded implants was also demonstrated histologically by Piatelli.²⁵

The conclusion from the numerous studies points to the observation that the critical factor in osseointegration is not early loading of the implant, but rather the absence of excessive micromotion. Initial stability seems to be a prerequisite. When implants are immediately loaded, micromotion is unavoidable; however, a certain amount up to 100 μ m seems to be tolerated and is not deleterious to osseointegration.²⁶

To summarize the findings of these previous studies, implants can be immediately loaded in full function provided that micromotion is controlled by following a meticulous case selection, such as crossarch stabilization, controlling occlusal overload, wide distribution of implants and minimizing cantilevered portions.

Parameters for Immediately Loading

Based on the experience gained from the numerous studies previously mentioned, initial stability is the prerequisite for immediate loading and is

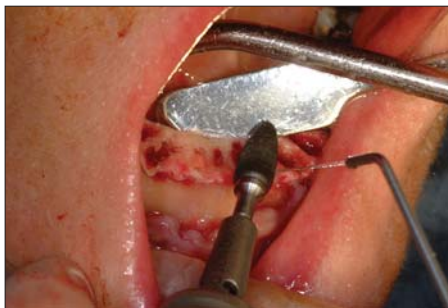

Figure 3.

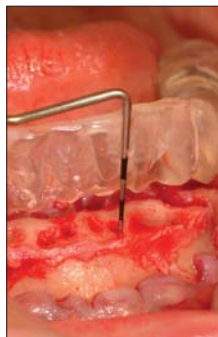


Figure 4.

Figures 3 and 4. Alveolectomy was performed to create sufficient occlusal space for mandibular prosthesis.

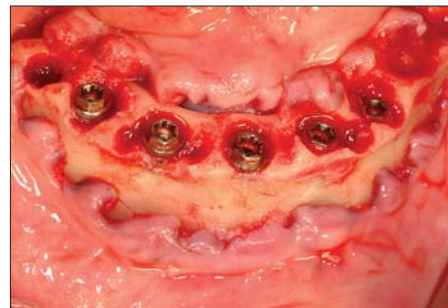


Figure 5. Five endosseous screw-type implants were placed in the interforamina space.

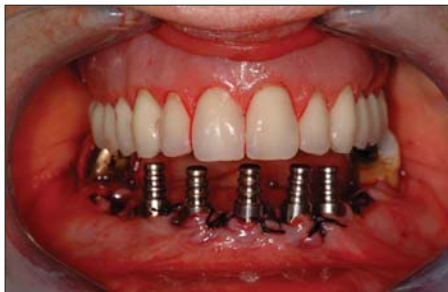

Figure 6. Abutments and impression copings were placed. Note the retained molars maintain the patient's existing occlusal vertical dimension.

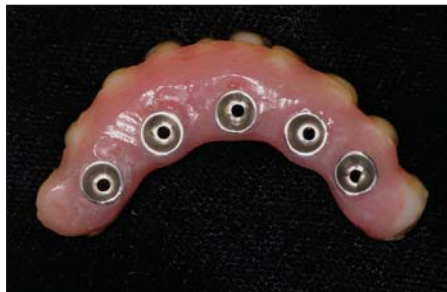

Figure 7. The mandibular provisional prosthesis was fabricated extraorally. Notice the highly polished tissue side.

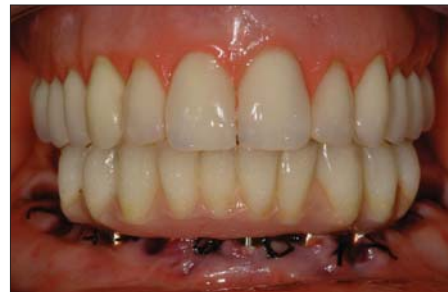

Figure 8. View of mandibular provisional prosthesis in the mouth immediately prior to patient dismissal.

dependent on a number of parameters, including proper surgical technique and type of bone. Therefore, the following recommendations should be considered to maximize success:

- Implants should be at least 10 mm long.
- Adequate number and distribution of implants to provide crossarch stabilization
- Good initial stability of the implants with minimum insertion torques of 35-50 Ncm²⁷
- Passive fit of provisional restoration
- Sufficient interocclusal space should be present for adequate bulk of provisional restoration and rigidity to minimize micromotion.
- Even occlusal contacts
- Cantilevers should be avoided or

minimized to one premolar.

■ Removal of the provisional restoration should be avoided during the osseointegration period.

■ Patients with parafunctional habits may not be ideal candidates.

Patient Treatment Reports

Patient No. 1

This 65-year old female patient presented with severe chronic periodontitis. After discussing several options, she was treatment planned for complete mouth extractions, a maxillary removable complete denture, and a mandibular implant fixed complete denture (hybrid-type prosthesis) (Figure 1). A CT-scan of the mandible was performed to evaluate the bone for implant placement. On the day of surgery, all maxillary teeth were

extracted and a maxillary immediate complete denture placed. All mandibular teeth, with the exception of the two distal molars, were extracted. These teeth were retained to stabilize the surgical guide, which was previously fabricated (Figure 2). Full thickness flaps were raised and the alveolar ridge was recontoured to create sufficient interocclusal space (Figures 3, 4). Five 4 x 15 mm dental implants were placed using the surgical guide as a guide in the interforamina space (Figure 5). The flaps were sutured, multiunit abutments and transfer impression copings were placed, and an impression was made (Figure 6). A screw-retained provisional restoration was made extraorally, and placed (Figures 7, 8). Thus, the patient bypassed a removable mandibular prosthesis stage. Three months after implant placement, the pro-

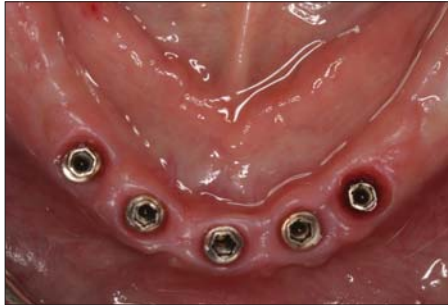

Figure 9. Three months' postdelivery. Implants are osseointegrated and ready for final restoration.

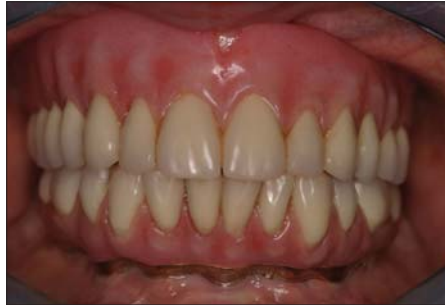

Figure 10.

Figures 10 and 11. One year after delivery of definitive prosthesis. Note lingual staining due to heavy smoking.

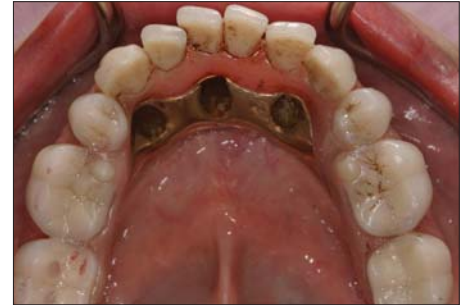

Figure 11.

visional restoration was removed (Figure 9) and the final prosthesis fabricated. At the one-year recall, the patient was pleased and the restoration is functioning without any complications (Figure 10), even though the patient continues to smoke (Figure 11).

Patient No. 2

This 68-year old Caucasian man presented with a hopeless mandibular dentition. After discussing several options, he was treatment planned to have all remaining mandibular teeth extracted, and restored with an implant fixed complete denture (hybrid-type prosthesis). A CT-scan was performed to evaluate the bone for implant placement. Prior to the extractions, two provisional implants were placed bilaterally to stabilize the surgical guide (Figure 12). On the day of surgery, the remaining mandibular teeth were extracted (Figure 13), and five 4 x 13 implants were placed using the surgical guide as a guide (Figures 14, 15). Abutments and temporary cylinders were placed on the implants. The previously placed provisional implants were used to position the provisional restoration that was adjusted to fit around the temporary cylinders (Figure 16). The temporary cylinders were picked up intraorally using autopolymerizing acrylic resin (Figure 17). The restoration was completed extraorally

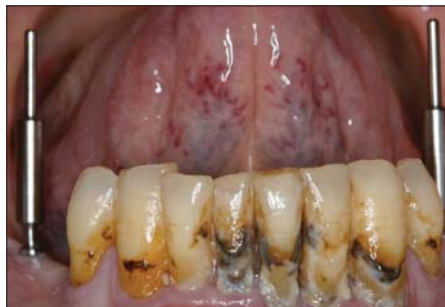

Figure 12. Two provisional implants were placed to stabilize the surgical guide.

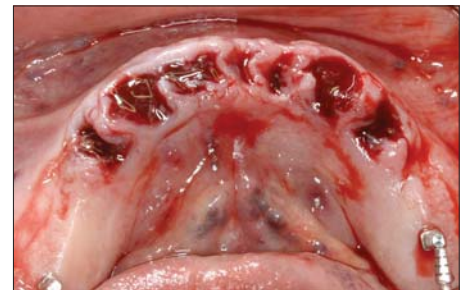

Figure 13. Occlusal view of mandible after extractions.

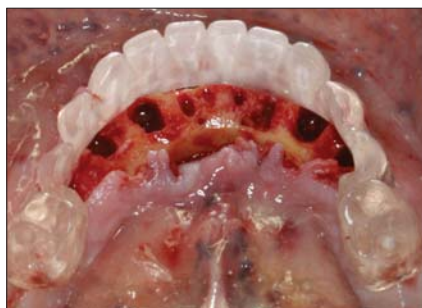

Figure 14. The surgical guide was stabilized on the provisional implants.

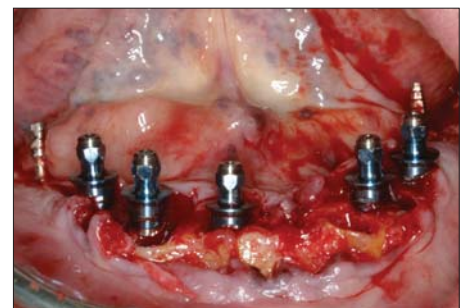


Figure 15. Five endosseous implants were placed intraforamina.

and the screw-retained restoration was placed within hours of the extractions (Figures 18, 19).

Summary

Implant dentistry has continued to evolve vastly since the initial groundbreaking work of Brånemark and colleagues. Current scientific knowledge sup-

ports the feasibility of immediately loading dental implants, provided that careful patient selection, pretreatment planning and a proper surgical/restorative protocol is followed. The benefits to the patient and clinician are numerous and include shortened treatment time, avoiding a removable prosthesis phase, and minimizing the number of office visits.

CDA

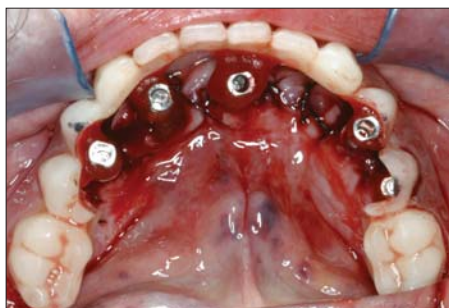

Figure 16. Previously fabricated provisional prosthesis was placed intraorally. Note that provisional implants help align the provisional restoration.

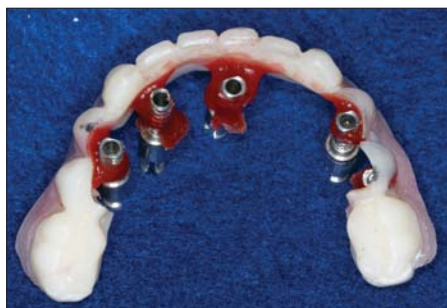

Figure 17. Temporary cylinders are picked-up intraorally using autopolymerizing acrylic resin.

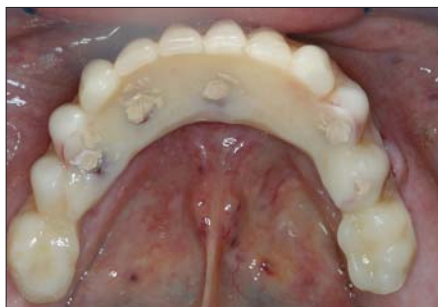

Figure 18.

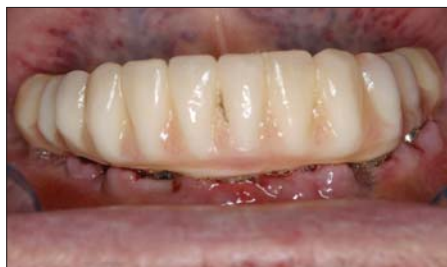

Figure 19.

Figures 18 and 19. The provisional restoration is completed extraorally and placed within hours of the extractions.

References / 1. Linkow LI, Chercheve R, Theories and techniques of oral implantology. CV Mosby Company, St. Louis, 1970, 74-6.

2. Brånemark PI, Hansson BO, et al, Osseointegrated implants in the treatment of the edentulous jaw. Experience from a 10-year period. *Scand J Plast Reconstr Surg (Suppl)* 16:1-132, 1977.

3. Adell R, Lekholm U, et al, A 15-year study of osseointegrated implants in the treatment of the edentulous jaw. *Int J Oral Surg* 10:387-416, 1981.

4. Albrektsson T, Direct bone anchorage of dental implants. *J Prosthet Dent* 50:255-61, 1983.

5. Szmukler-Moncler S, Piattelli A, Favero GA, et al, Considerations preliminary to the application of early and immediate loading protocols in dental implantology. *Clin Oral Implants Res* 11:12-25, 2000.

6. Schroeder A, Van Der Zypen E, Stich H, et al, The reaction of bone, connective tissue, and epithelium to endosteal implants with titanium-sprayed surfaces. *J Oral Maxillofac Surg* 9:15-25, 1981.

7. Ericsson I, Nilner K, Klinge B, Glantz PO, Radiographic and histological characteristics of submerged and non-submerged titanium implants. An experimental study in the Labrador dog. *Clin Oral Implants Res* 7:20-6, 1996.

8. Ericsson I, Randow K, et al, Some clinical and radiographic features of submerged and non-

submerged titanium implants. A five-year follow-up study. *Clin Oral Implants Res* 8(5):422-6, 1997.

9. Becker W, Becker BE, et al, One-step surgical placement of Brånemark implants: A prospective multicenter clinical study. *Int J Oral Maxillofac Implants* 12:454-62, 1997.

10. Buser D, Schenk RK, et al, Influence of surface characteristics on bone integration of titanium implants: A histomorphometric study in miniature pigs. *J Biomed Mater Res* 25:889-902, 1991.

11. Wennerberg A, Albrektsson T, Andersson B, Kroll JJ, A histomorphometric and removal torque study of screw-shaped titanium implants with three different surface topographies. *Clin Oral Implants Res* 6:24-30, 1995.

12. Klokkevold PR, Nishimura RD, Adachi M, et al, Osseointegration enhanced by chemical etching of the titanium surface. A torque removal study in the rabbit. *Clin Oral Implants Res* 8:442-7, 1997.

13. Cordioli G, Majzoub Z, Piattelli A, et al, Removal torque and histomorphometric investigation of 4 different titanium surfaces: an experimental study in the rabbit tibia. *Int J Oral Maxillofac Implants* 15:668-74, 2000.

14. Lazzara RJ, Porter SS, et al, A prospective multicenter study evaluating loading of osseointegrated implants two months after placement: One-year results. *J Esthet Dent* 10:280-9, 1998.

15. Albrektsson T, Brånemark PI, Hansson HA, Lindstrom J, Osseointegrated titanium implant. Requirements for ensuring a long-lasting, direct bone-to-implant anchorage in man. *Acta Orthop Scand* 52:155-70, 1981.

16. Henry P, Rosenberg J, Single-stage surgery for rehabilitation of the edentulous mandible. Preliminary results. *Pract Periodontics Aesthet Dent* 6:1-8, 1994.

17. Schnitman PA, Wohrle PS, Rubenstein JE, Immediate fixed interim prostheses supported by two stage threaded implants: Methodology and results. *J Oral Implantol* 2:96-105, 1990.

18. Schnitman PA, Wohrle PS, Rubenstein JE, Ten year results for Brånemark implants immediately loaded with fixed prostheses at implant placement. *Int J Oral Maxillofac Implants* 12:495-503, 1997.

19. Chiapasco M, Gatti C, et al, Implant-retained mandibular overdentures with immediate loading. A retrospective multicenter study on 226 consecutive cases. *Clin Oral Implants Res* 8:48-57, 1997.

20. Tarnow DP, Emtiaz S, Classi A, Immediate loading of threaded implants at stage 1 surgery in edentulous arches: Ten consecutive case reports with one- to five-year data. *Int J Oral Maxillofac Implants* 12:319-24, 1997.

21. Balsh TJ, Wolfinger GJ, Immediate loading of Brånemark implants in edentulous mandibles: A preliminary report. *Implant Dent* 6:83-8, 1997.

22. Salama H, Rose LF, et al, Immediate loading of bilaterally splinted titanium root-form implants in fixed prosthodontics, a technique re-examined: two case reports. *Int J Periodontics Restorative Dent* 15:344-61, 1995.

23. Grunder U, Immediate functional loading of immediate implants in edentulous arches: two-year results. *Int J Periodontics Restorative Dent* 21:545-51, 2001.

24. Cooper LF, Rahman A, Moriarty J, et al, Immediate mandibular rehabilitation with endosseous implants: simultaneous extraction, implant placement, and loading. *Int J Oral Maxillofac Implants* 17:517-25, 2002.

25. Piattelli A, Ruggieri A, et al, A histologic and histomorphometric study of bone reactions to unloaded and loaded non-submerged single implants in monkeys: a pilot study. *J Oral Implantol* 19:314-20, 1993.

26. Brunski JB, Biomechanical factors affecting the bone-dental implant surface. *Clin Mater* 10(3):153-201, 1992.

27. Brunski JB, Avoid pitfalls of overloading and micromotion of intraosseous implants. *Dent Implantol Update* 4(10):77-81, 1993.

To request a printed copy of this article, please contact / Krikor Derbabian, DDS, 2625 W. Alameda Ave., Suite 326, Burbank, Calif., 91505.

What's the Rush?

"Perhaps have a spot of tea and some lovely scones with a bit of raspberry jam on the side."



his month we honor the firm of Applebee & Freres, Pty., Ltd., of Liondown-on-the-Yob, NSW, Australia. Applebee, or as it is informally known locally, Woolenthralongabongdong (an Aboriginal word meaning literally "dis house belong you big discount"), is a dental supply company that has shaken the industry to its foundations by marketing products with hitherto unheard-of attributes.

Sir Geoffrey Graeme Nigel Applebee, OBE, MBE, FICD, SPCA, 93, senior partner of the firm explained his innovative ideas: "We here at Applebee & Freres, Pty., Ltd., aka Woolenthralongabongdong, of Liondown-on-the-Yob, NSW, ah, I'm sorry, old chap, what was the question? Oh, yiss ... we have had the growing suspicion over the last 40 years that dentistry is moving too fast. Rapport with patients has been sacrificed on the altar of high-volume production. It's a bloody shame is what it is! High-volume production required faster instruments, materials and techniques to cope with the increased demand. Or was it the other way 'round? No matter, it flouts every dictate of common sense, so Applebee &

Freres, Pty., Ltd., and so on and so forth have come up with the answer."

Sir Geoffrey adjusted his cannula, took a few hits off his O₂ flask and went on to excoriate Robert Nelson as the "flaming twit" who developed the first commercial air turbine handpiece, thus starting the downward spiral of dentistry "to hell in a handbasket." The 400,000 rpm air turbine, he claimed, begat the carbide bur that begat the extra coarse diamonds and, ultimately, begat the vaporizing lasers.

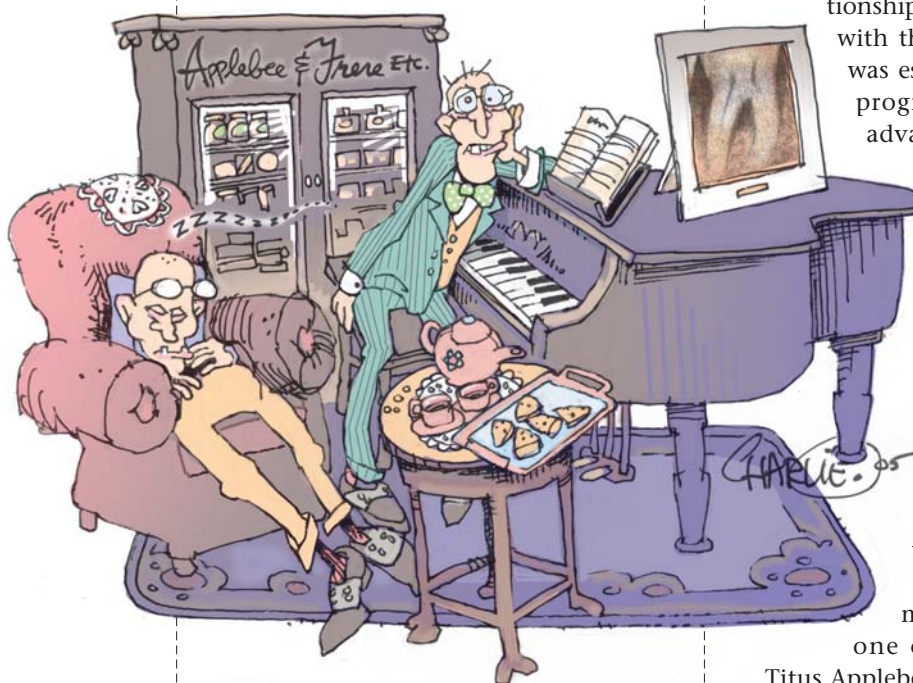
Simultaneously, Sir Geoffrey wheezed, some idiot invented composite resins and eventually curing lights that keep getting faster and curing deeper. "Where will it all end?" he demanded querulously.

Applebee, on a roll now, decries faster-setting cements, bloody fools who want their teeth bleached pure white in 45 minutes, and the brutish dentists, sounding new depths of swinishness who cater to their demands.

Taking the buttons off the foils, Sir Geoffrey prepared to eviscerate the concept of high-volume dentistry and the almost certain demise of the sacred doctor/patient relationship should he fail in his joust with this particular windmill. He was especially incensed by those progressive dentists who take advantage of delegating tasks to qualified assistants to the point where their only contribution to a given procedure is to greet the patient, issue instructions and decamp to the next operator. He charitably characterized them as "detestable spivs who'd slit your bloody weasand for a florin."

"May a pox fly away with them," he bleated.

Time for Sir Geoffrey's medication and a nap, so one of the freres, young Mr. Titus Applebee, 91, carried on, his den-



“You espy any long queues impatiently panting
for your ministrations? I think not!
Take time to smell the eugenol, Sonny!”

Continued from Page 358

tures rattling a curious counterpoint to his ancient respiratory apparatus. We pressed for an explanation of just what it is that Woolentharaalongabongdong is producing to warrant the “unheard of attributes” being applied to their output.

The brothers Applebee agree that *greed*, thinly disguised as *efficiency* is the motivation behind the manic quest for speed in the profession today. To reverse this deplorable condition, their company’s engineers and scientists have developed a line of equipment and consumables guaranteed to slow the practice of dentistry down to a more genteel pace.

For example, Applebee’s dental chair takes a full 30 minutes to go from upright to full back. Applebee no longer makes a high-speed handpiece, but features a slow-speed unit powered by rubber bands with a governor limiting its speed to just over 400 rpm. Advertising brochures for the Applebee “Slo-Mo,” as it is called, promises that full crown preps can now be handily accomplished in just four appointments when used in conjunction with their “super-fine” nonabrasive stone burs.

The company still makes a polyvinyl impression material, but has added a retardant to the mix, slowing the final set down to a more reasonable six hours. This gives dentist and patient plenty of time to get to know each other better, young Mr. Titus pointed out. “Perhaps have a spot of tea and some lovely scones with a bit of raspberry jam on the side,” he suggested.

Digital radiography raises the hackles of the Woolentharaalongabongdong etc. as a prime example of a speed-crazed world gone mad. The company touts their own X-ray machine as a re-

finement of technology borrowed from earlier Daguerreotype equipment. Applebee radiographs have a warm sepia tone that is said to soften the bad news that ordinary X-rays frequently reveal. Many patients, Mr. Titus reported, have taken intraoral scenes they are particularly fond of and given them pride-of-place atop the Steinway.

Naysayers who express qualms anent the decrease in production are given short shrift by the Applebees. “Look outside your office door,” commanded Sir Gregory who has suddenly regained consciousness and is enjoying the aromatherapy of a fine Panatela. “You espy any long queues impatiently panting for your ministrations? I think not! Take time to smell the eugenol, Sonny!”

The “less is more” philosophy as espoused by Applebee & Freres has captured the attention of not only dentists, but their business managers as well.

“As a viable concept,” reported Fiscal Deficiencies, the Chapter 11 experts who handled our affairs, “it has some merit, provided you are willing to live in the back of your van and sup at the Midnight Mission. Our calculations indicated, for example, that with the Applebee regimen in place, based on their two-patient-a-day recommendation, a one-surface posterior composite would have to fetch a fee of \$1,718.35 in order for you to stay in business.”

That certainly seems acceptable to us, and as soon as we can lay on a supply of day-old scones, some sugar-free jam and a pot of Earle’s Olde English Darjeeling, we are slipping quietly into snychromesh compound low. If this punctilio attracts you, join us. CDA