

Sclérodermie systémique: atteinte cutanée

Luc Mouthon

luc.mouthon@cch.aphp.fr

Service de Médecine Interne, hôpital Cochin,

Centre de Référence Vasculaites nécrosantes et sclérodermie systémique

Assistance publique-Hôpitaux de Paris, Paris

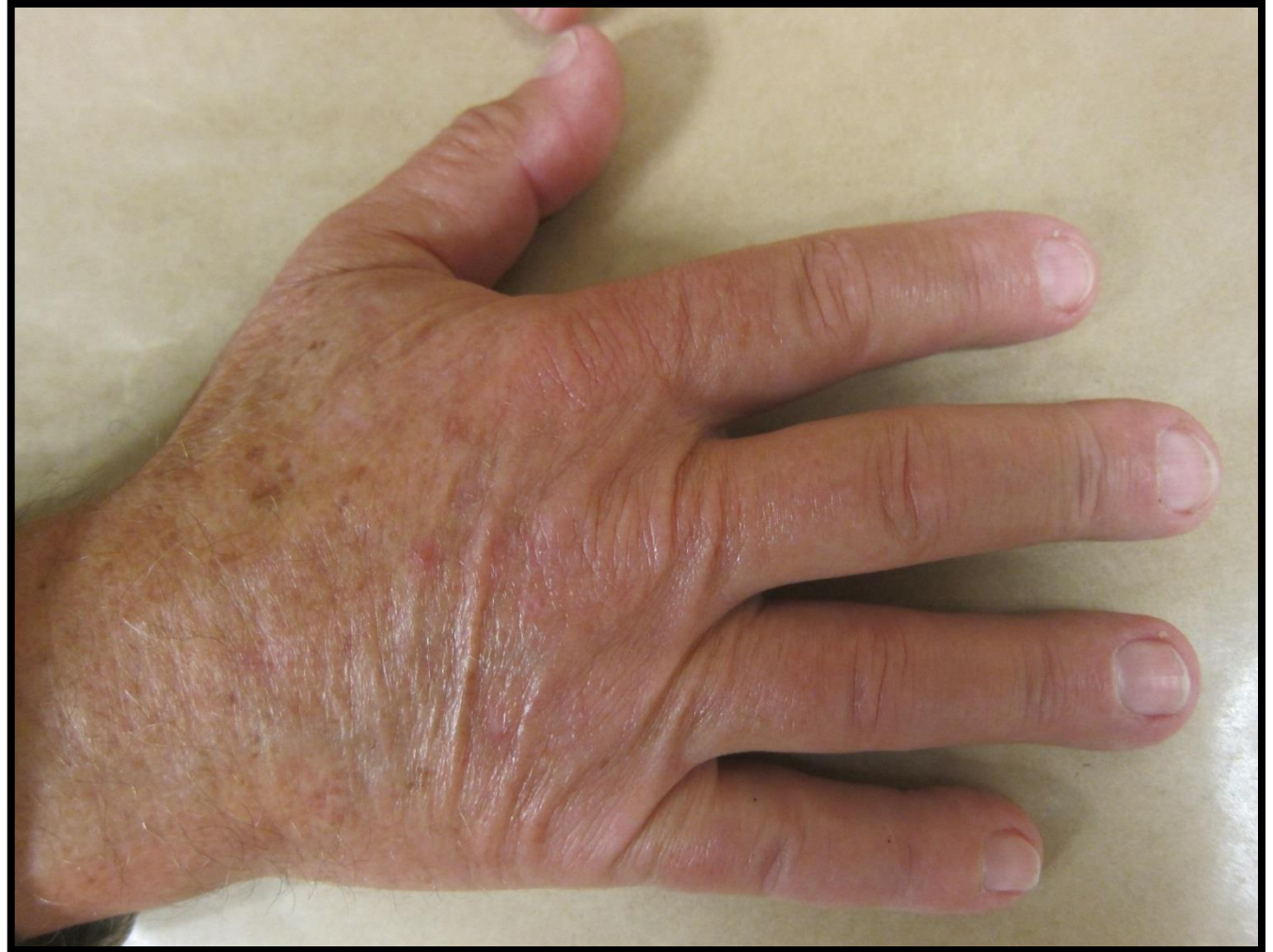Université Paris Descartes, Inserm U1016, Institut Cochin, Paris



2013 classification criteria for SSc: an ACR/EULAR collaborative initiative (I)

- Skin thickening of the fingers extending proximal to the metacarpophalangeal joints: SSc;
- If that is not present, 7 additive items apply:
 - skin thickening of the fingers,
 - fingertip lesions,
 - telangiectasia,
 - abnormal nailfold capillaries,
 - interstitial lung disease or pulmonary arterial hypertension,
 - Raynaud's phenomenon,
 - SSc-related autoantibodies.

Skin thickening of the fingers (I)



Score = 2

Puffy fingers

Only count higher score

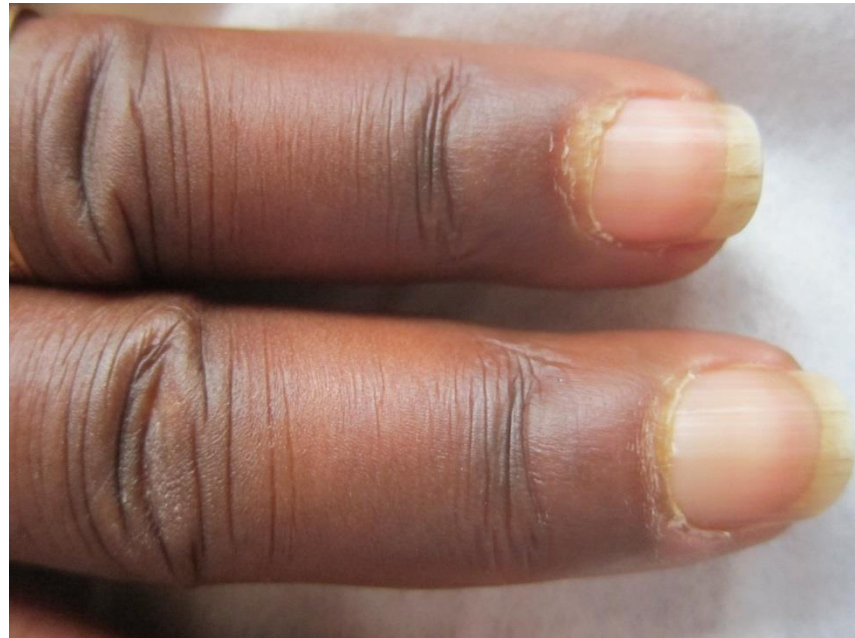Skin thickening of the fingers (II)

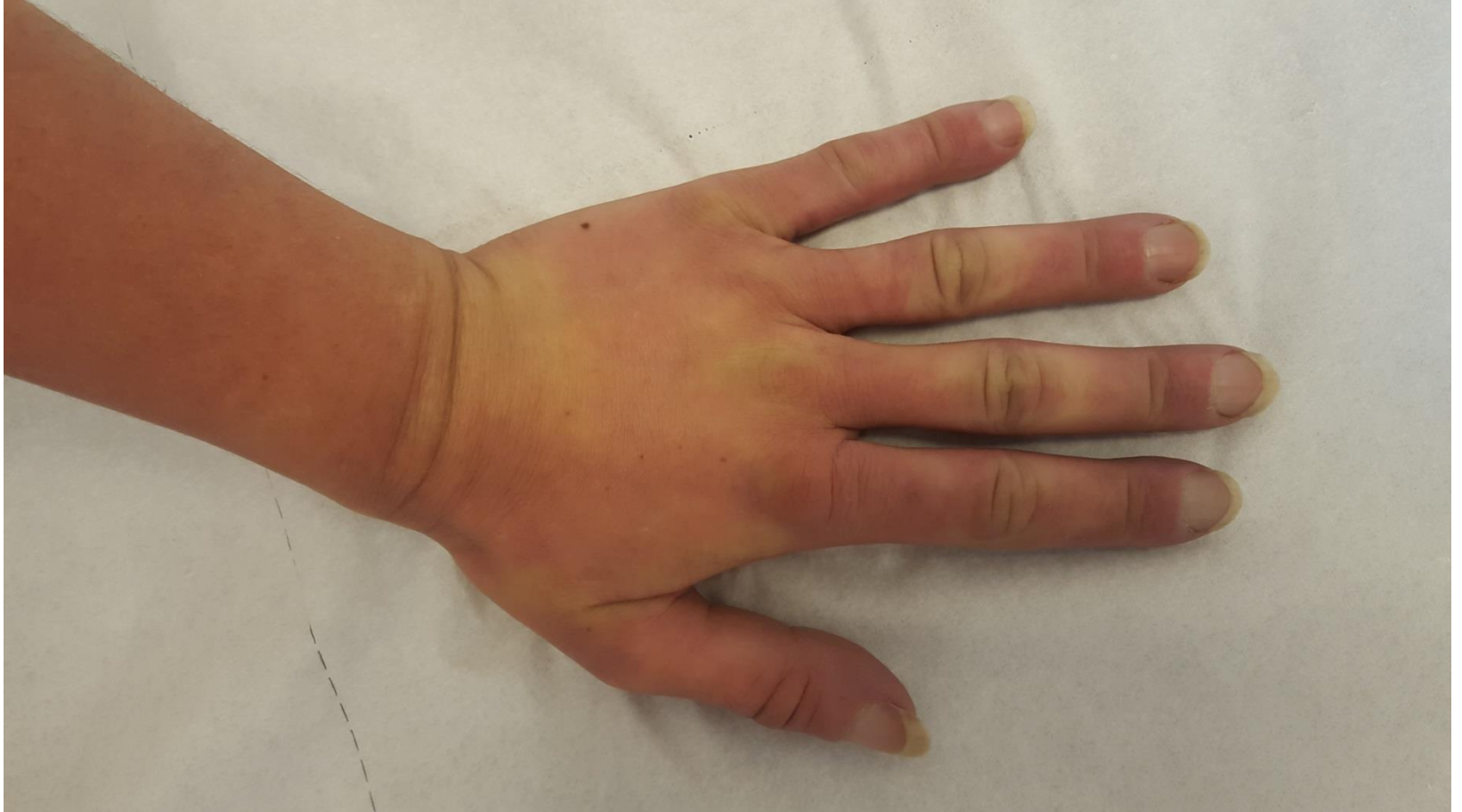

Sclerodactily

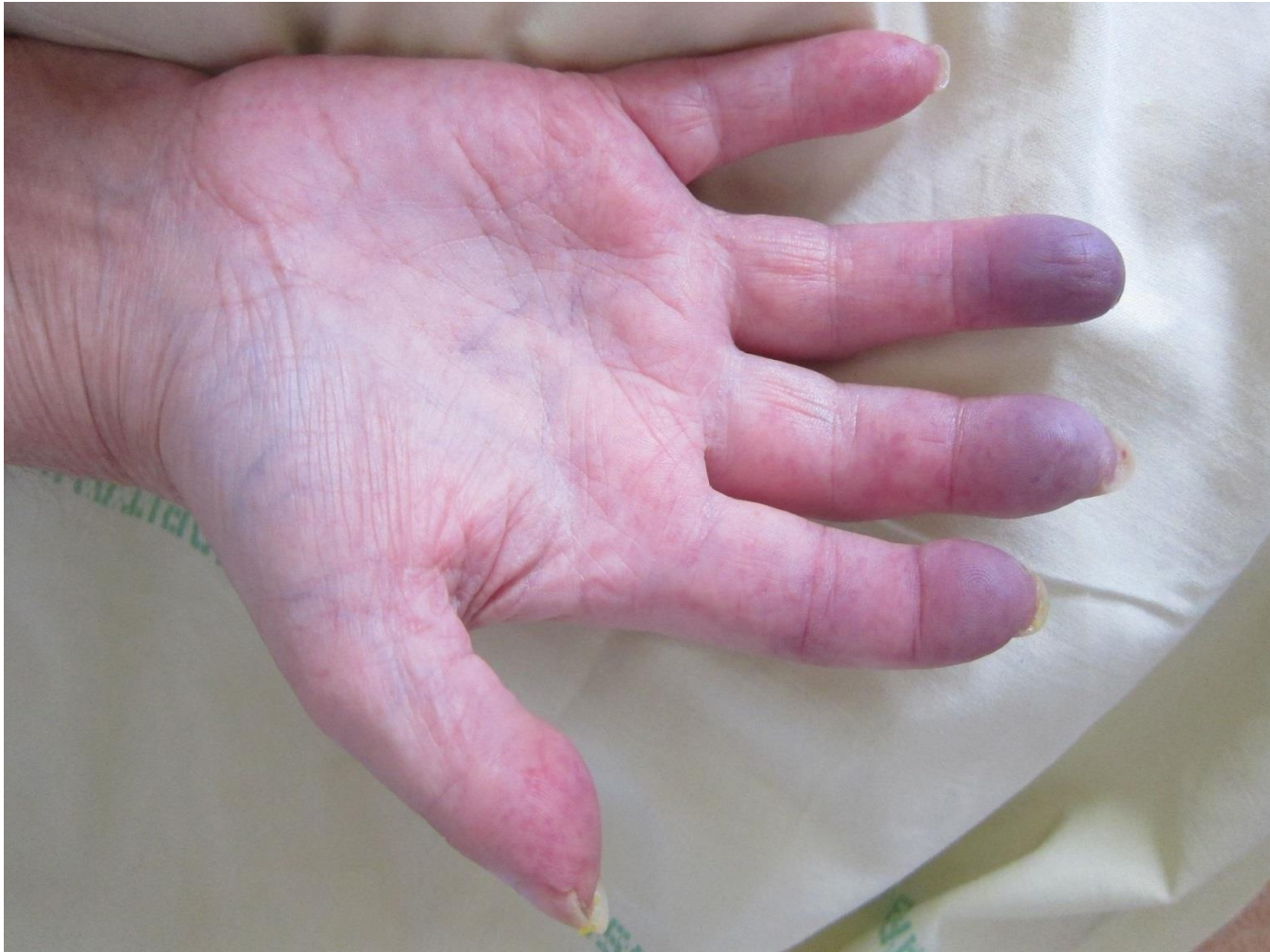Score = 4

Only count higher score



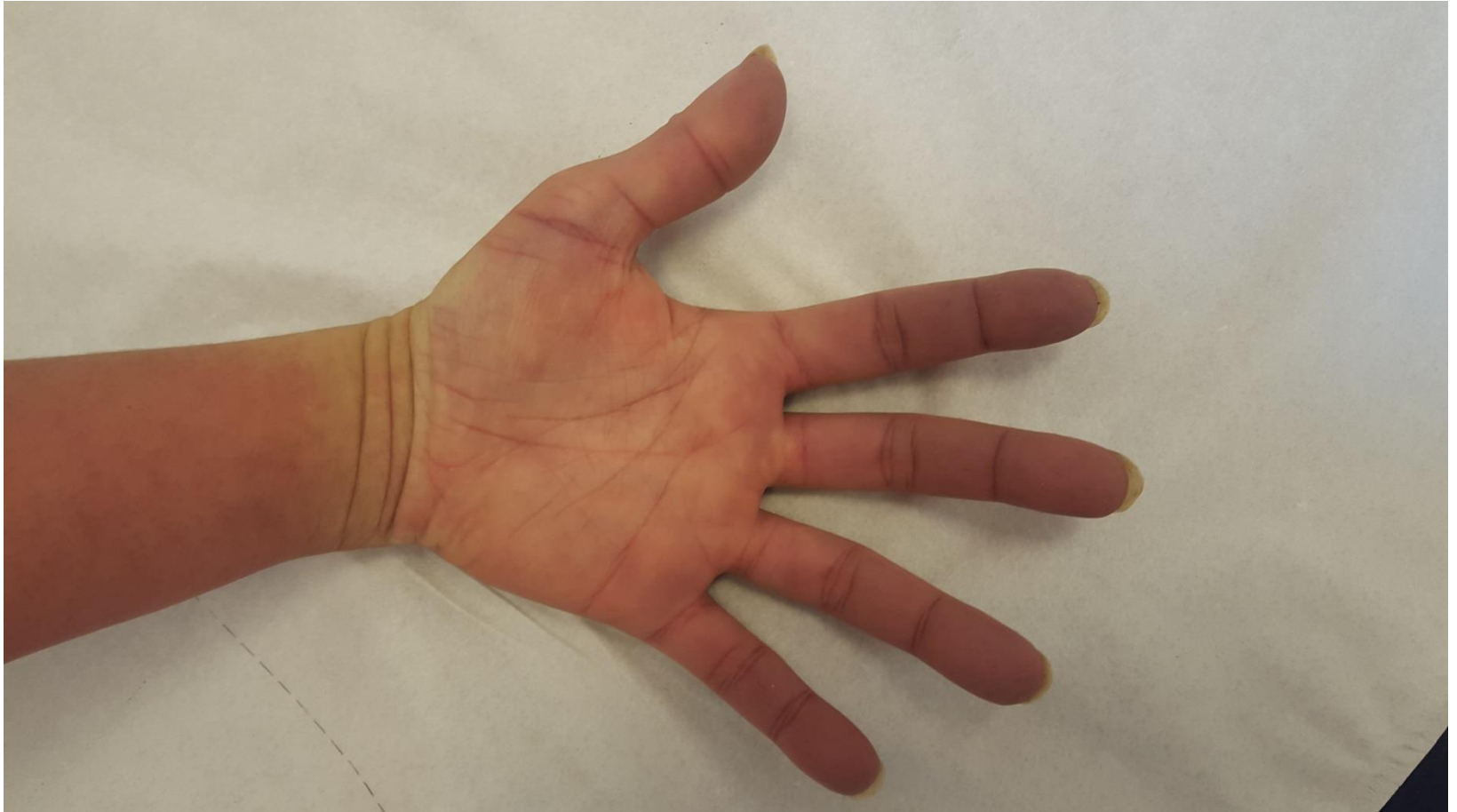

Raynaud's phenomenon

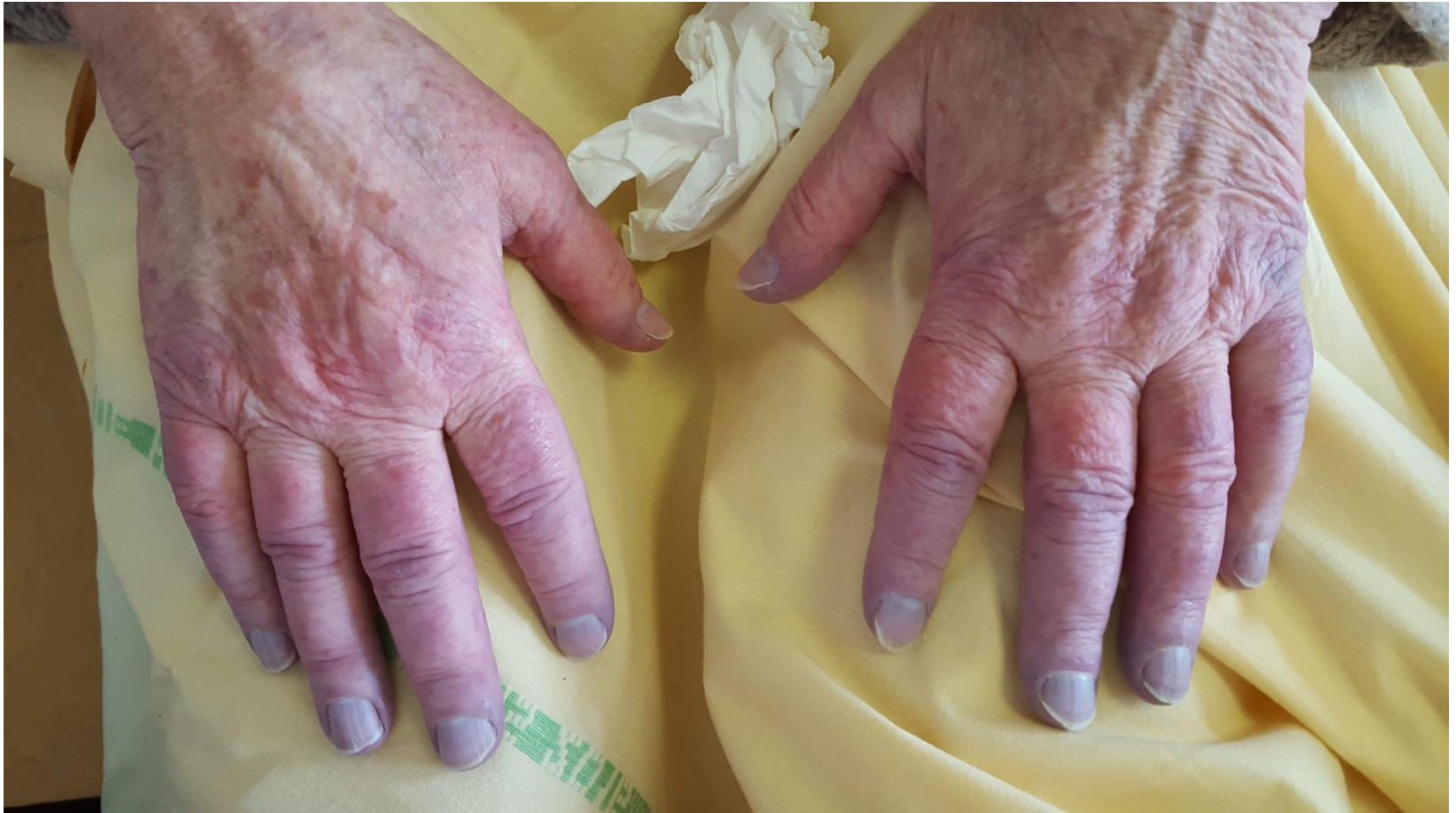

Score = 3

Raynaud's phenomenon



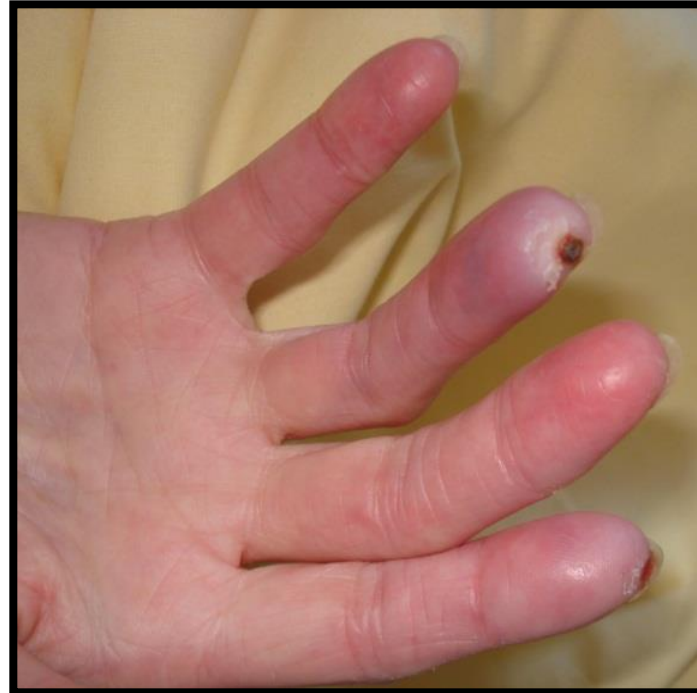Cyanosis



fingertip lesions

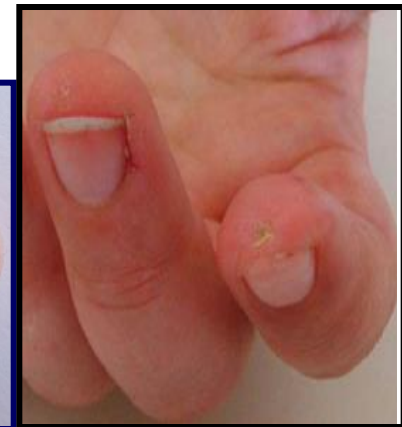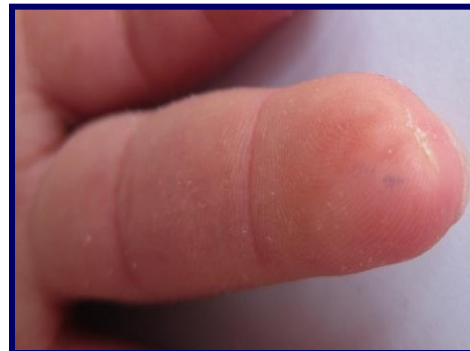Digital ulcers

Score = 2



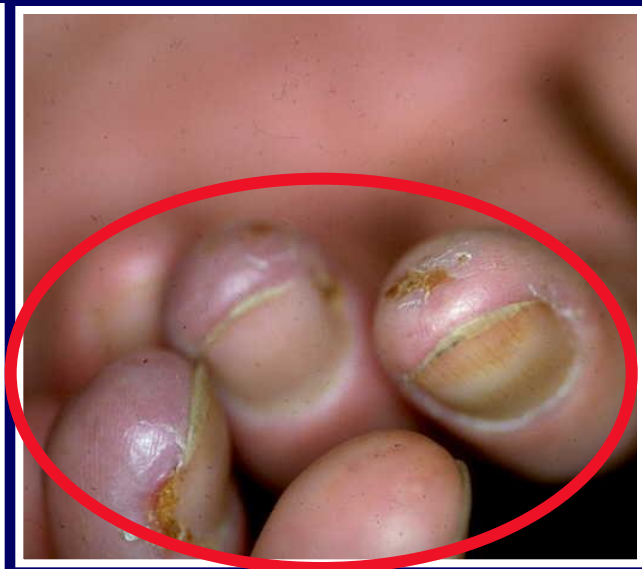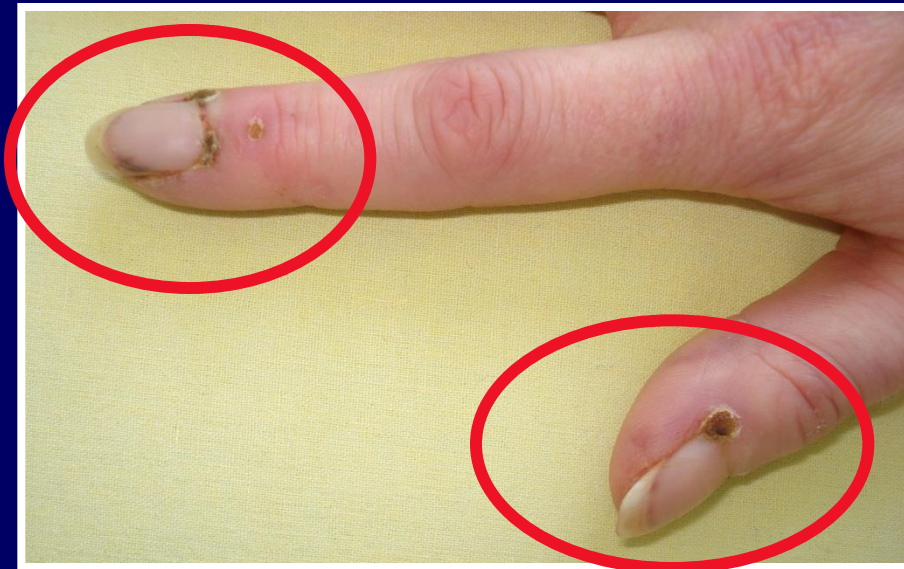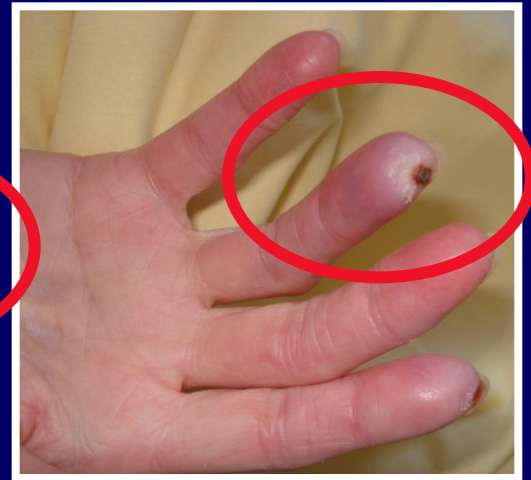
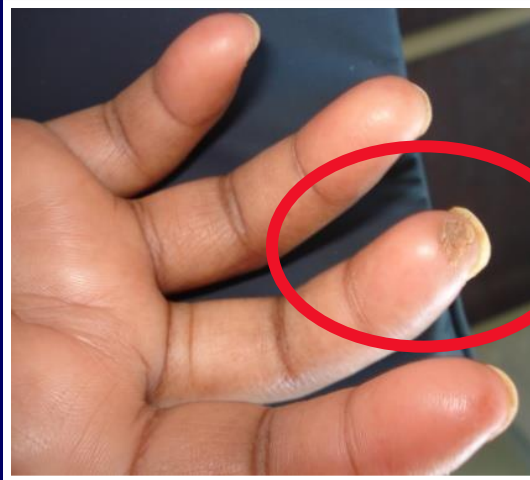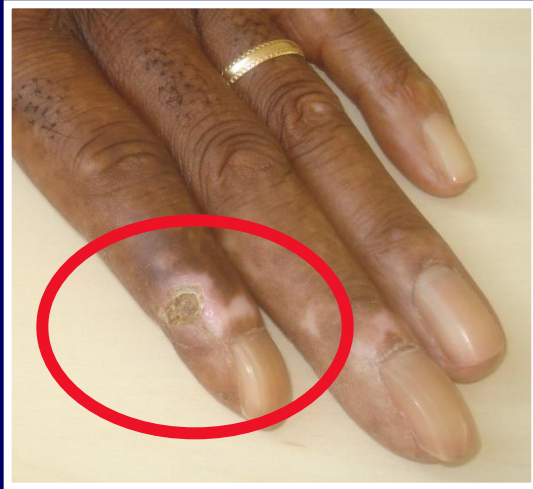Fingertip pitting scars

Score = 3

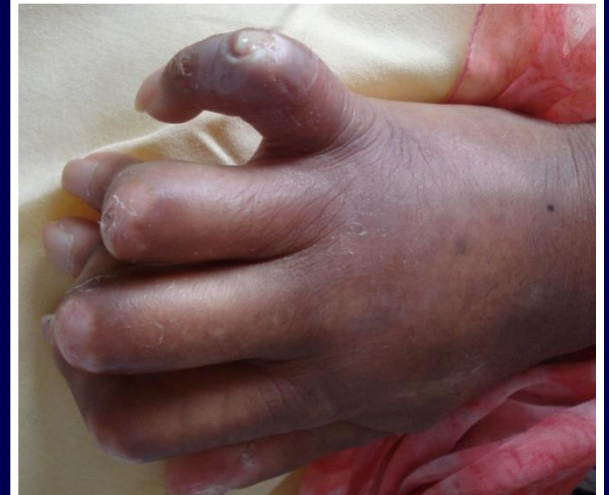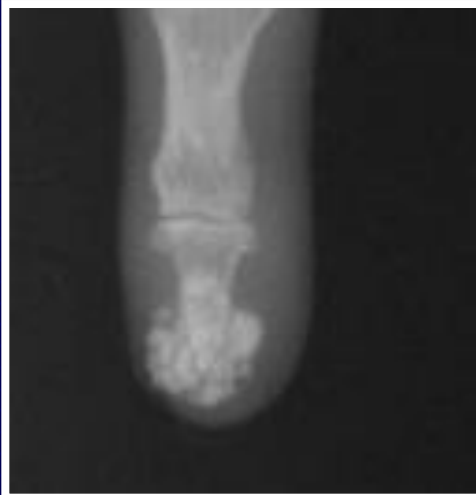
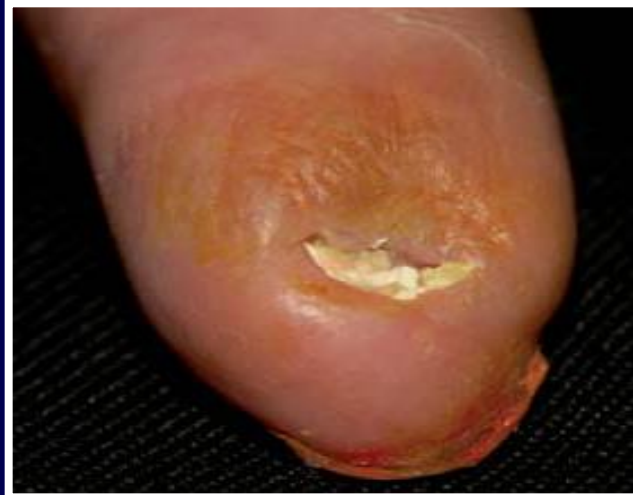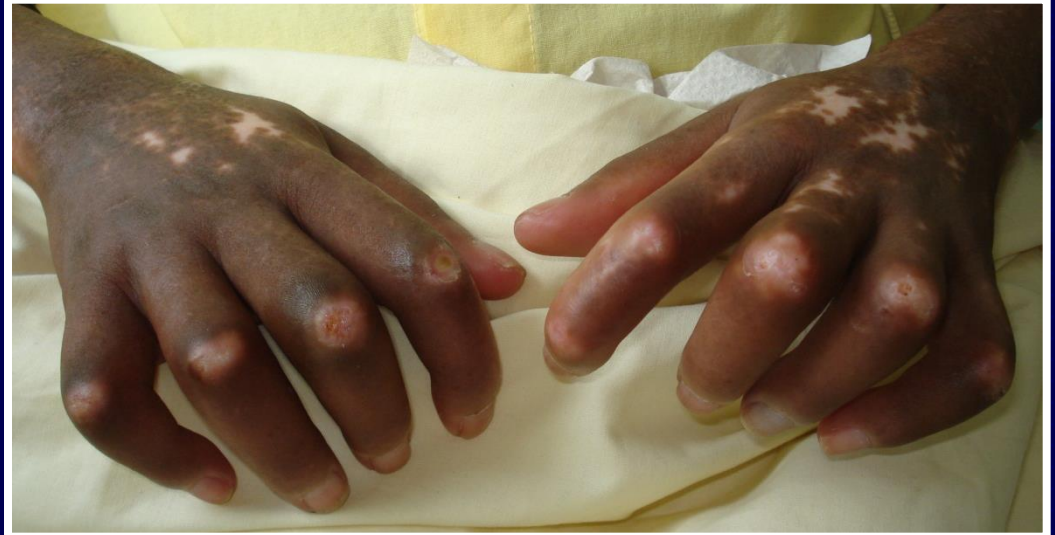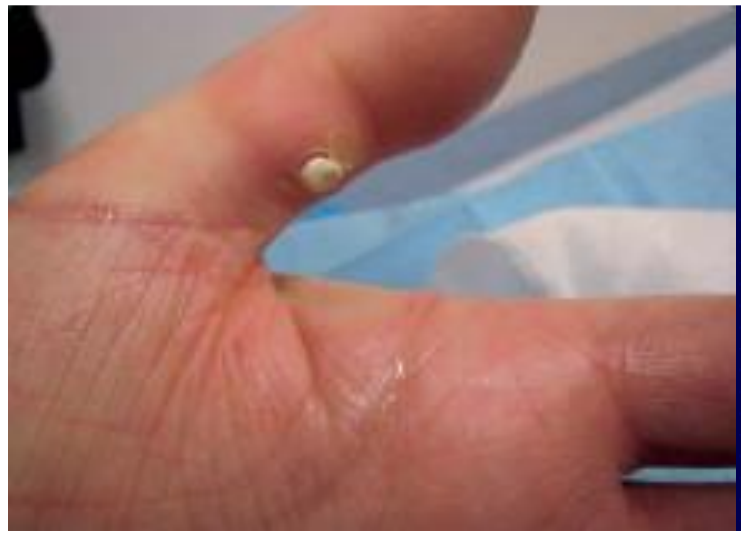


Only count higher score

Digital ulcers: Vascular mechanisms

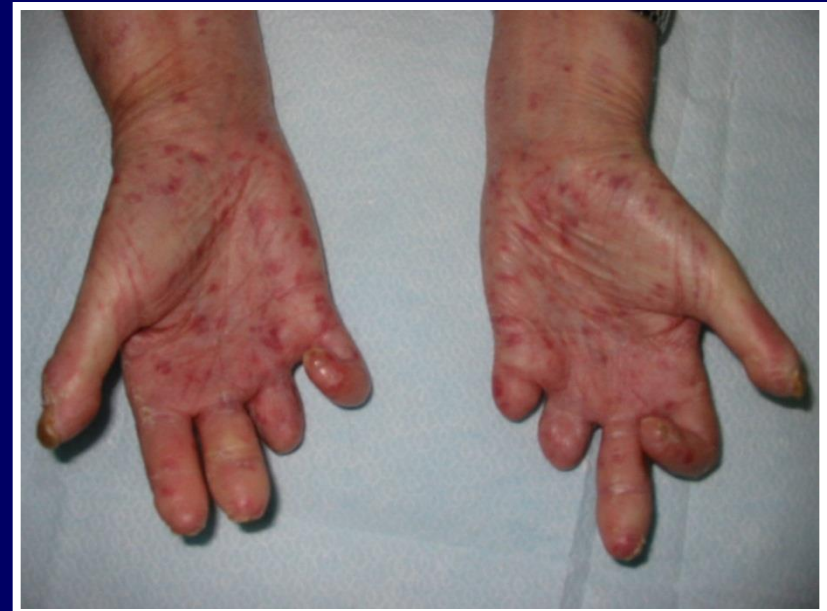
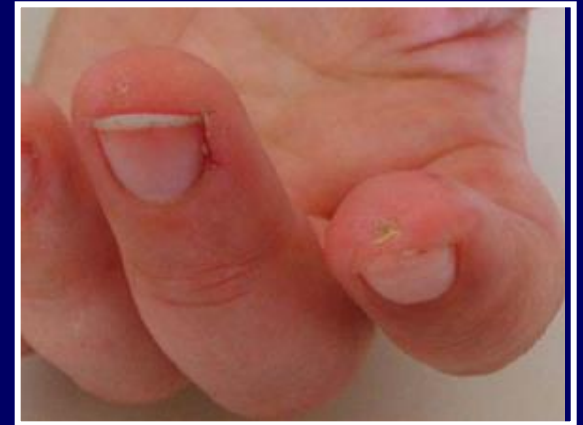
Calcinosis/mechanical

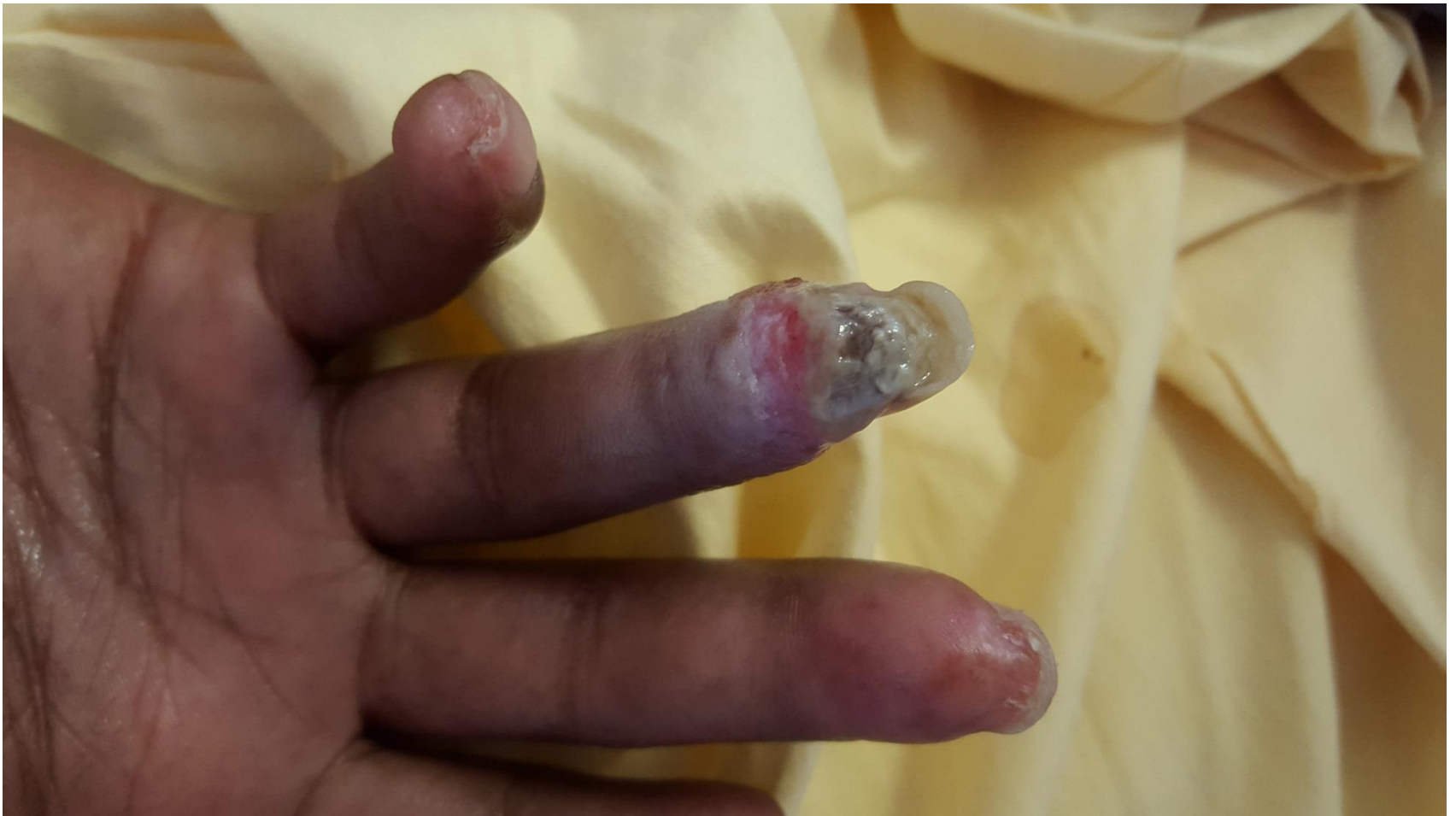

Digital ulcers: Healing

- ◆ Time to healing: Not well documented
- ◆ 30% sequelae
- ◆ Loss of substance
- ◆ Pitting scar
- ◆ Auto-amputation
- ◆ Surgical amputation

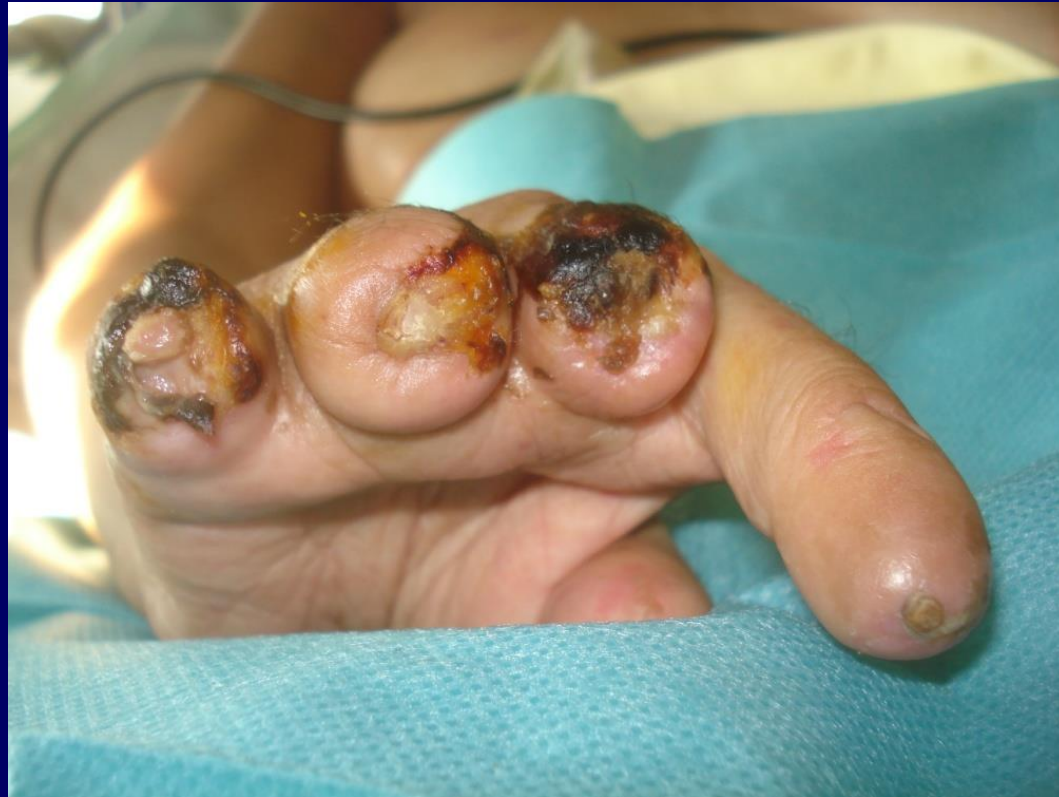
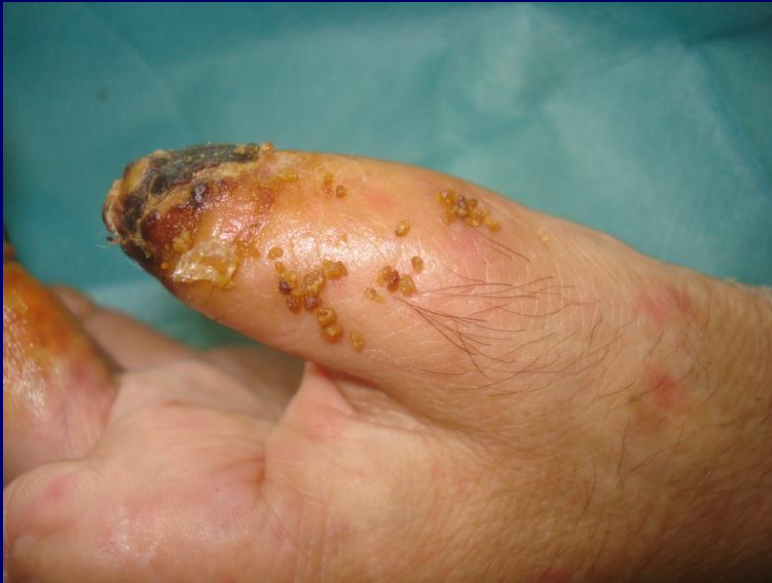
Digital ulcer/necrosis superinfection



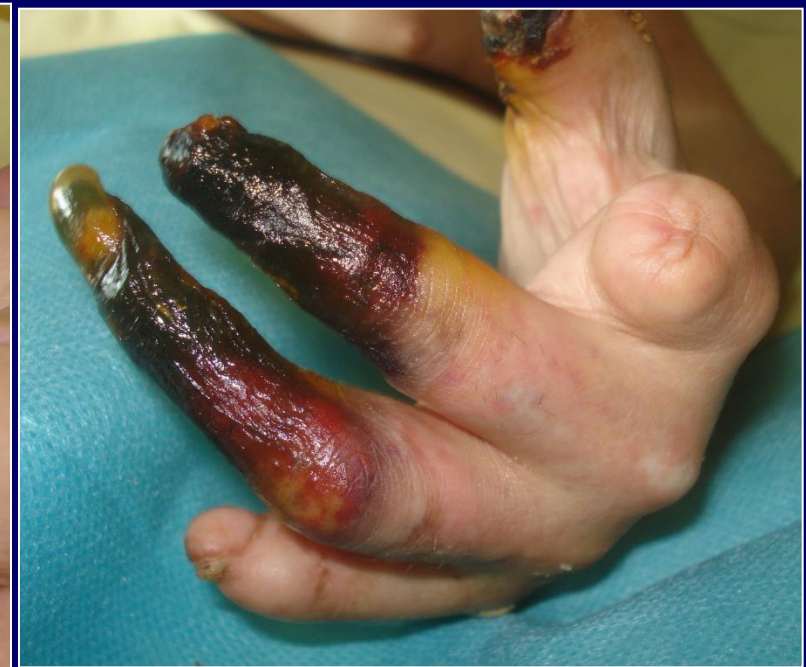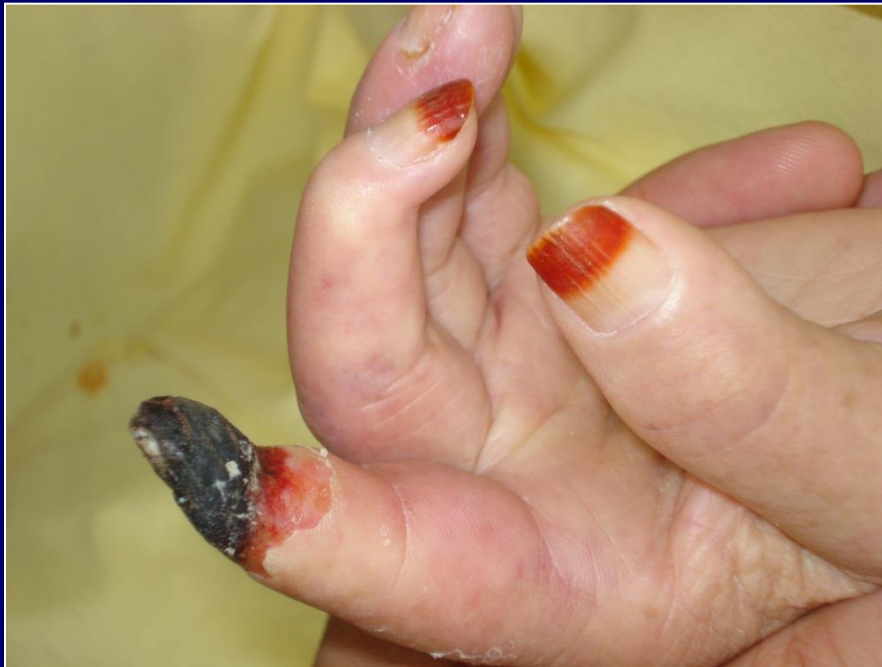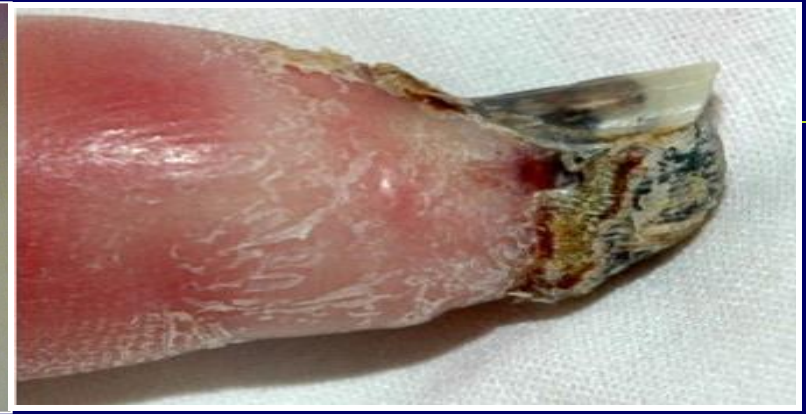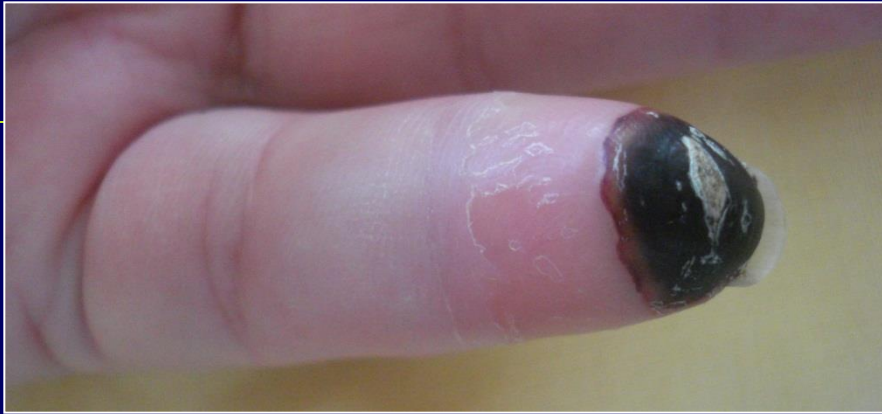Digital ulcers: Infection

- ◆ 1/3 infections
- ◆ 10% osteomyelitis
- ◆ Delayed healing++++



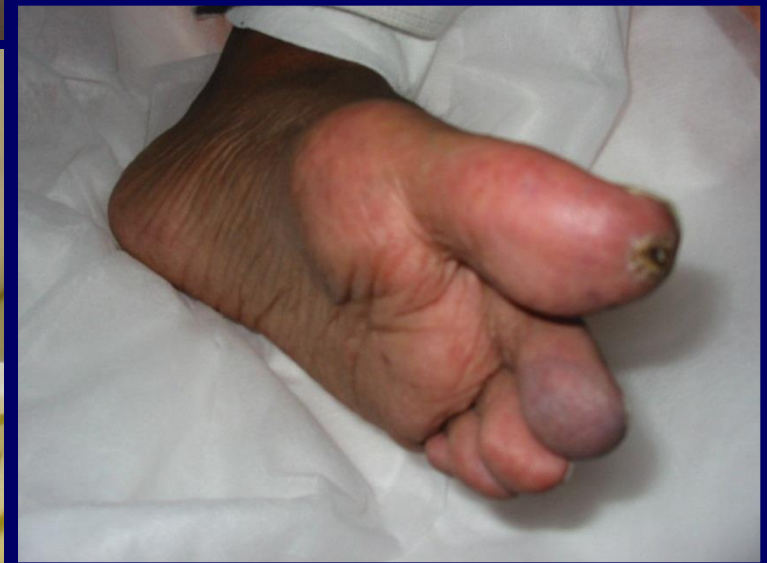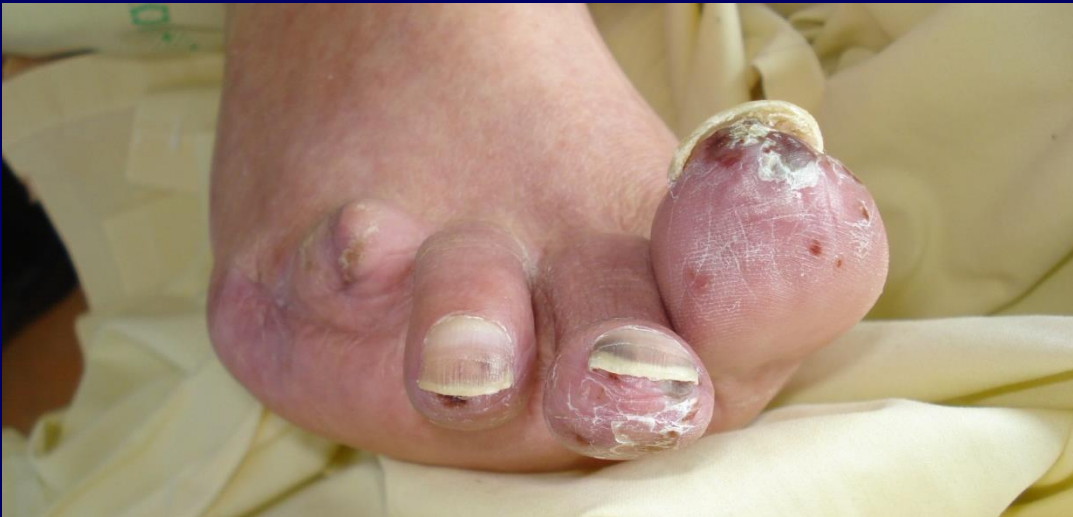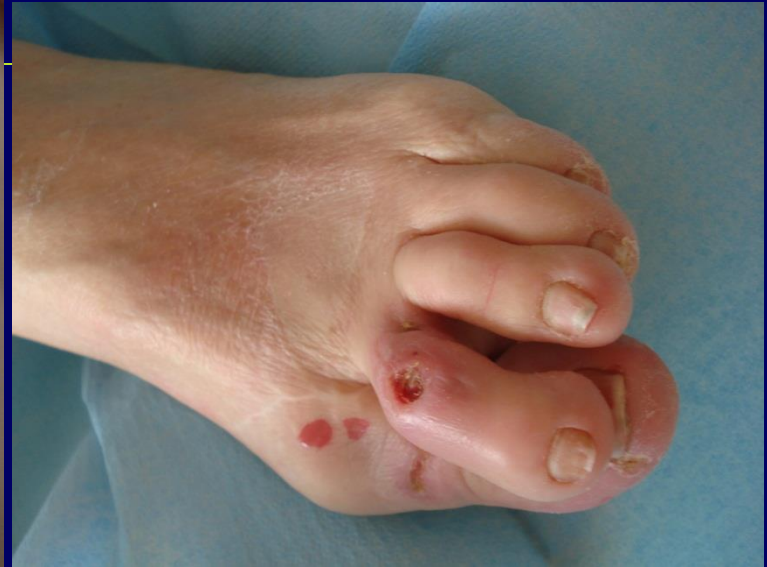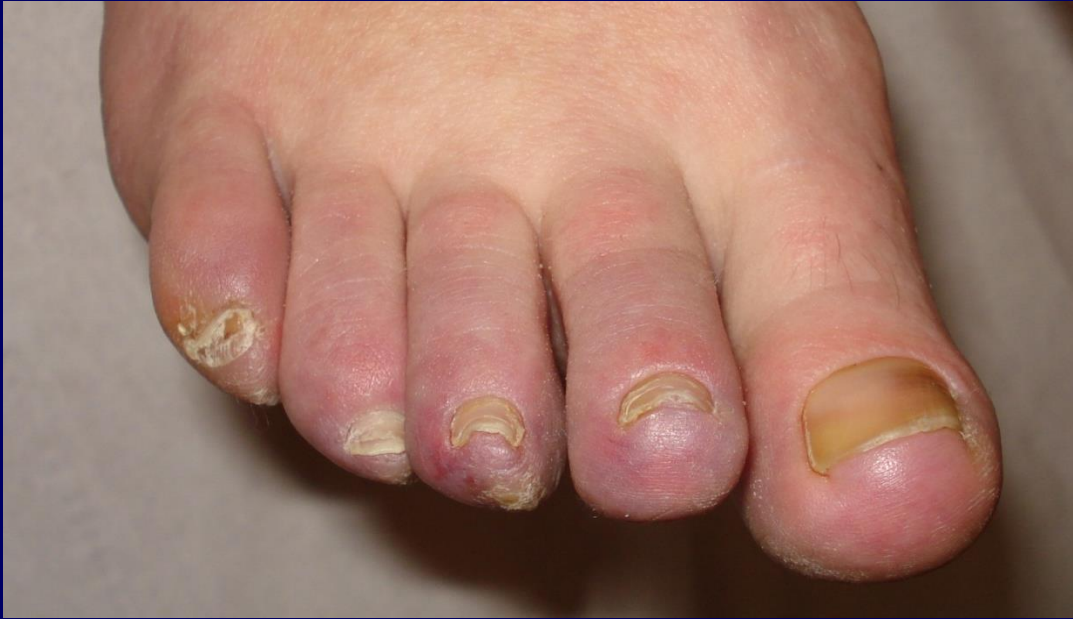Hachulla E, et al. *J Rheum* 2007; 34:2423-30.
Nihtyanova SI, et al. *Ann Rheum Dis* 2008; 67:120-3.

Digital necrosis/gangrene

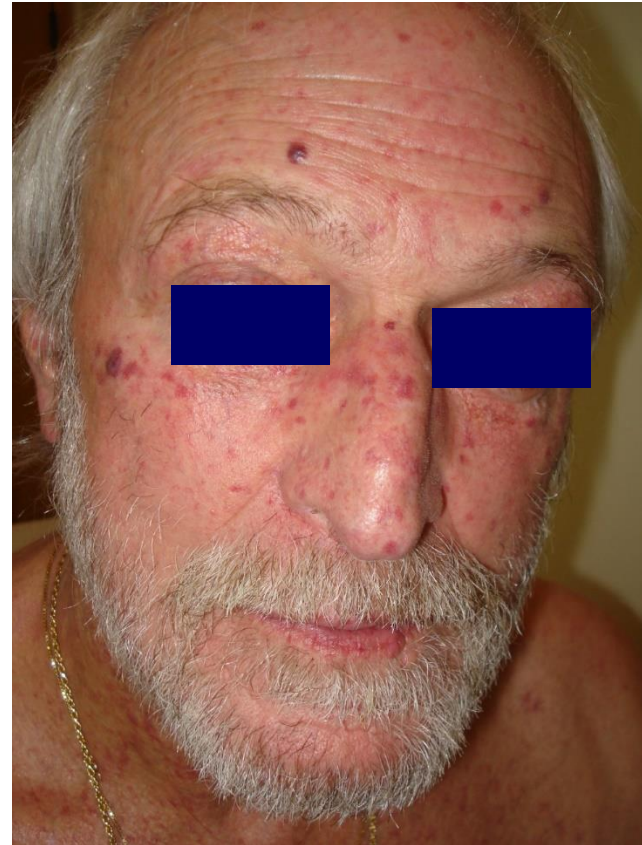
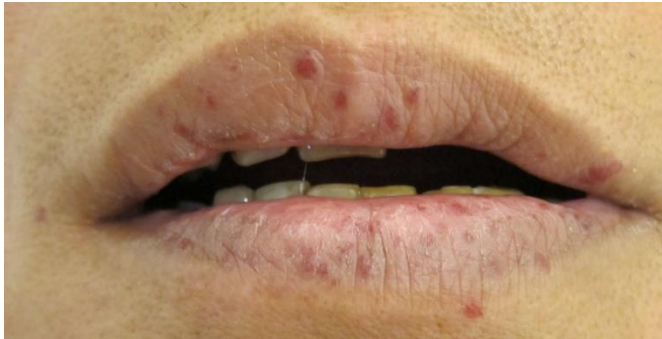
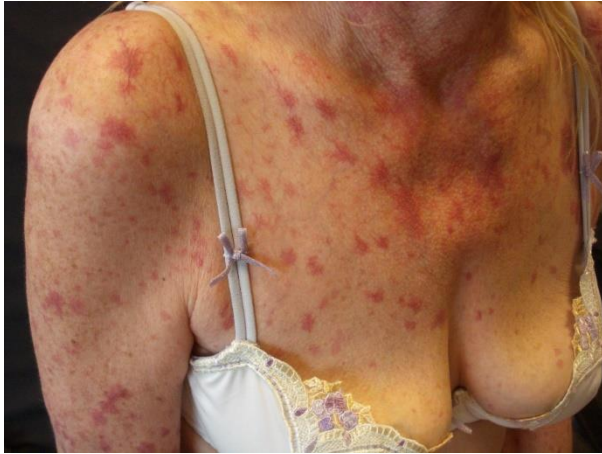—————> Perform arterial doppler

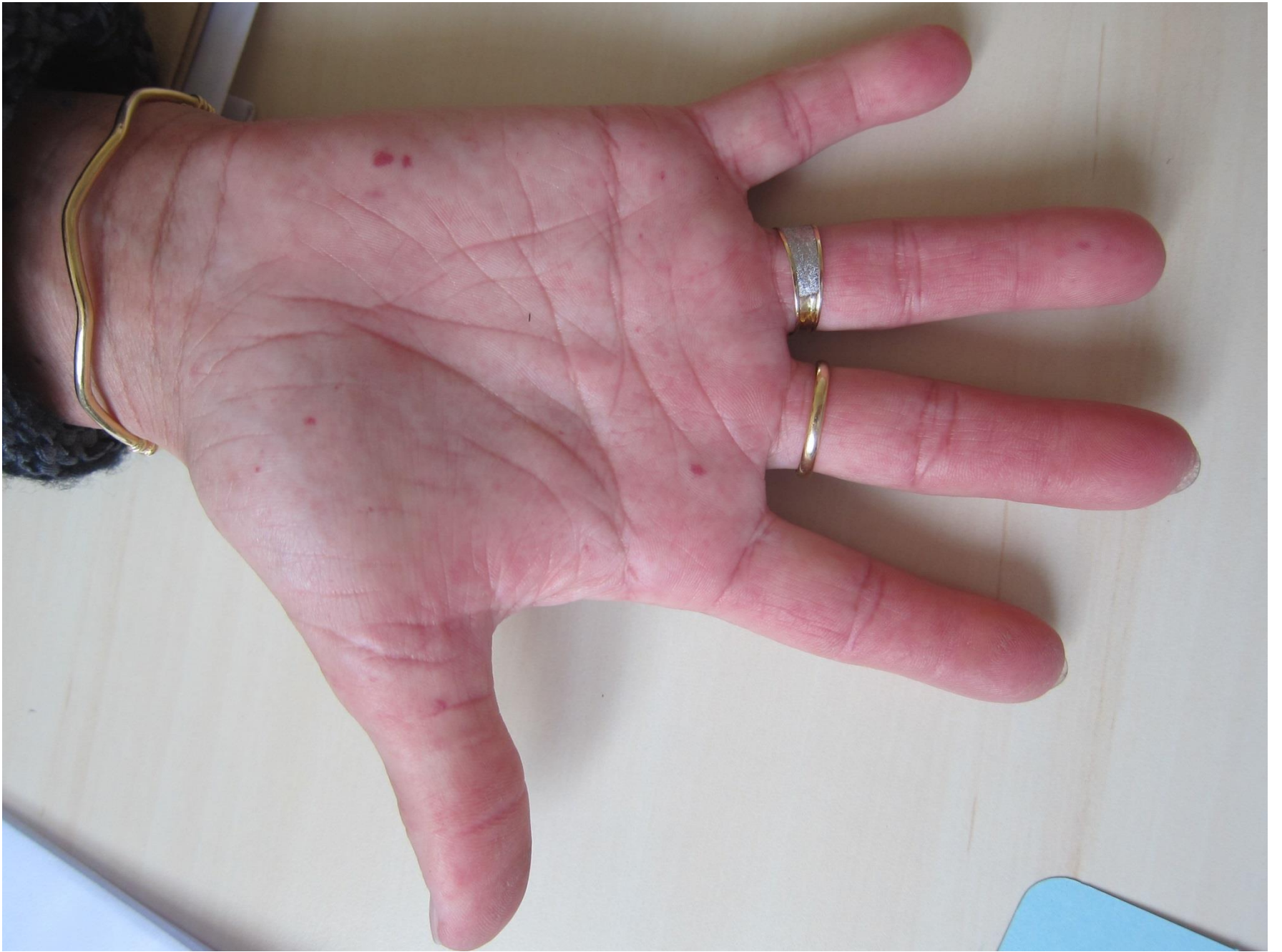Digital ulcers: Also on the feet!



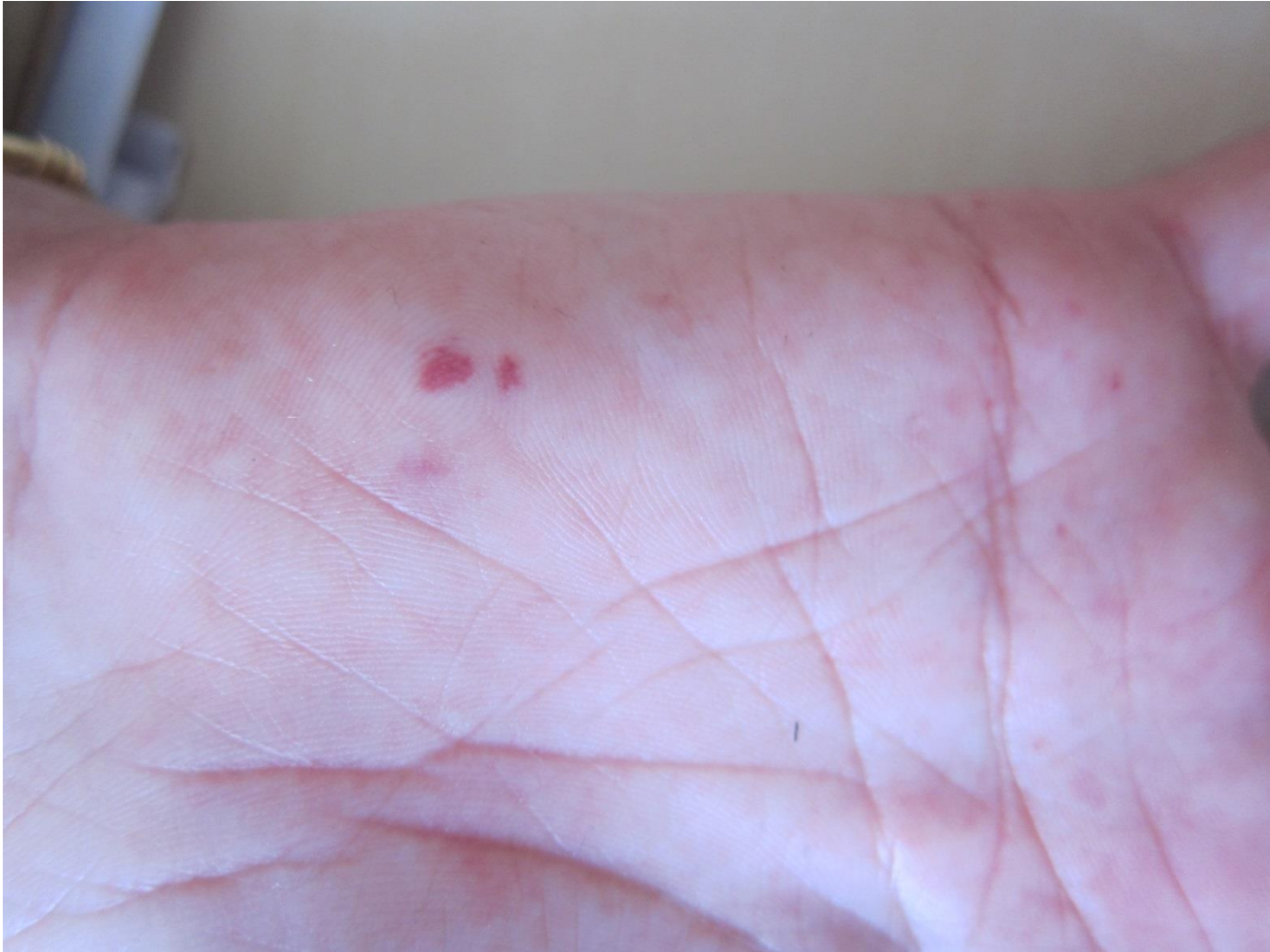telangiectasia



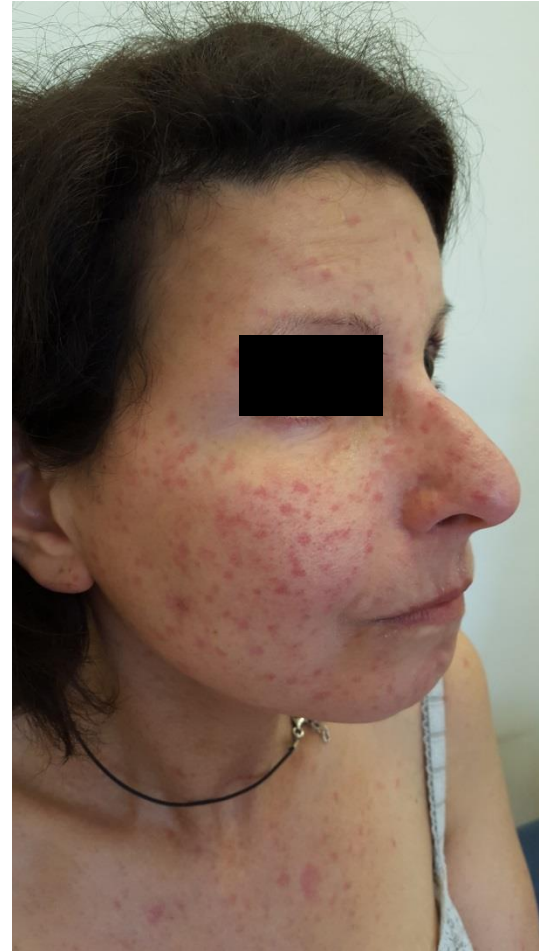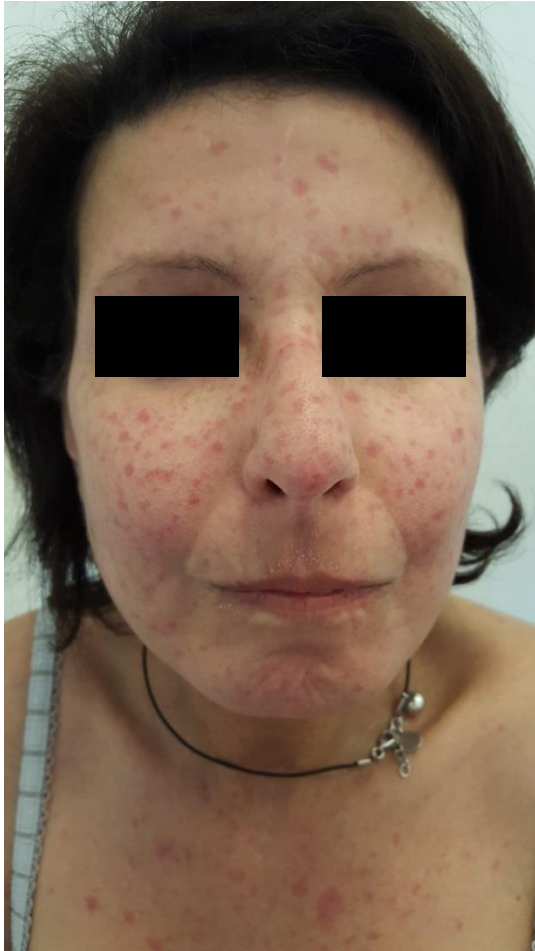Score = 2



telangiectasia

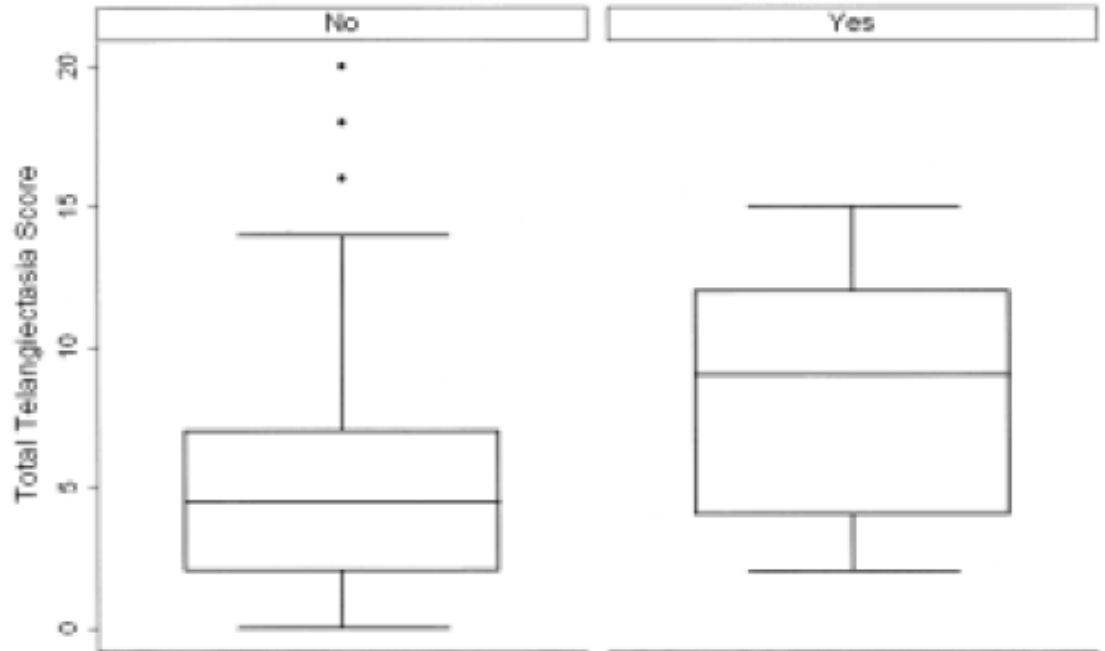
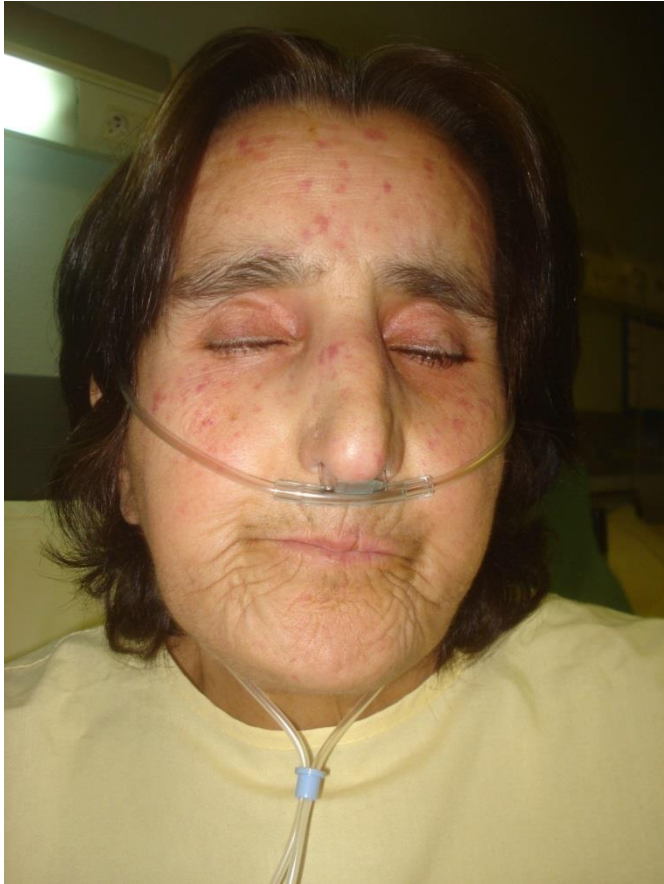

telangiectasia



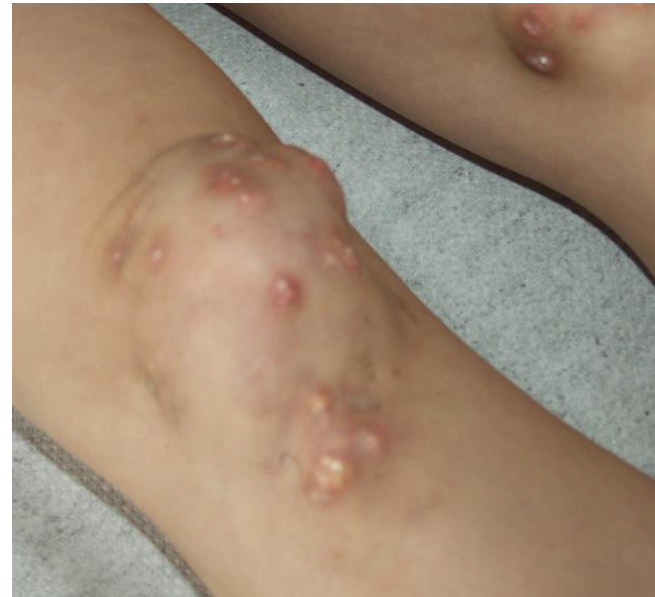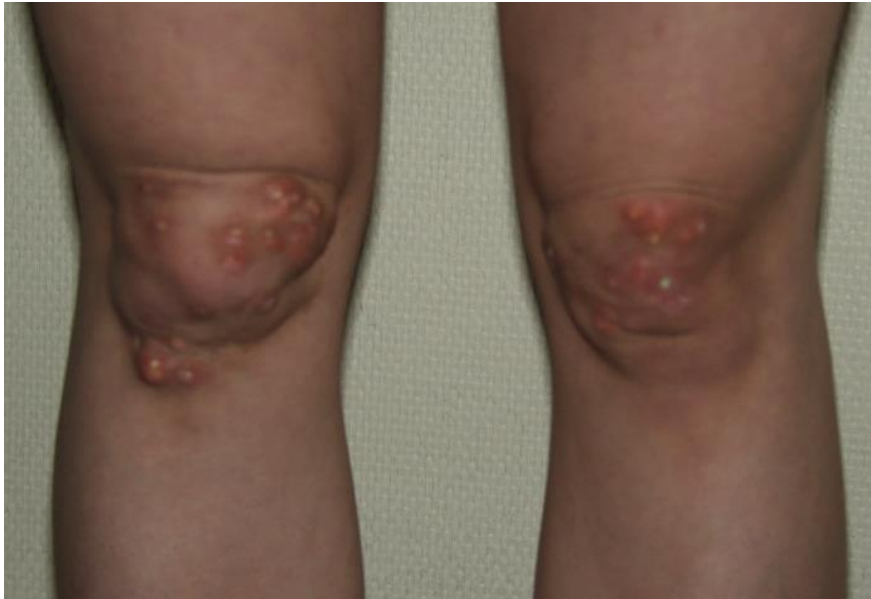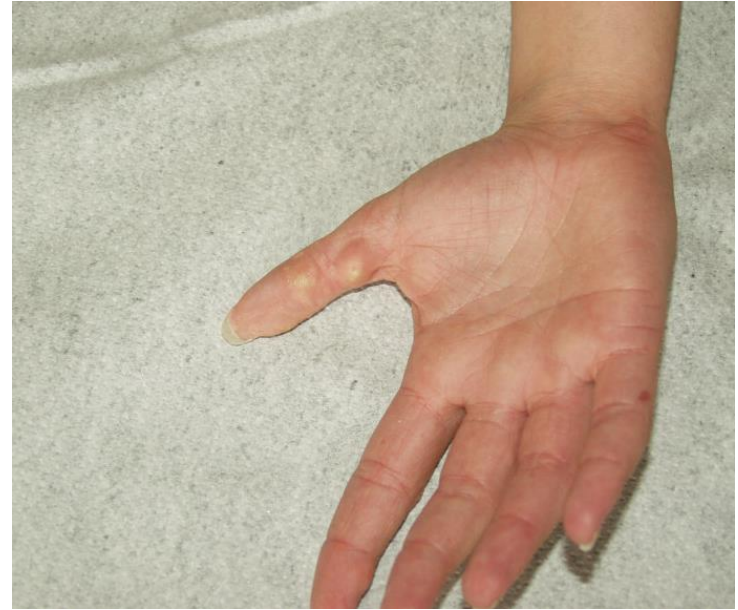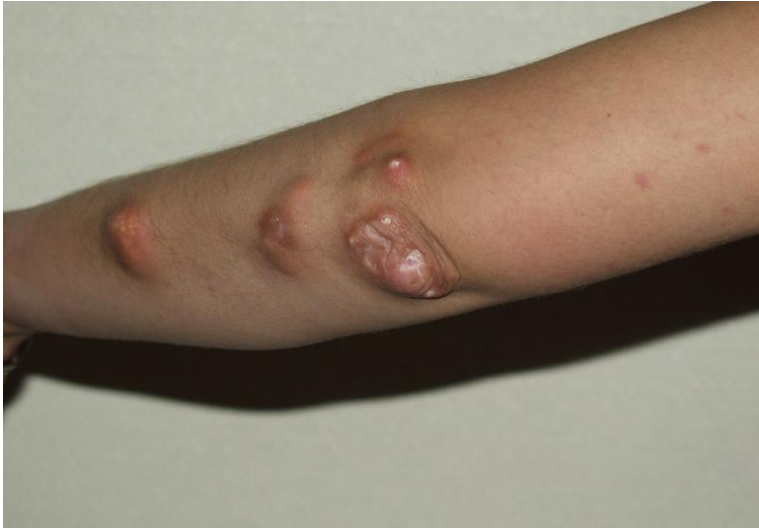Telangiectases in Scleroderma: A Potential Clinical Marker of Pulmonary Arterial Hypertension

Shah et al. J Rheumatol 2010

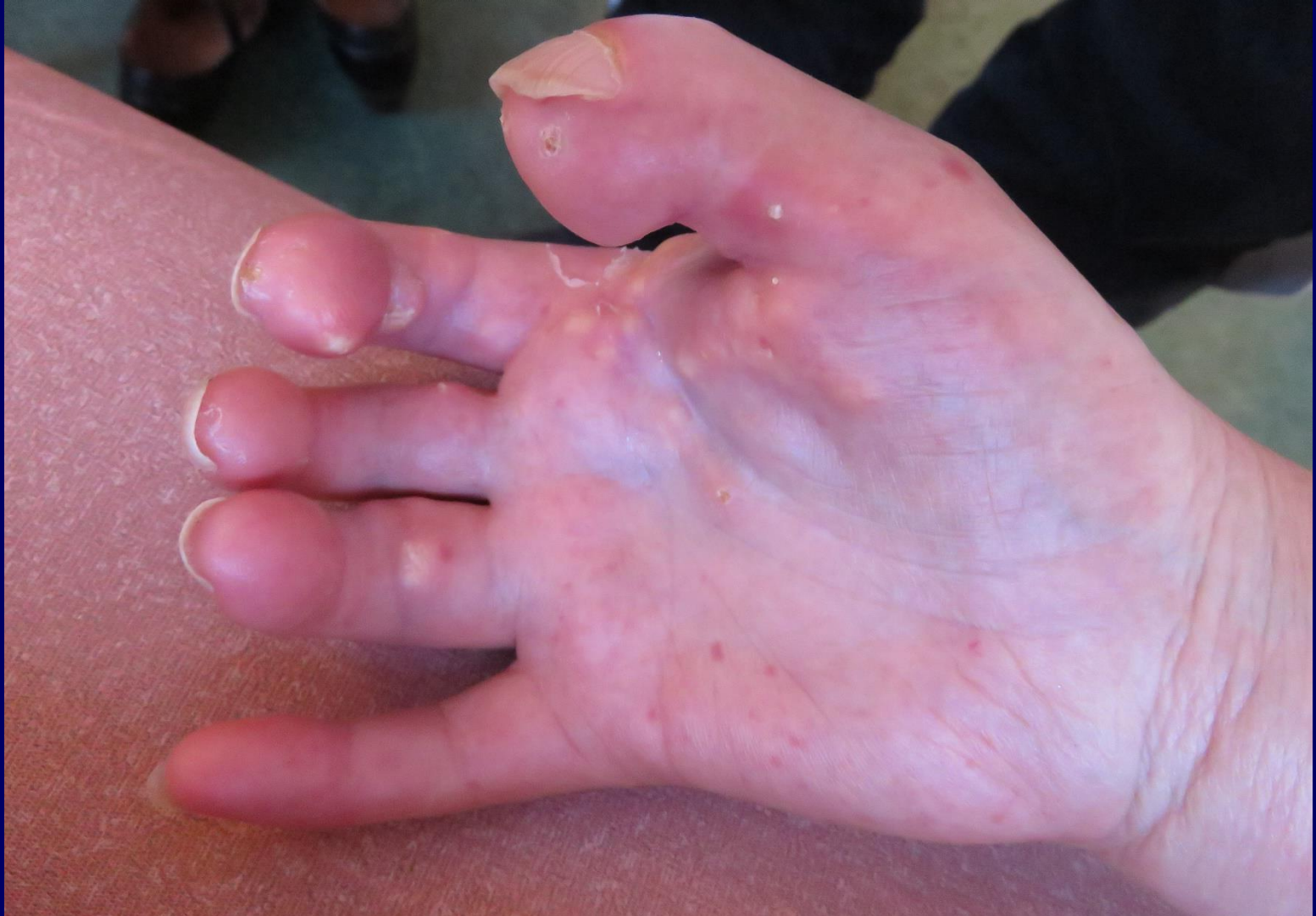

Graphs by PAH on Echocardiogram (RVSP > 45 mmHg) or Right Heart Catheterization

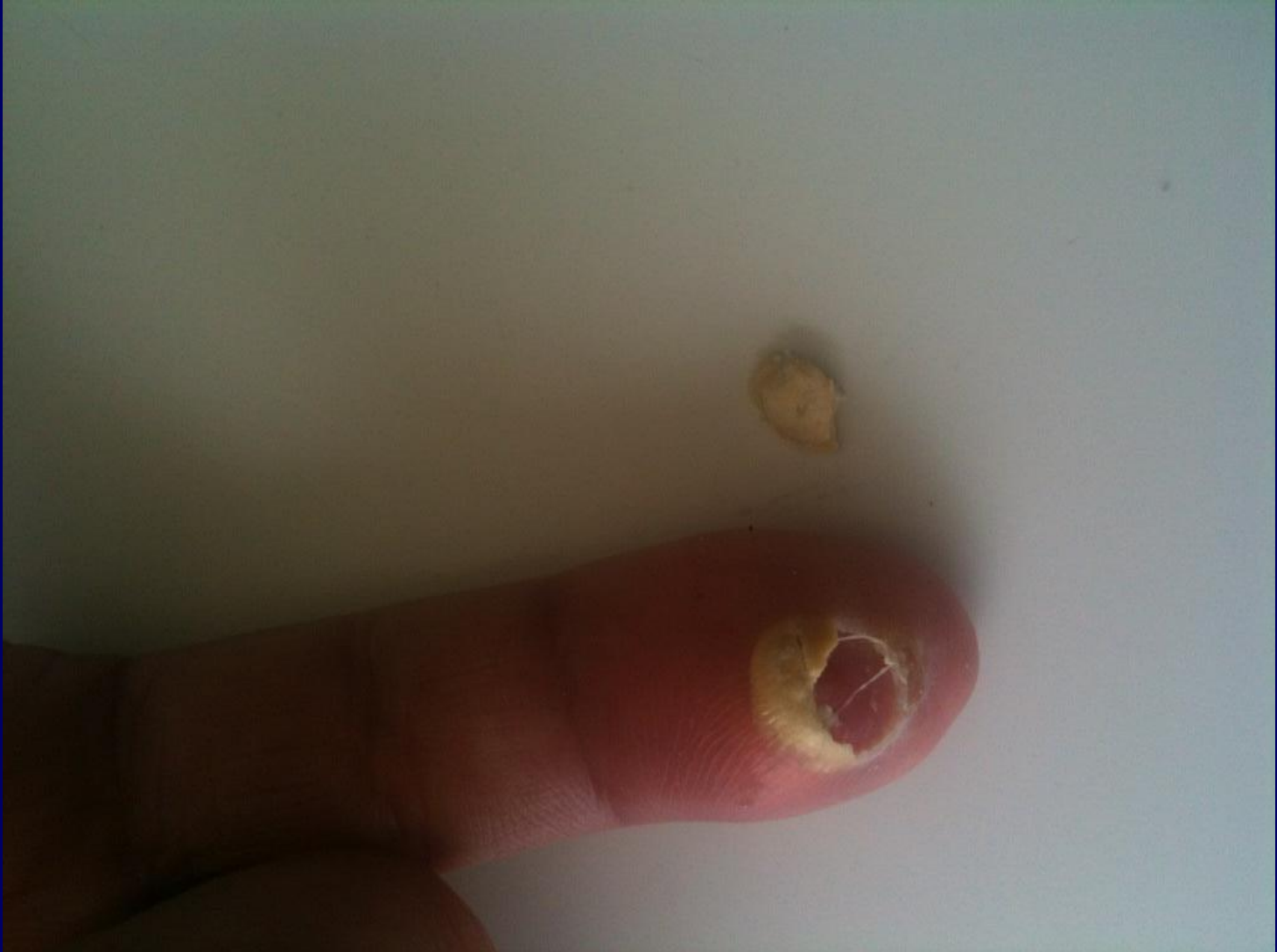Calcinoses



Calcinosis: major disability

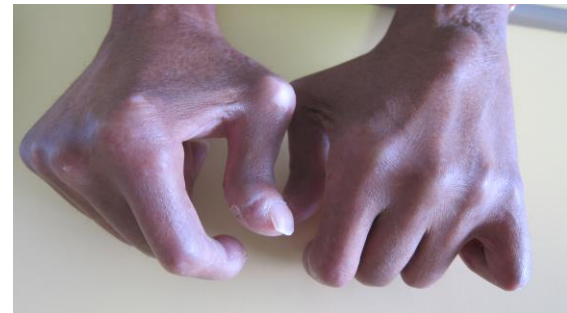
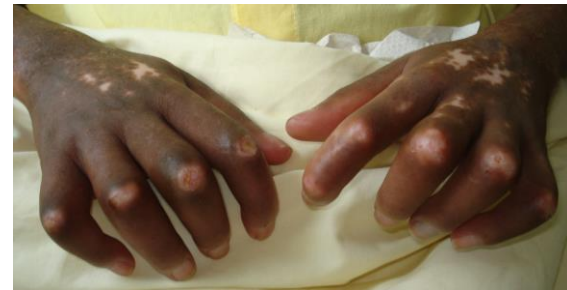
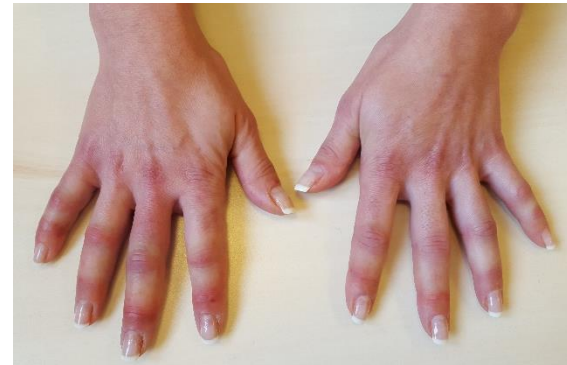Calcinosis: spontaneous elimination

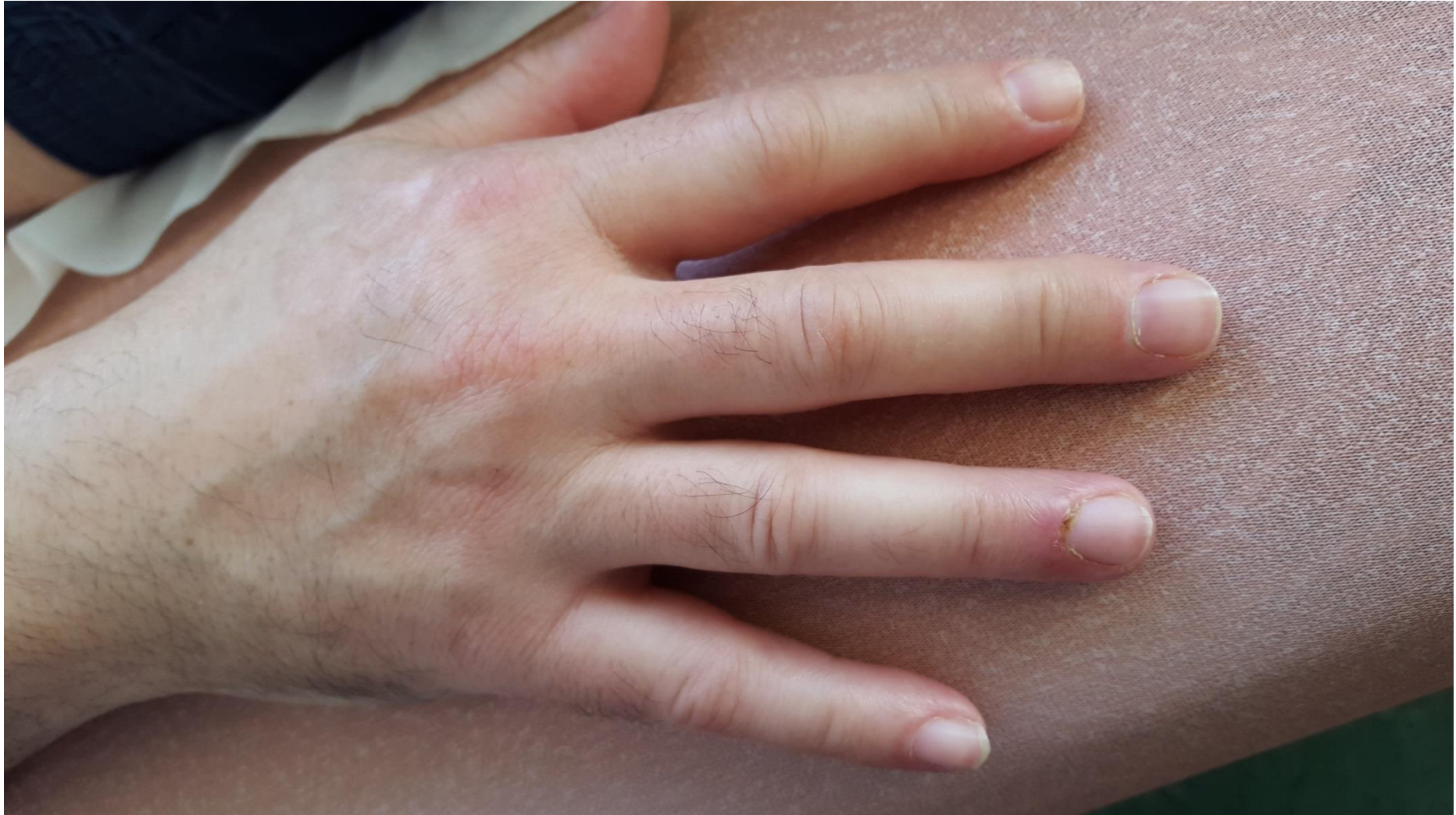

Atteinte de la main dans la ScS

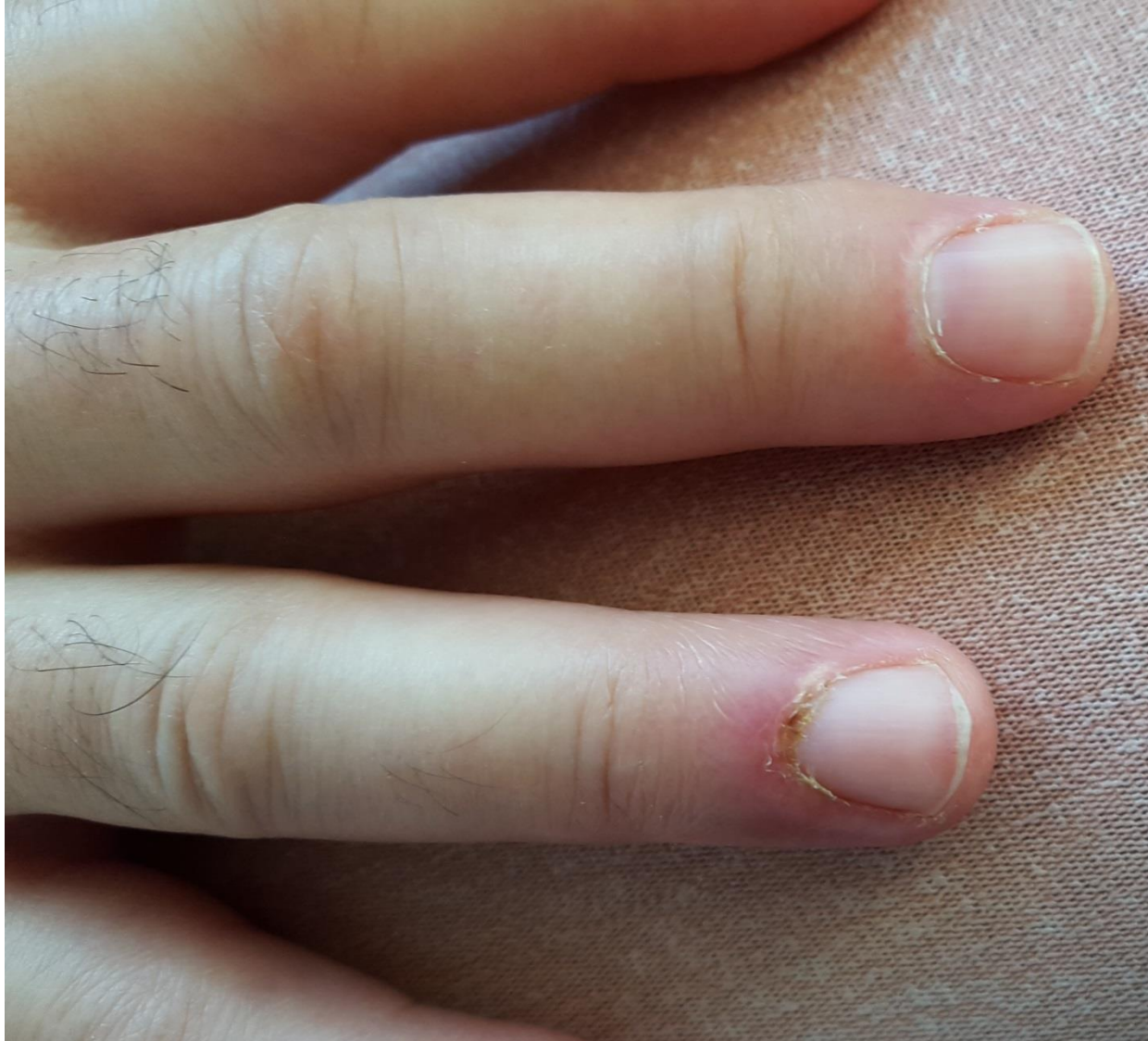- Trois phases
 - Phase oedémateuse (ScS diffuse)
 - Phase scléreuse
 - Phase atrophique: la peau devient atrophique et les déformations augmentent



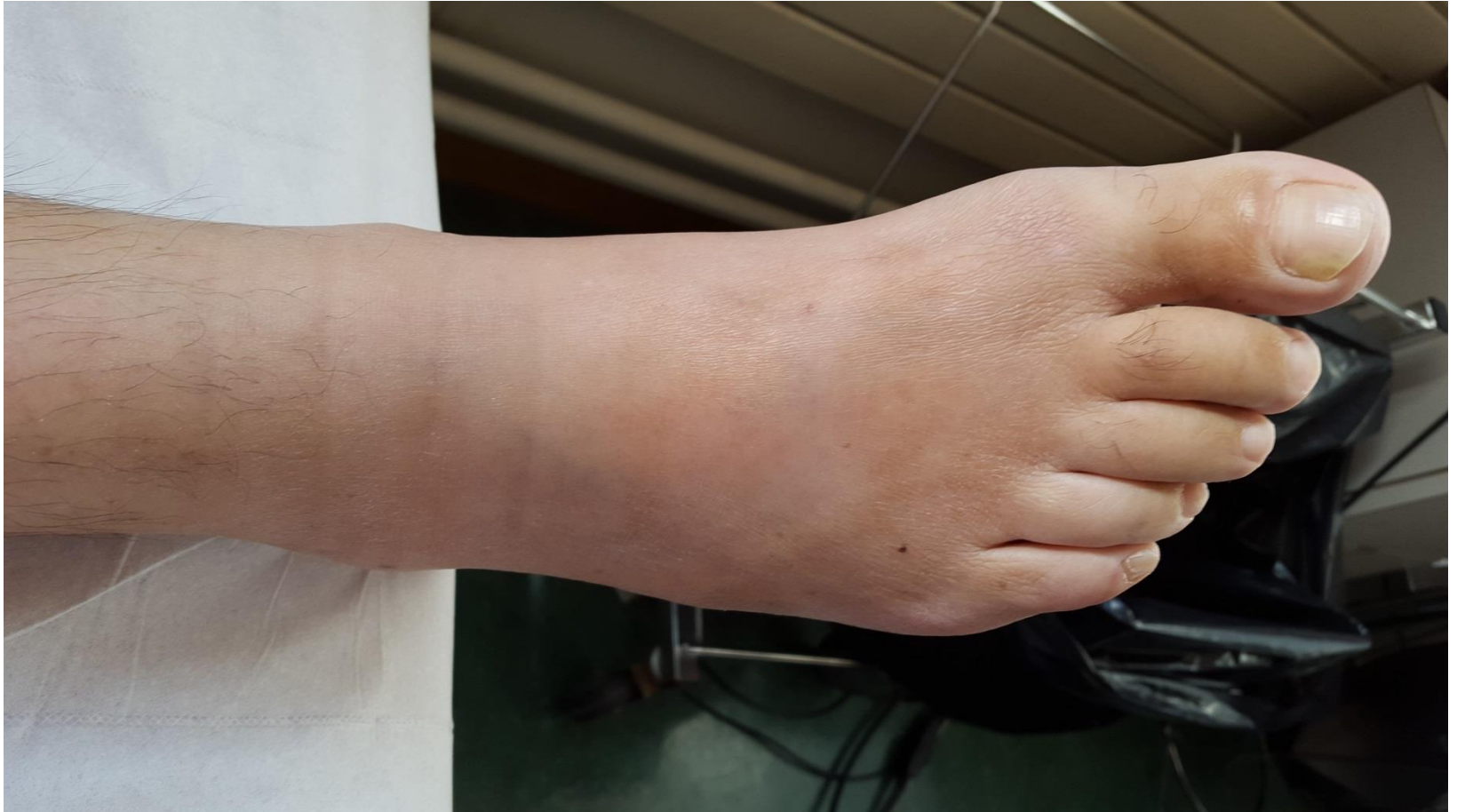ScS œdémateuse débutante



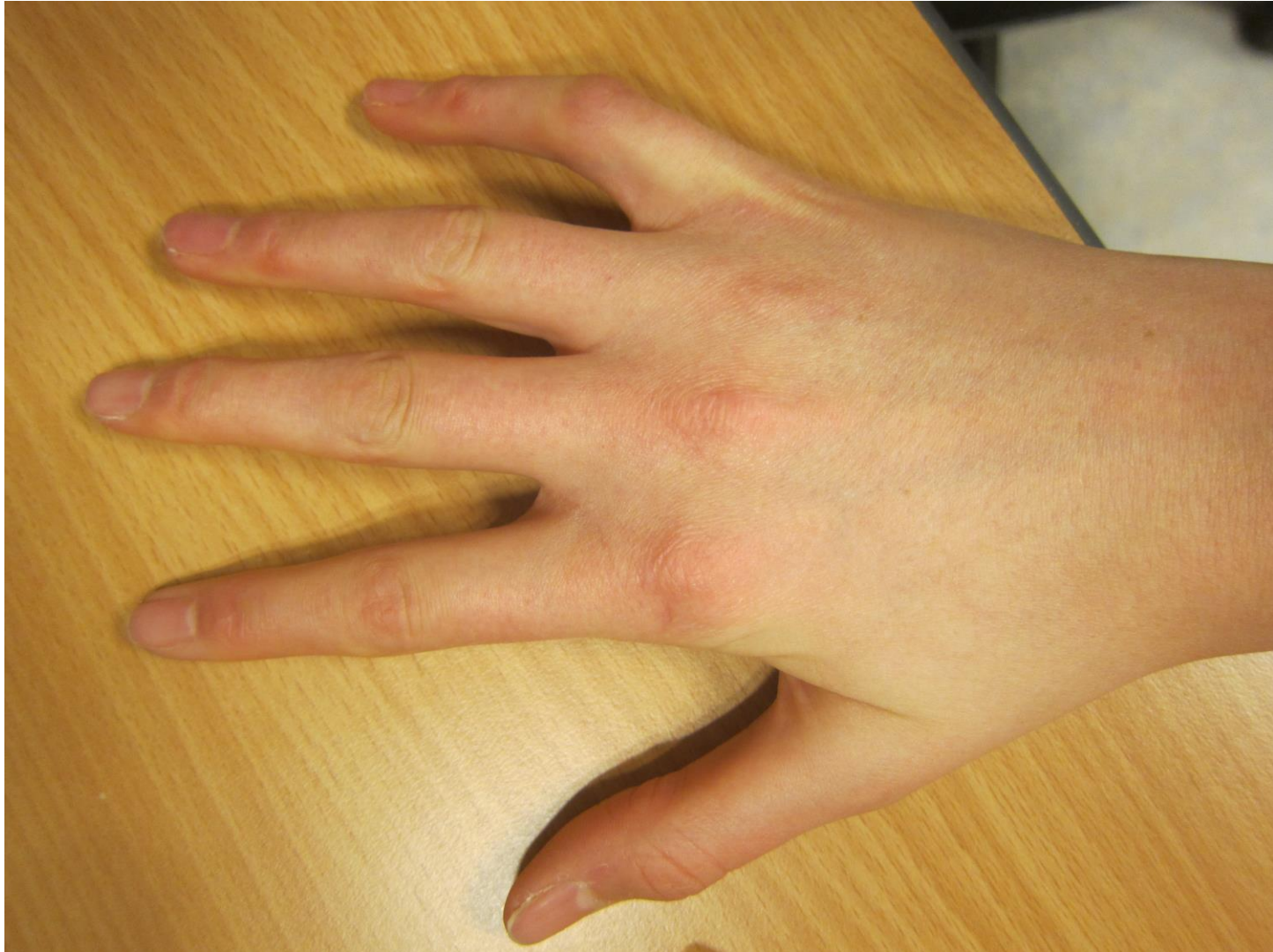ScS œdémateuse débutante



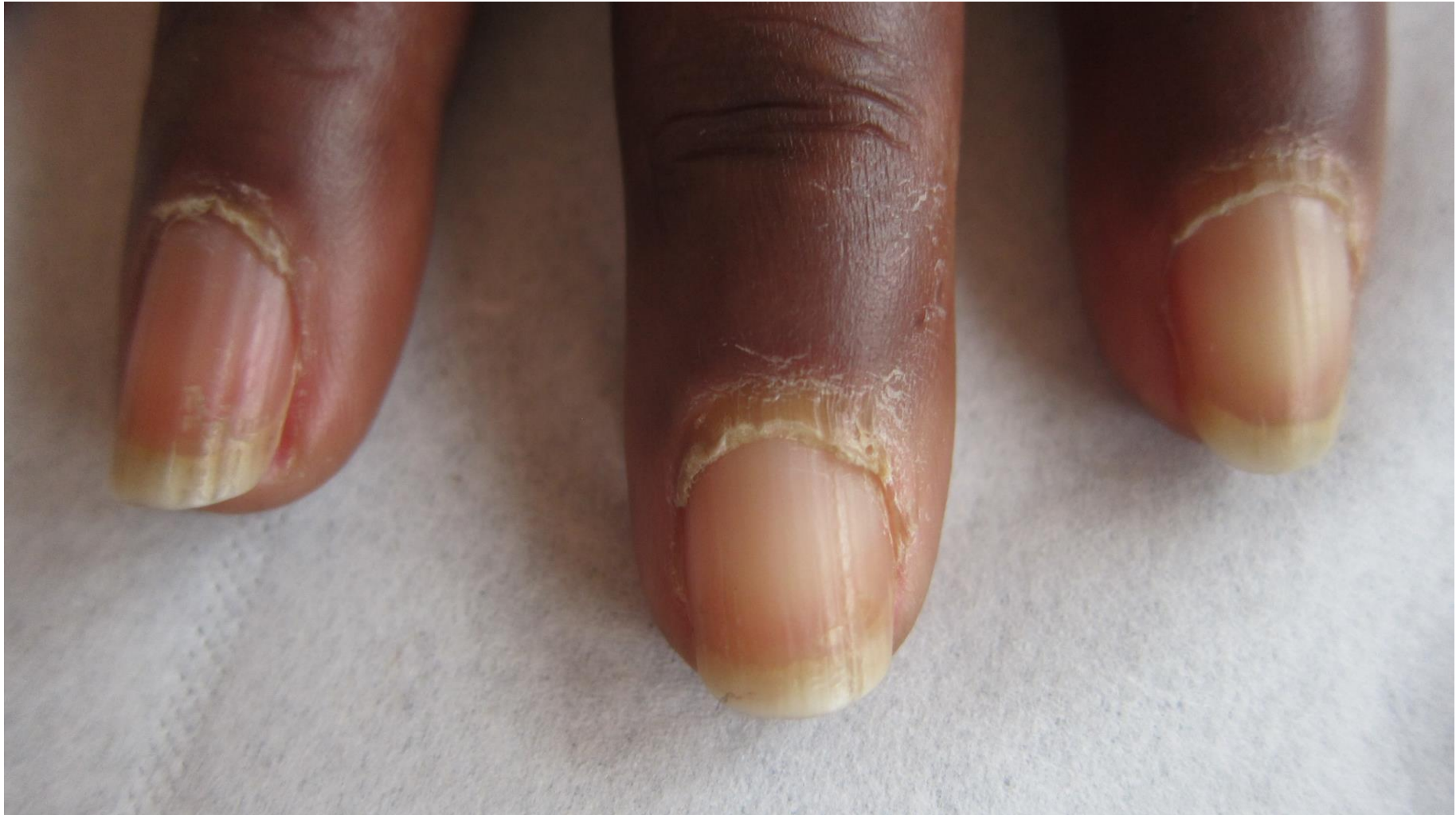ScS œdémateuse débutante

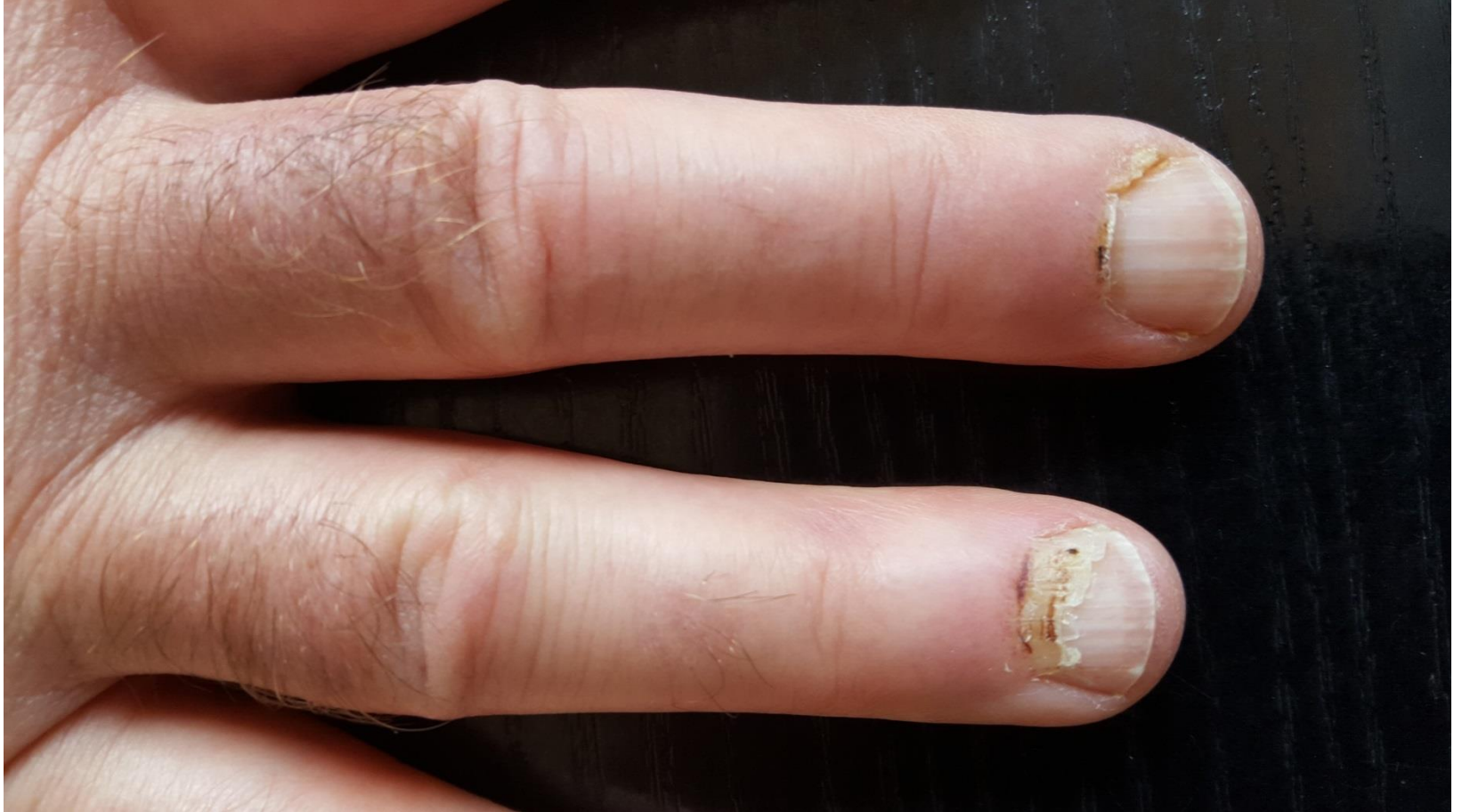

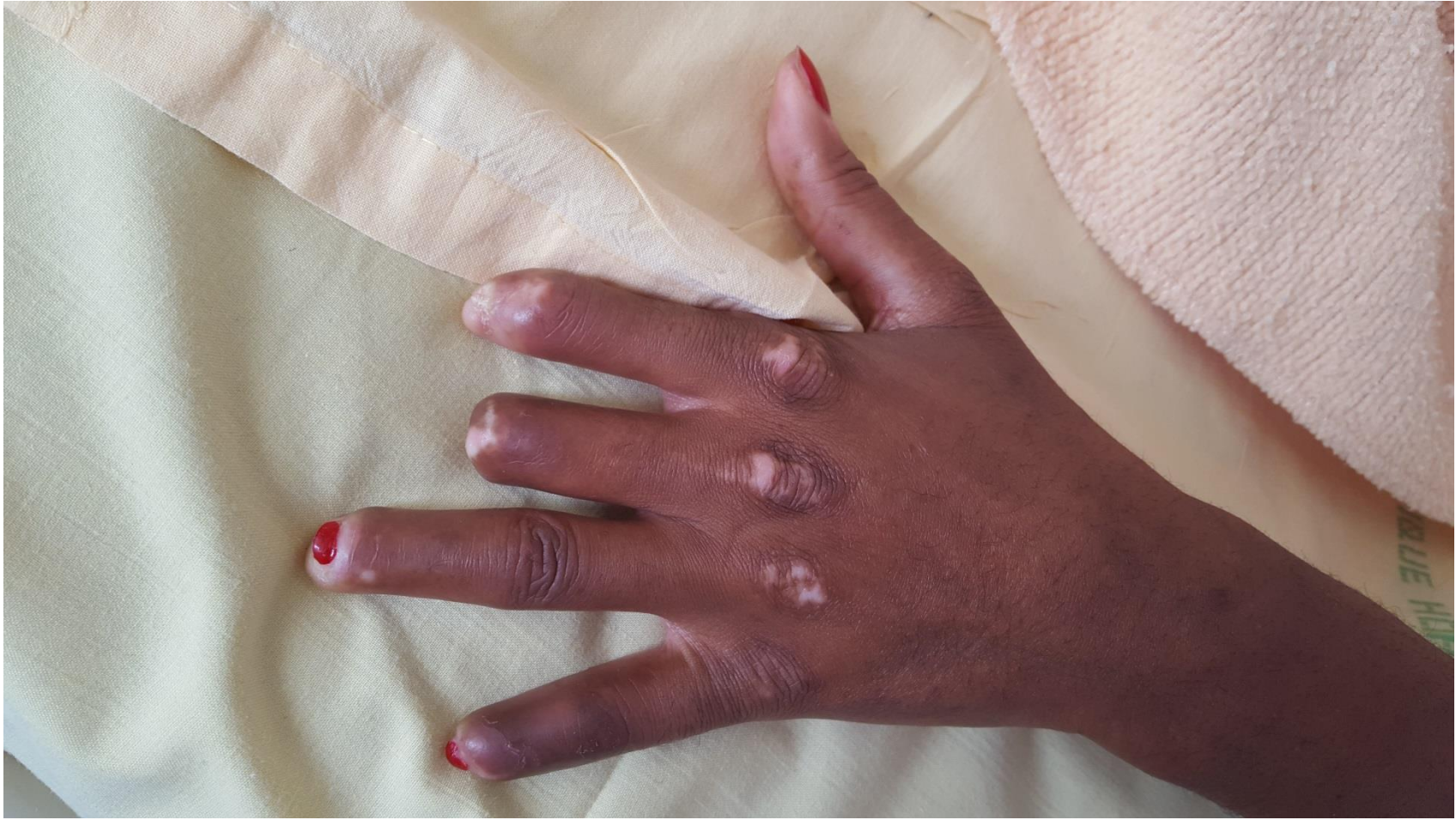Juvenile systemic sclerosis: atrophic phase

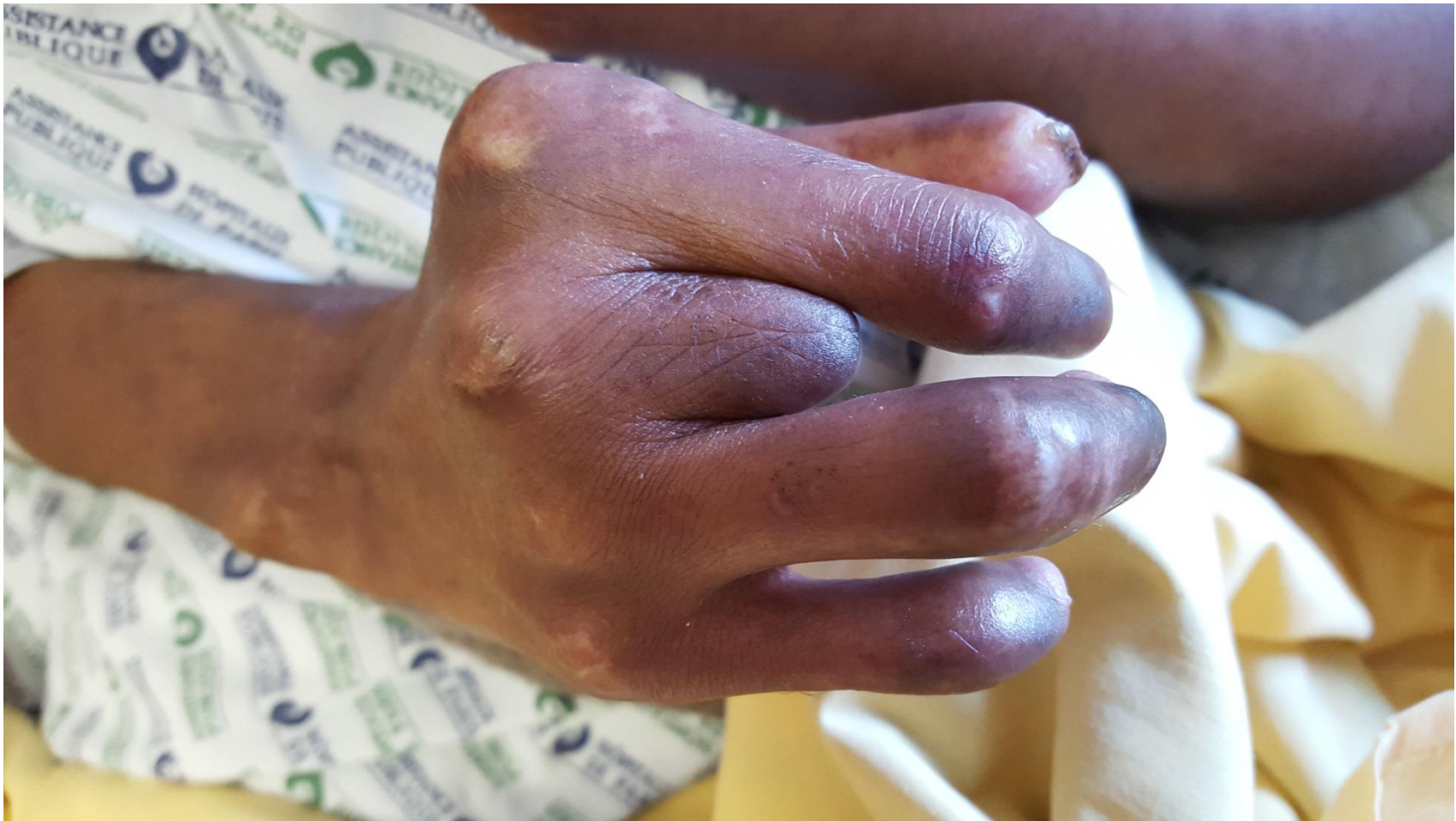

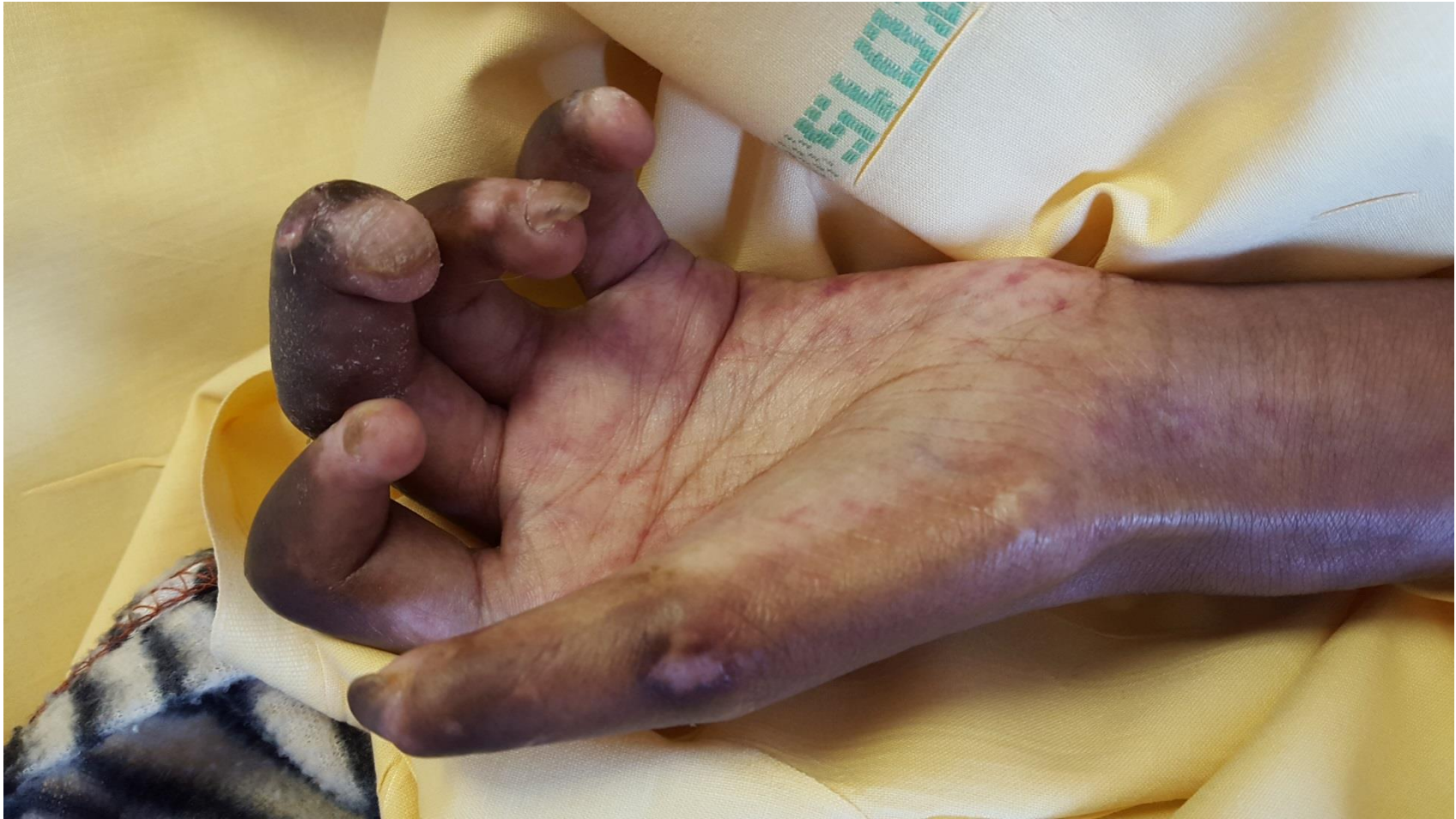Hypertrophy of the nail cuticle







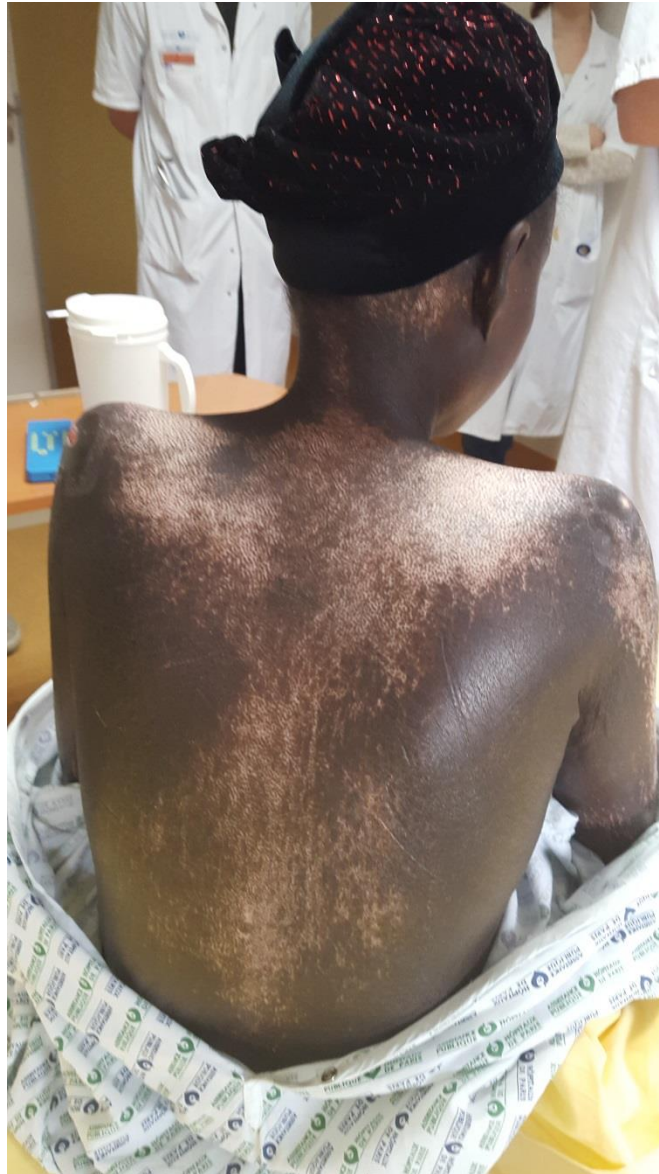



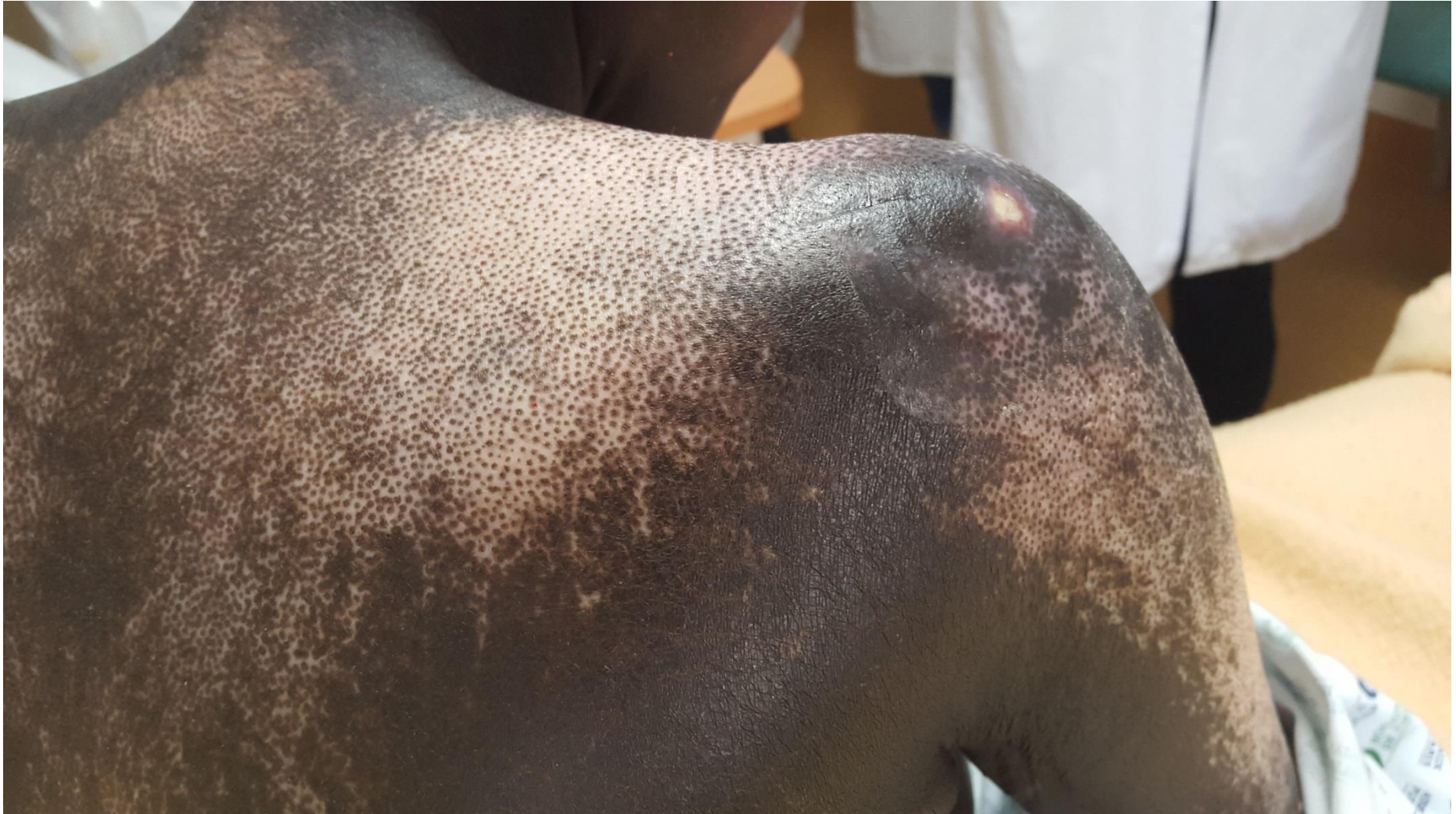Systemic sclerosis: depigmentation



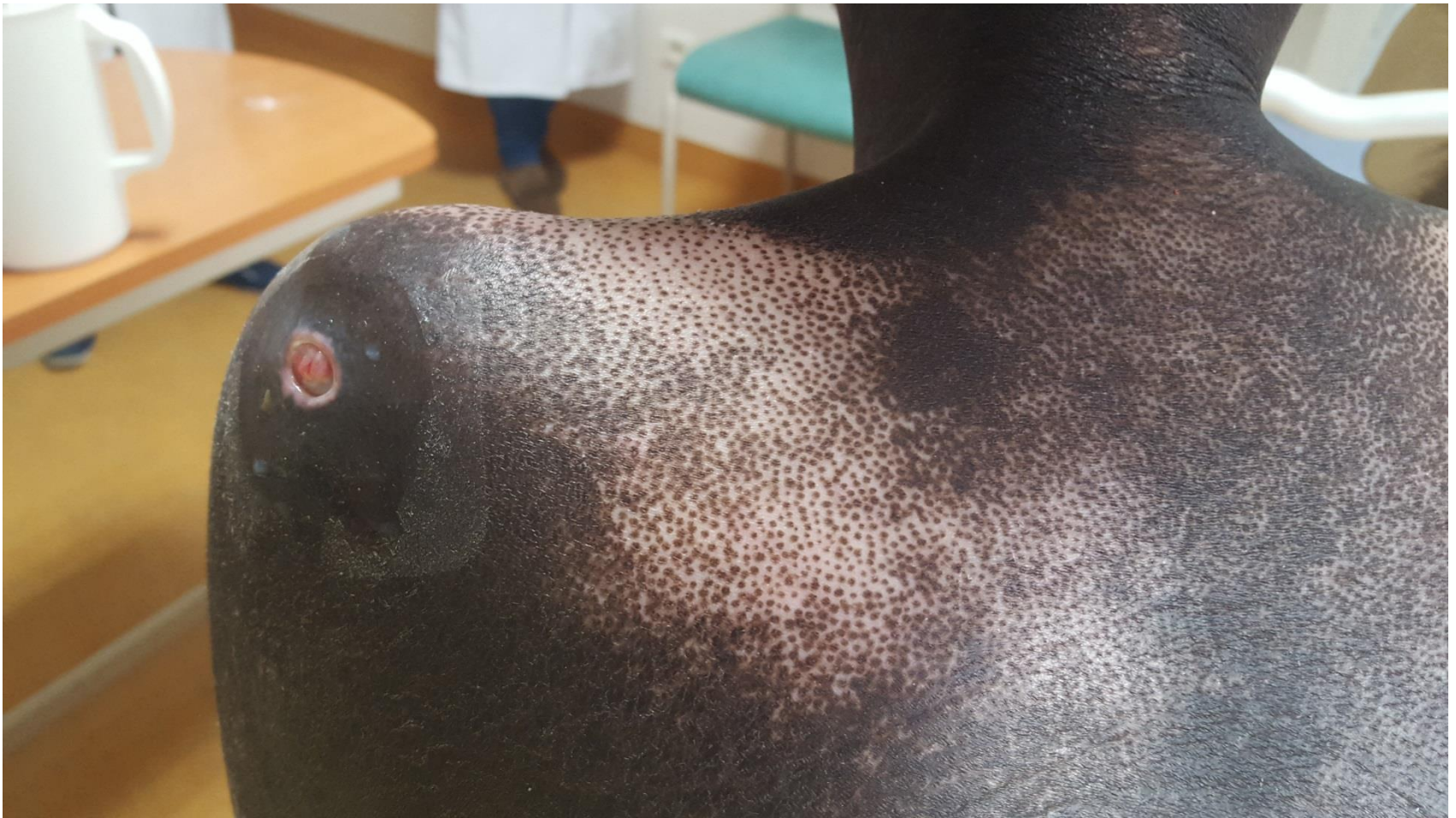Systemic sclerosis: depigmentation



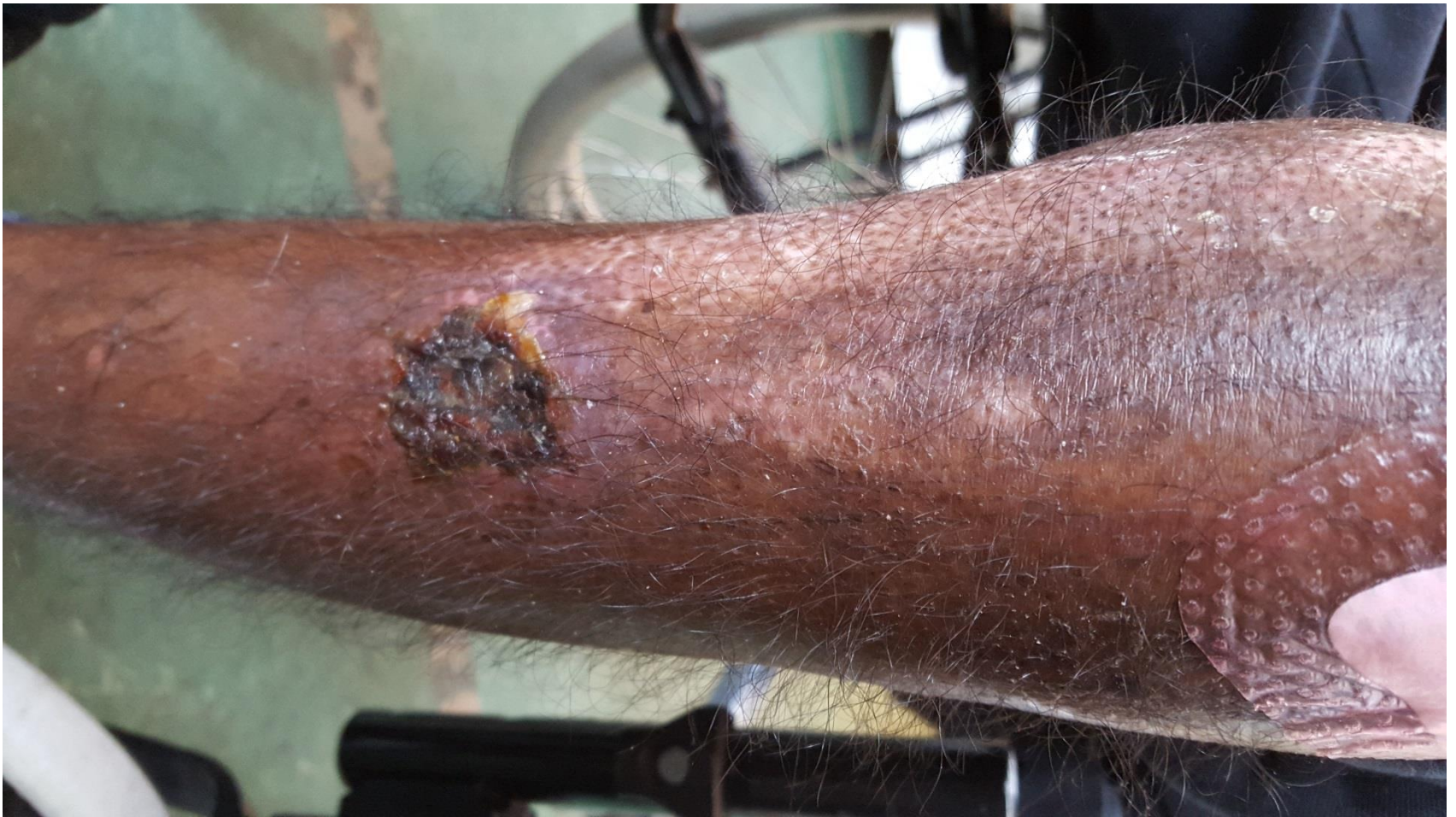Systemic sclerosis: depigmentation/ulcer

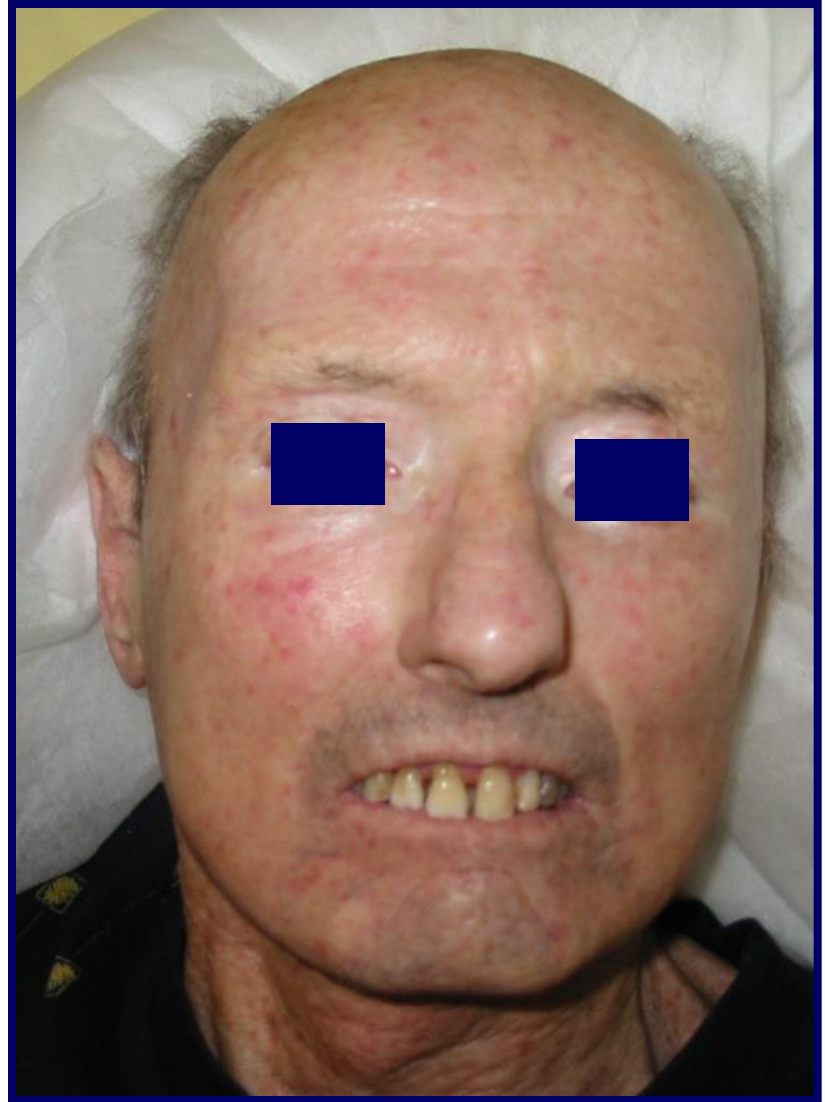
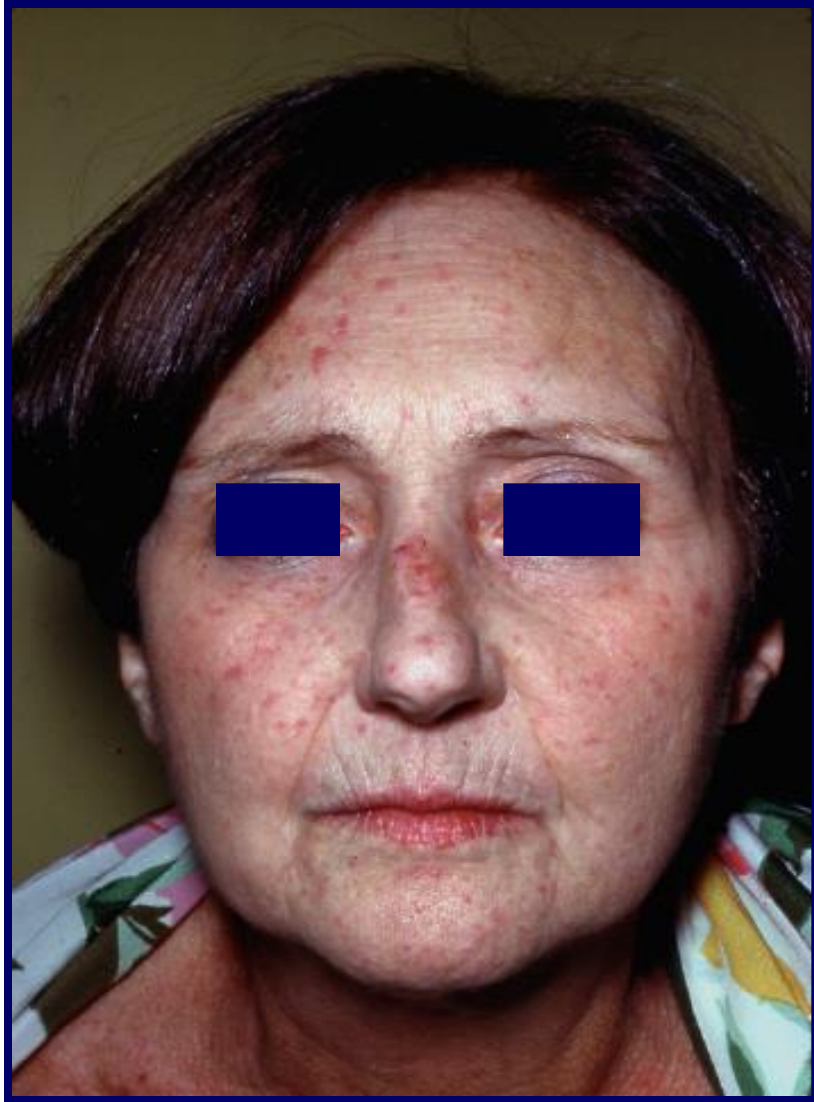
Systemic sclerosis: depigmentation/ulcer

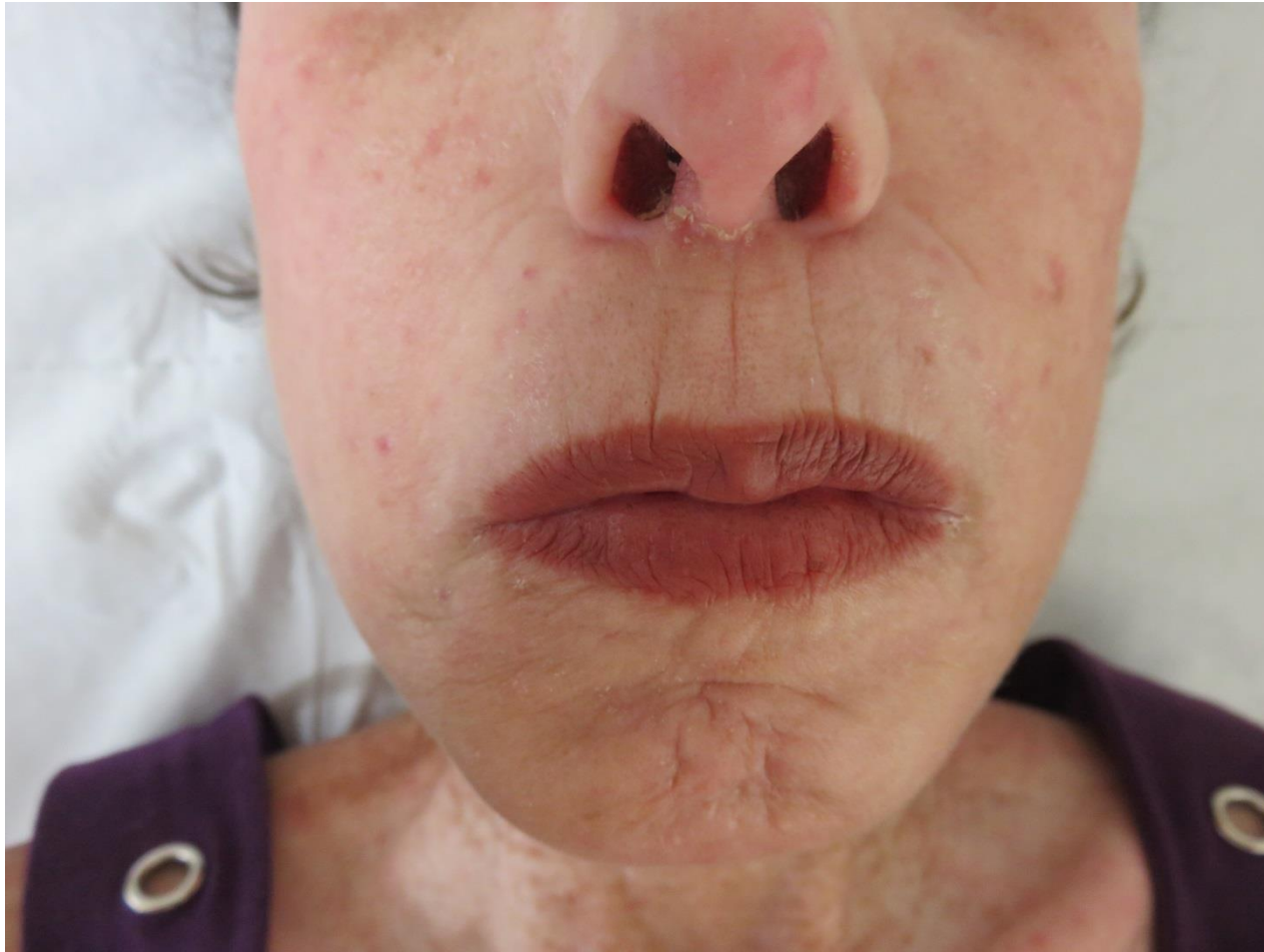

Systemic sclerosis: depigmentation/ulcer

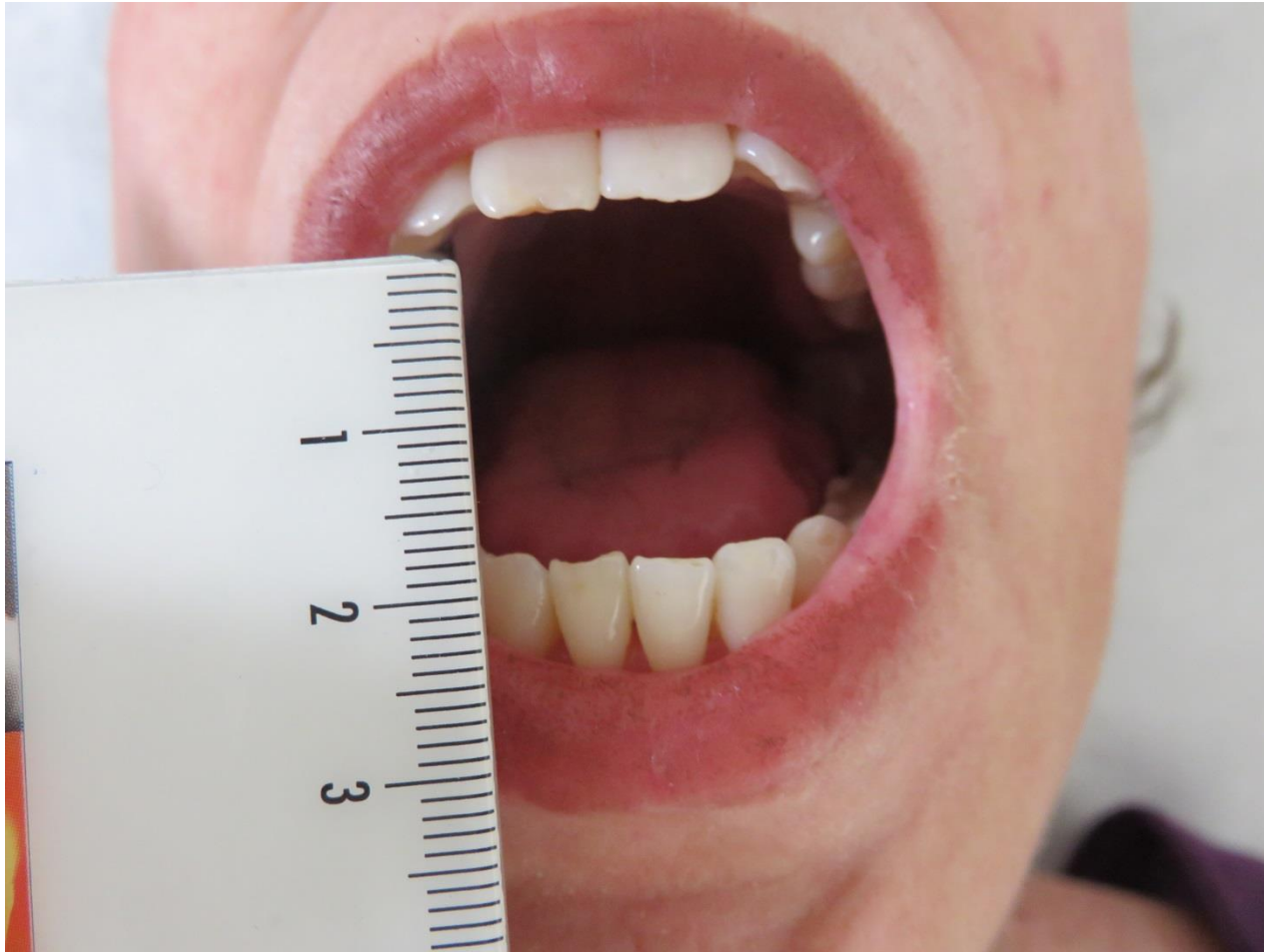



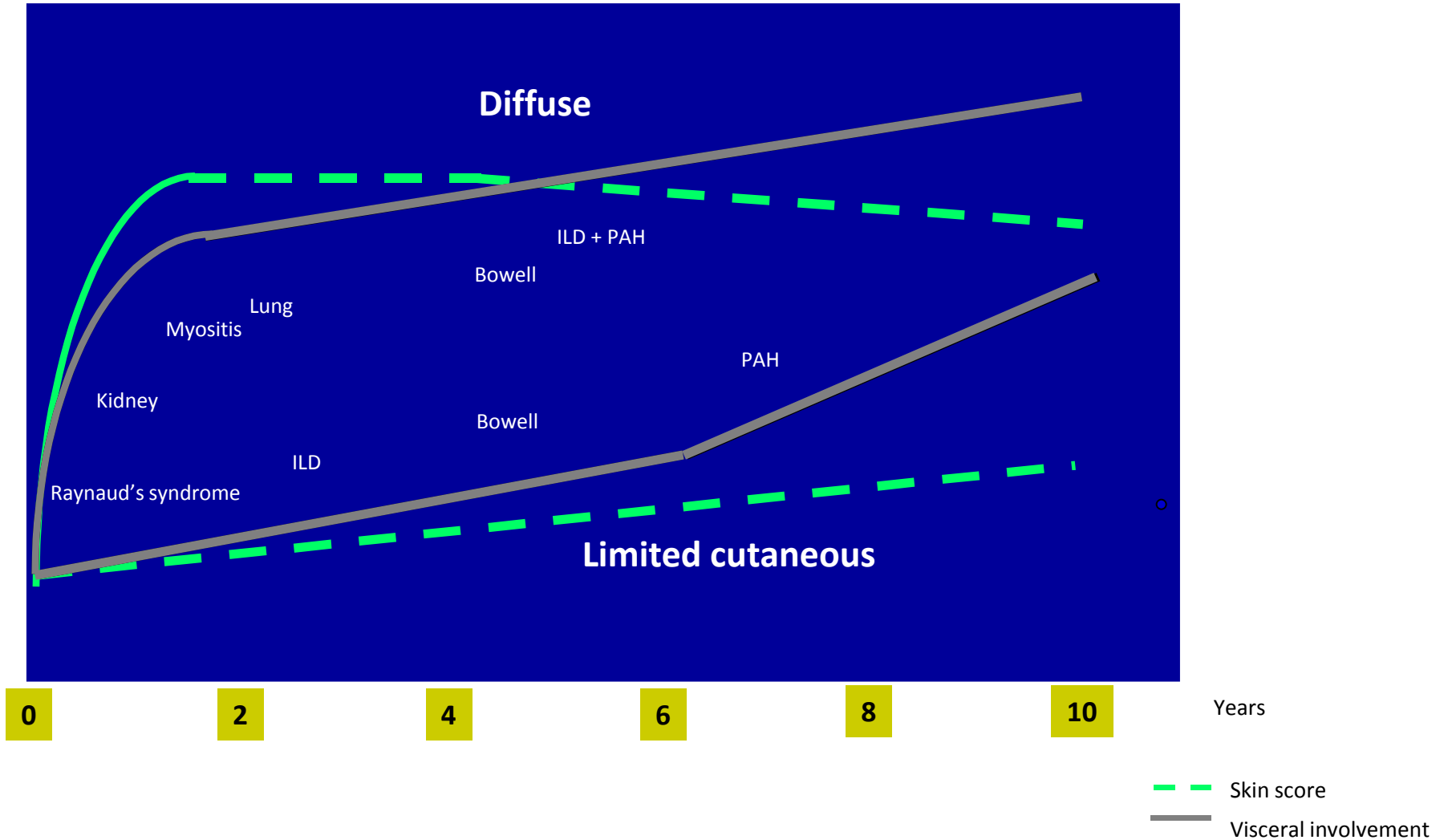
Mouth involvement



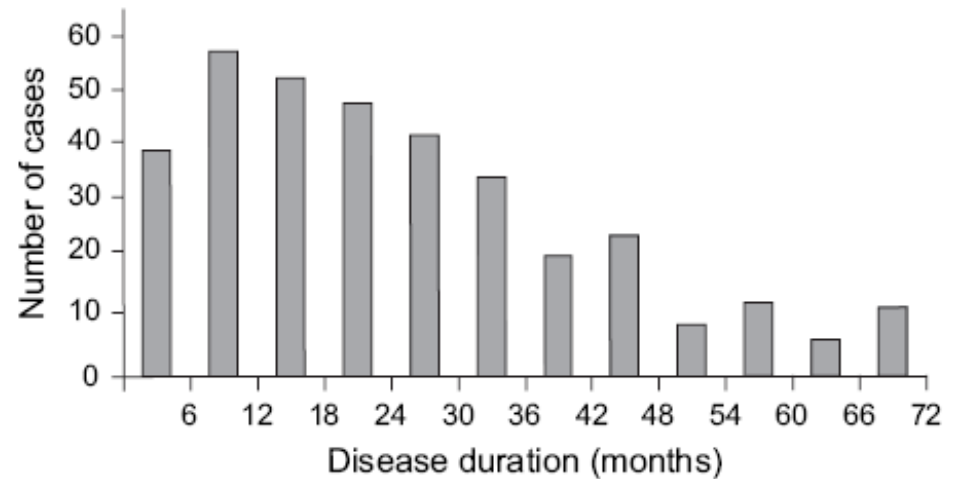
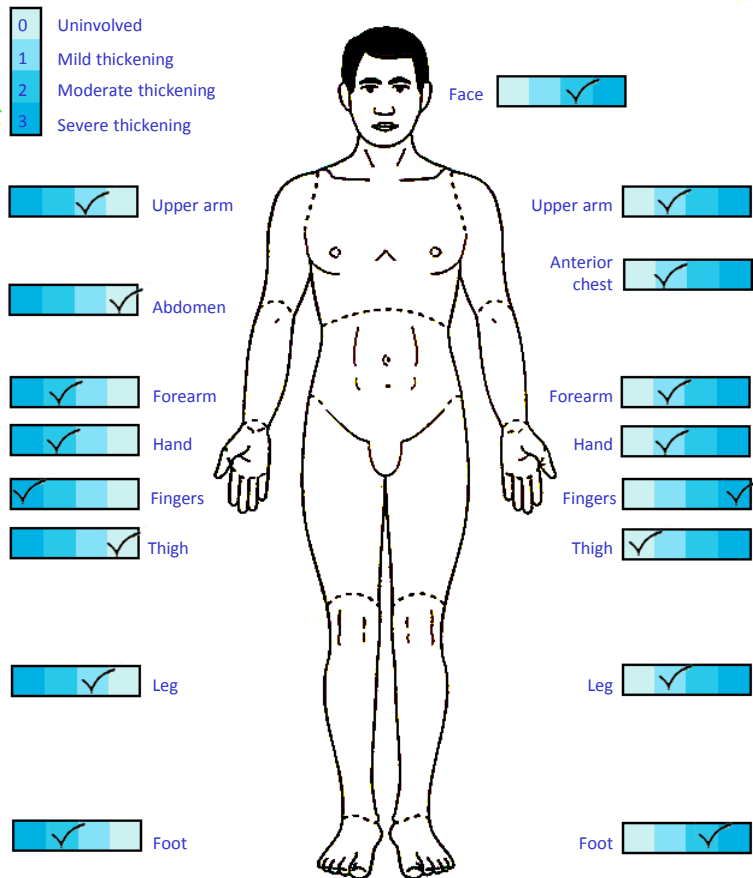
Limited mouth aperture



SYSTEMIC SCLEROSIS : EVOLUTION

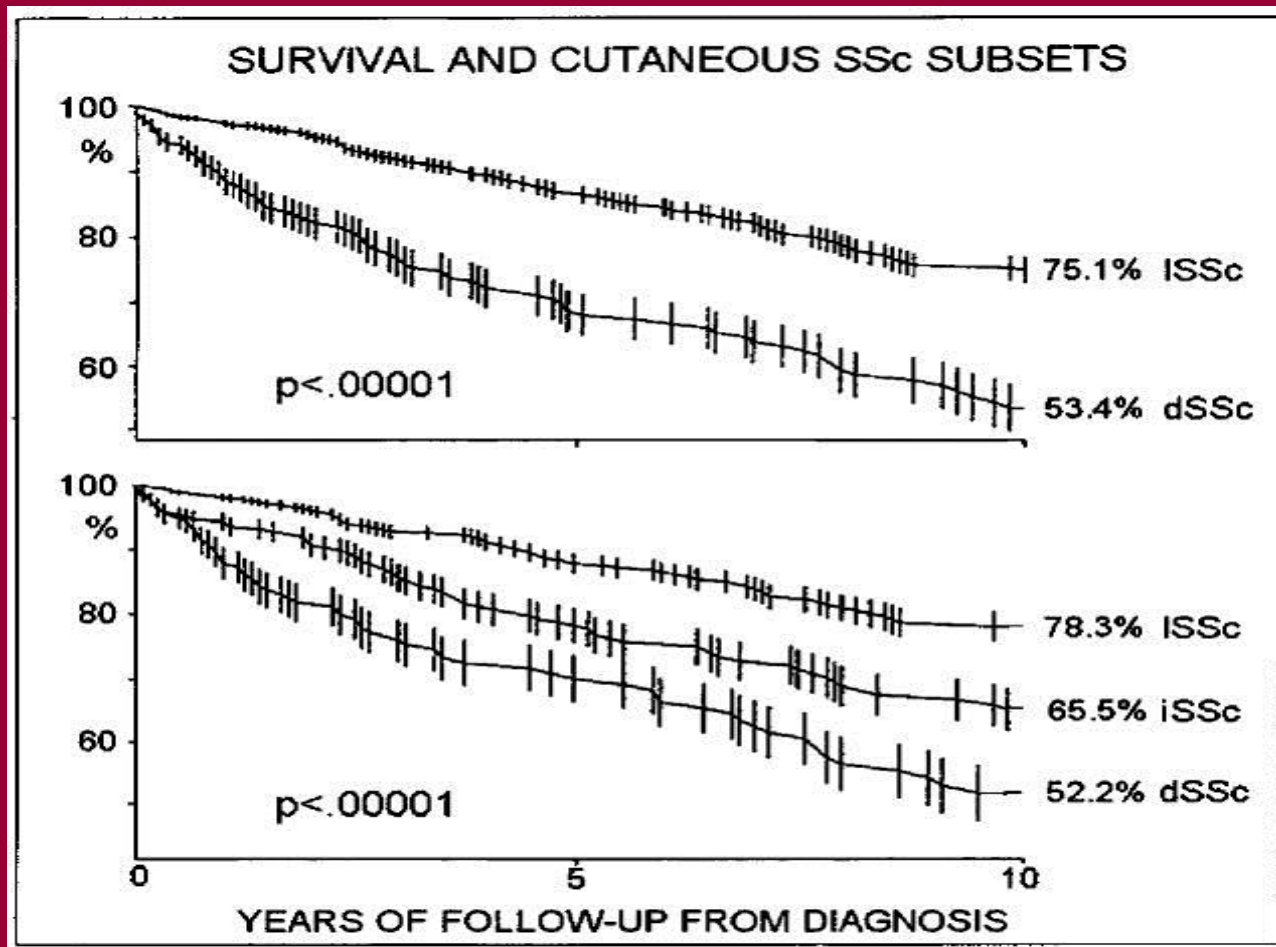


The modified Rodnan skin score (MRSS)



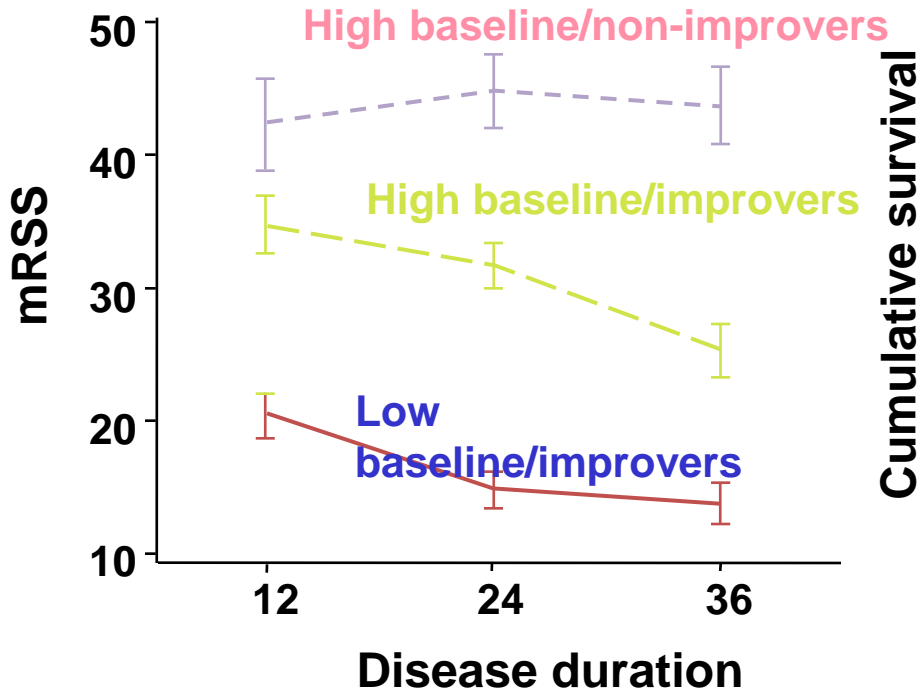
Disease duration at peak skin score of the patients who had dcSSc from the Royal Free Hospital scleroderma database.

Pronostic: l'atteinte cutanée proximale et la rapidité d'installation sont les éléments pronostiques importants

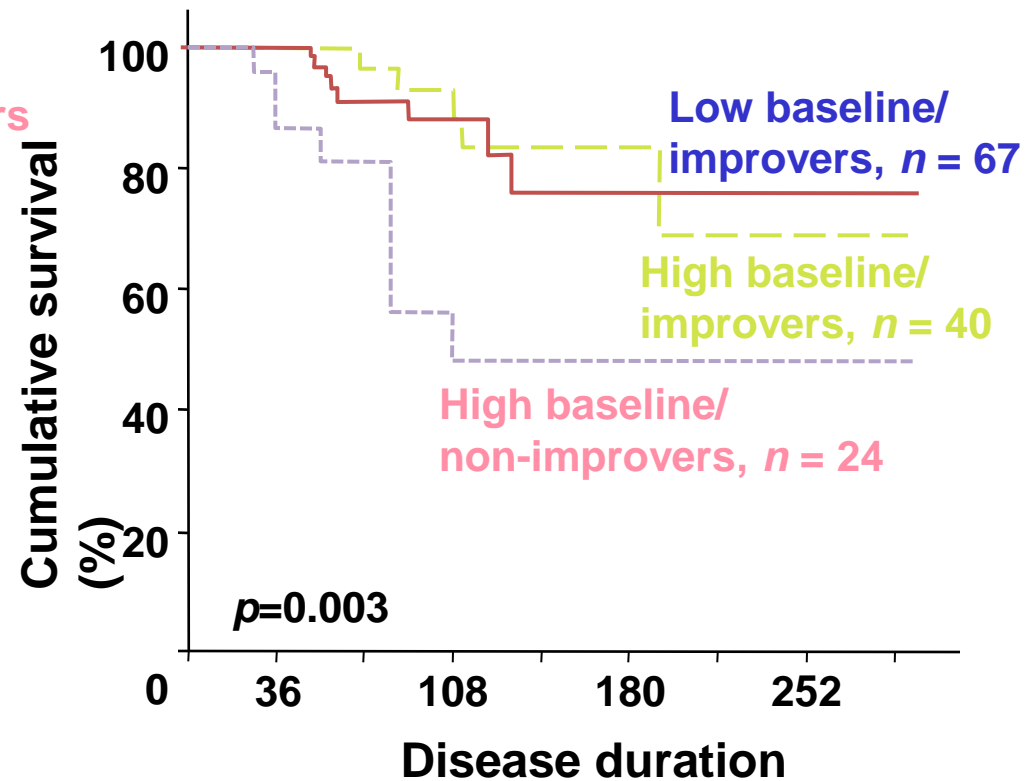


Disease duration and skin score in dcSSc

Change in skin score over 3 years in the subgroups



Survival in the subgroups



Identify early diffuse SSC

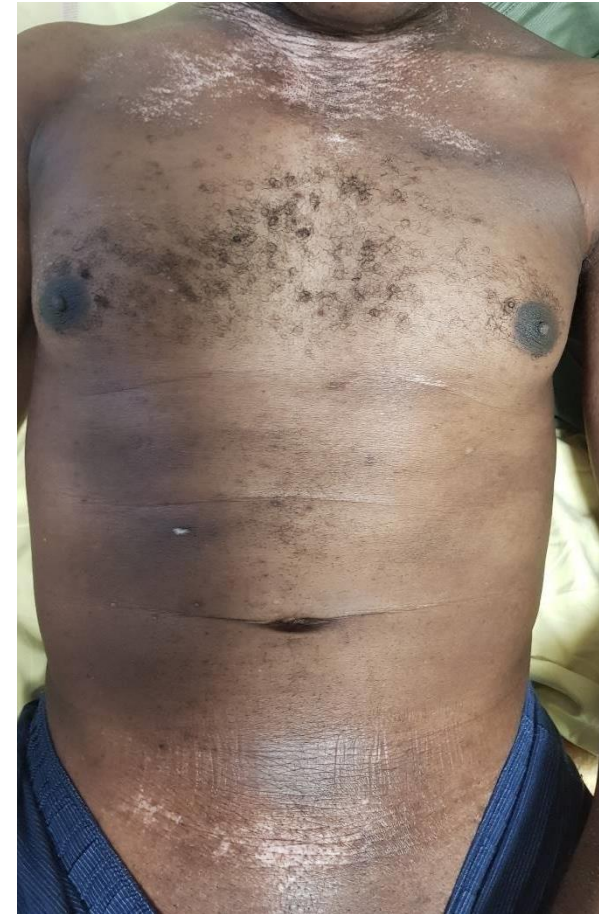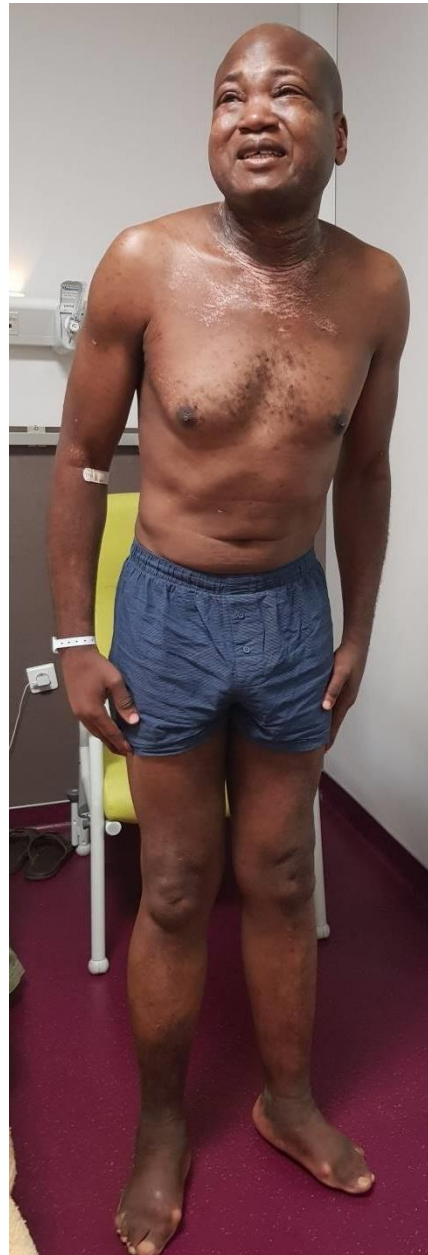Oedema (weight gain)
Swelling hands
Joint/muscle pain

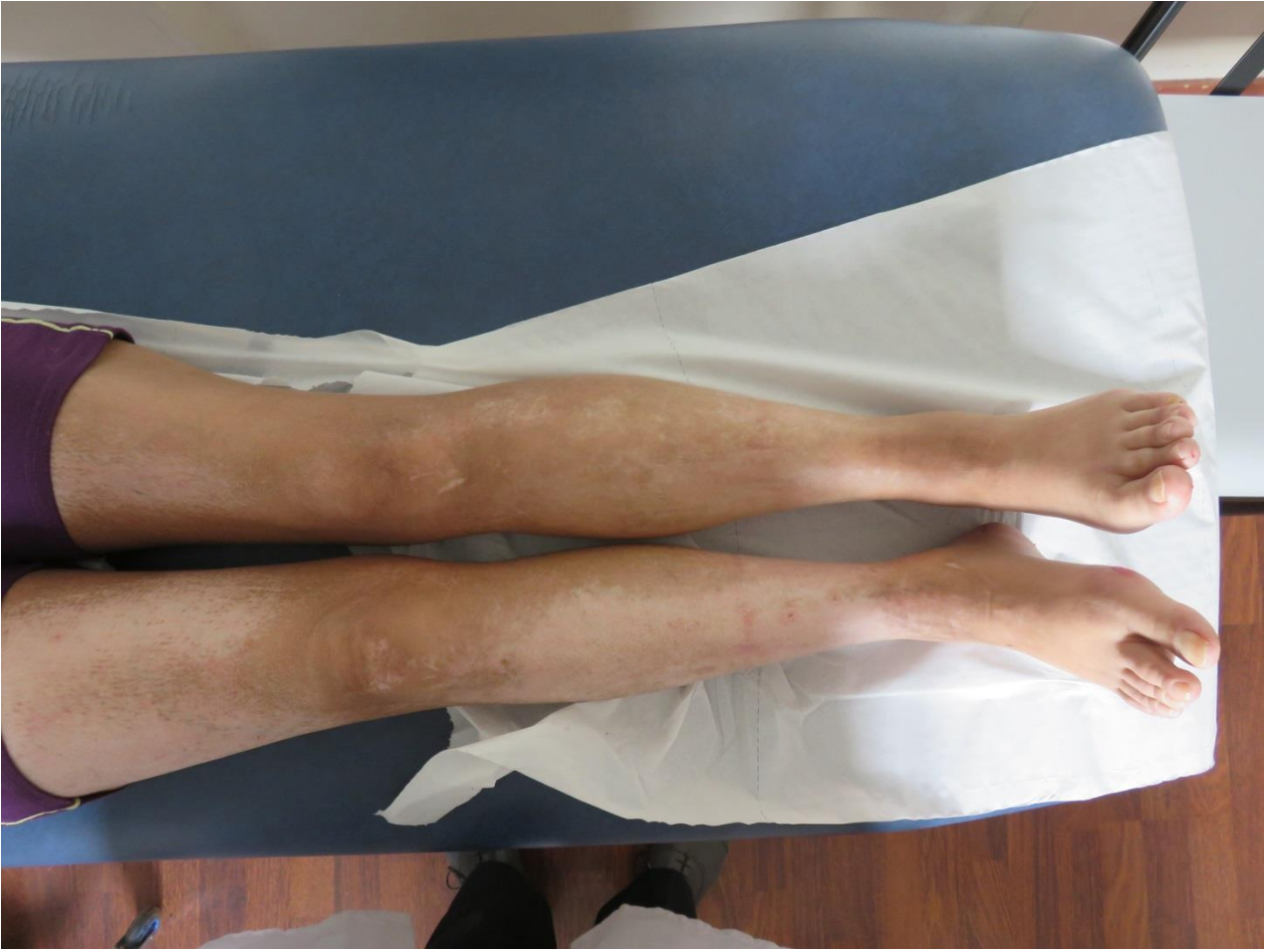Later on.....
Raynaud's phenomenon

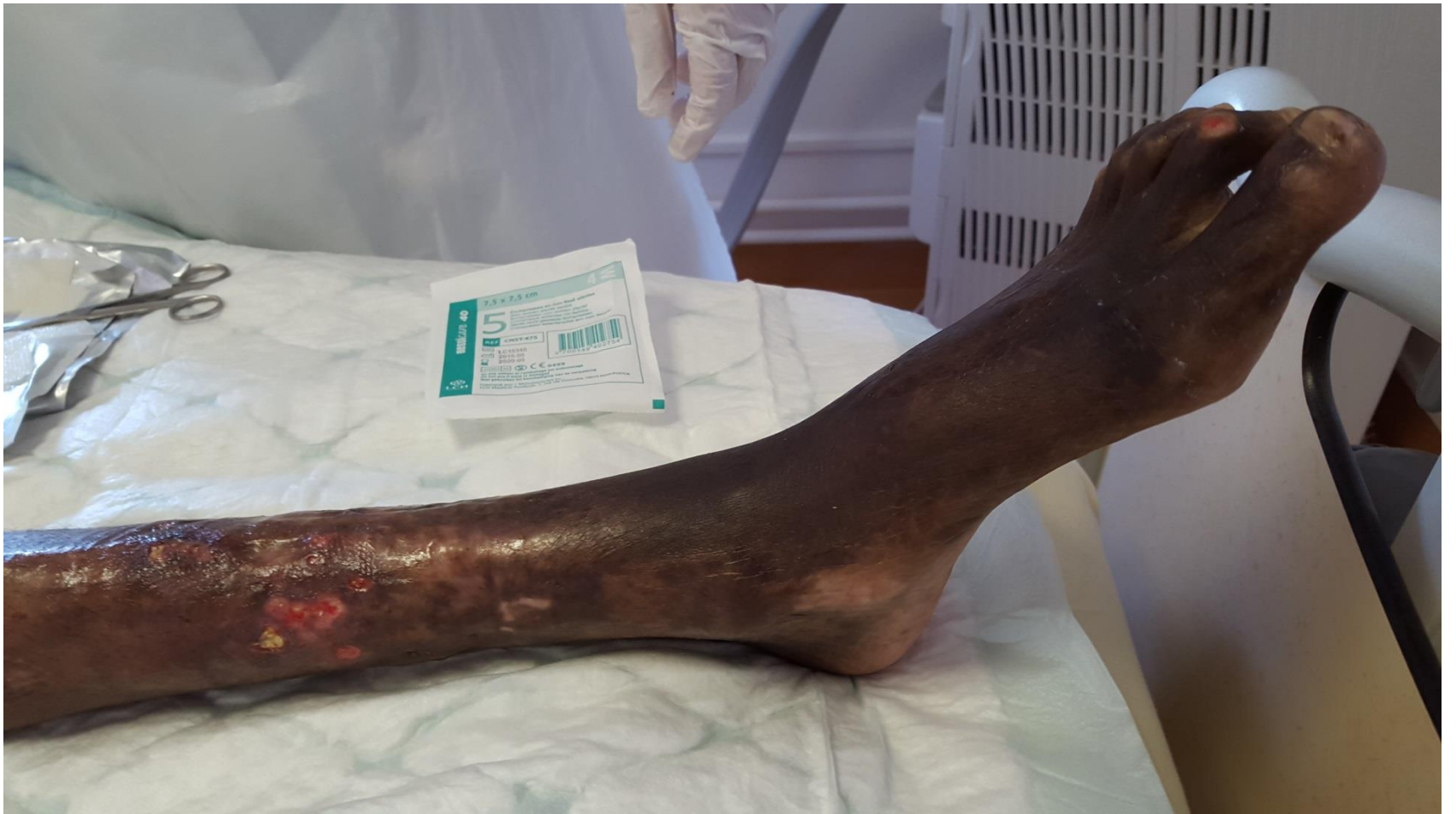Later on...
Sclerodactyly

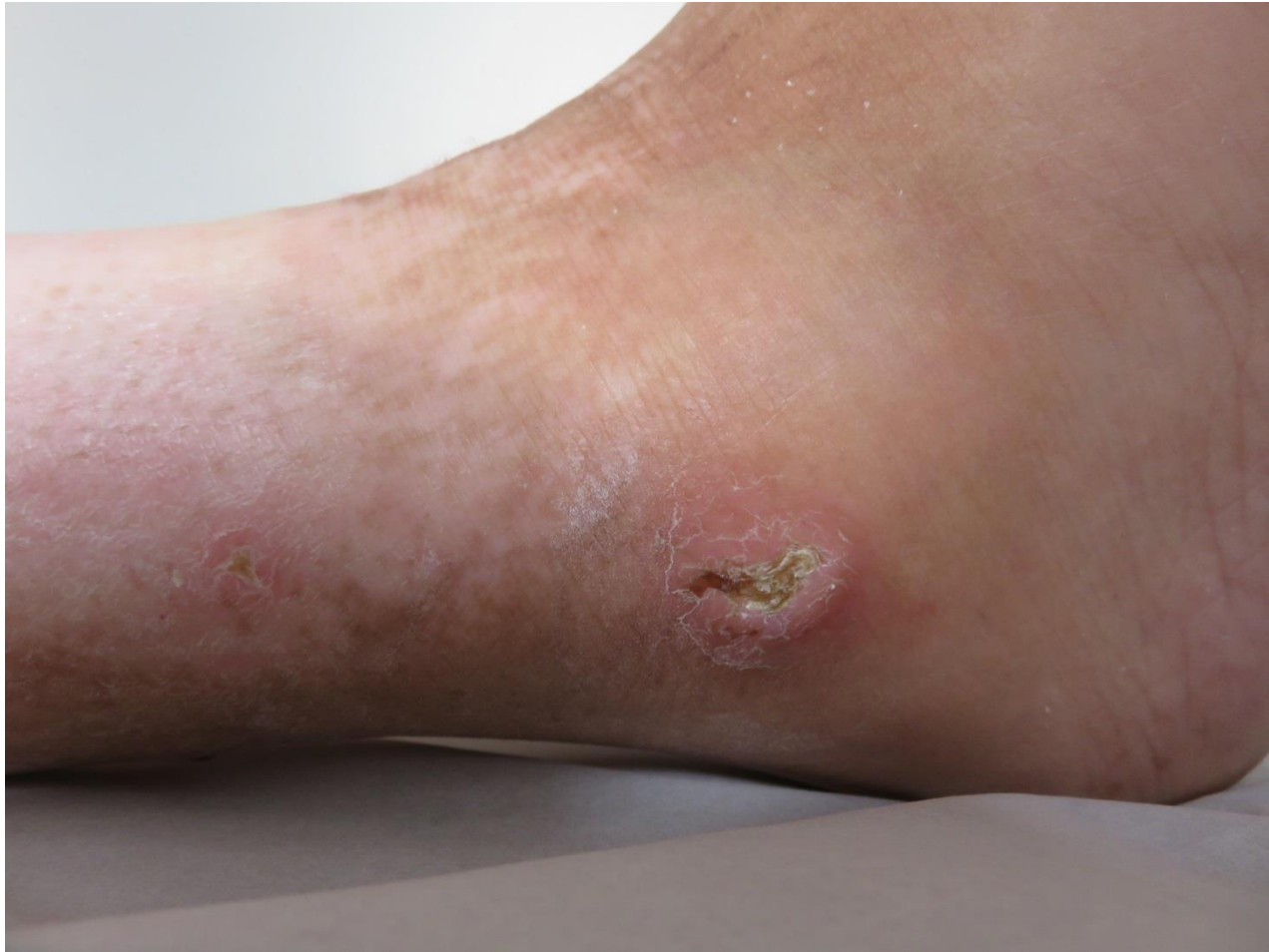Sometimes:
Myositis
Renal crisis
Before skin sclerosis

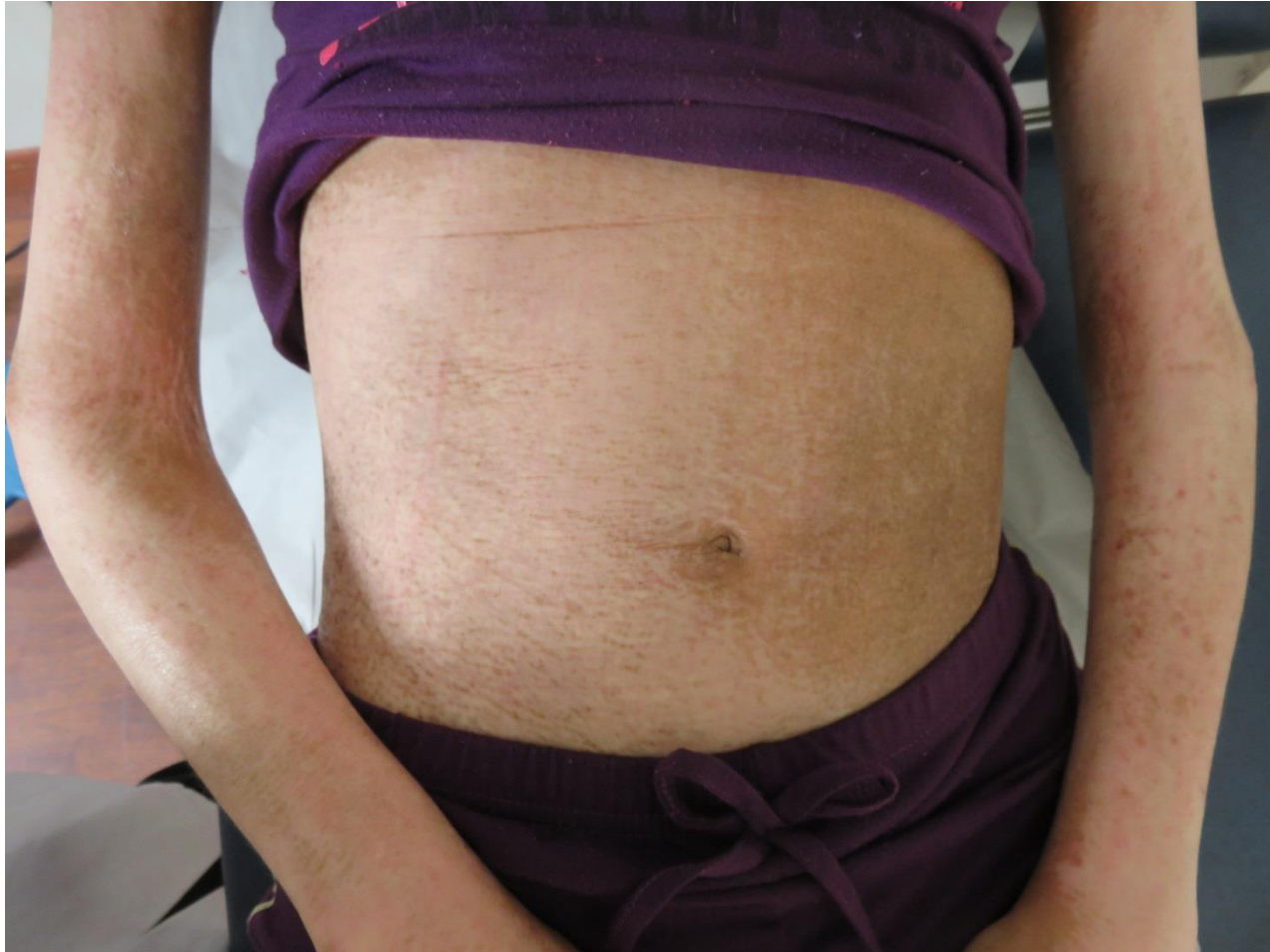
Always touch the skin !

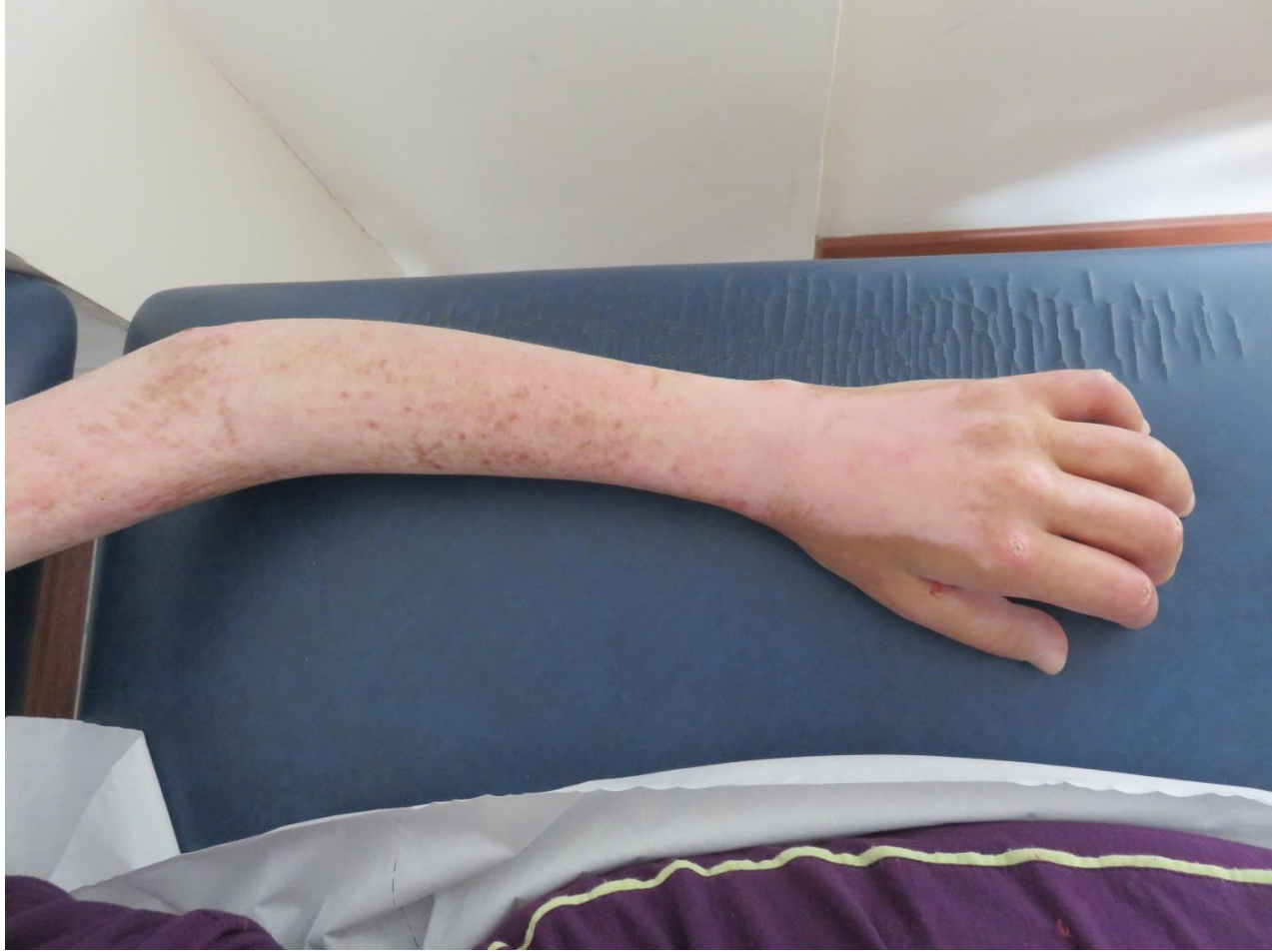






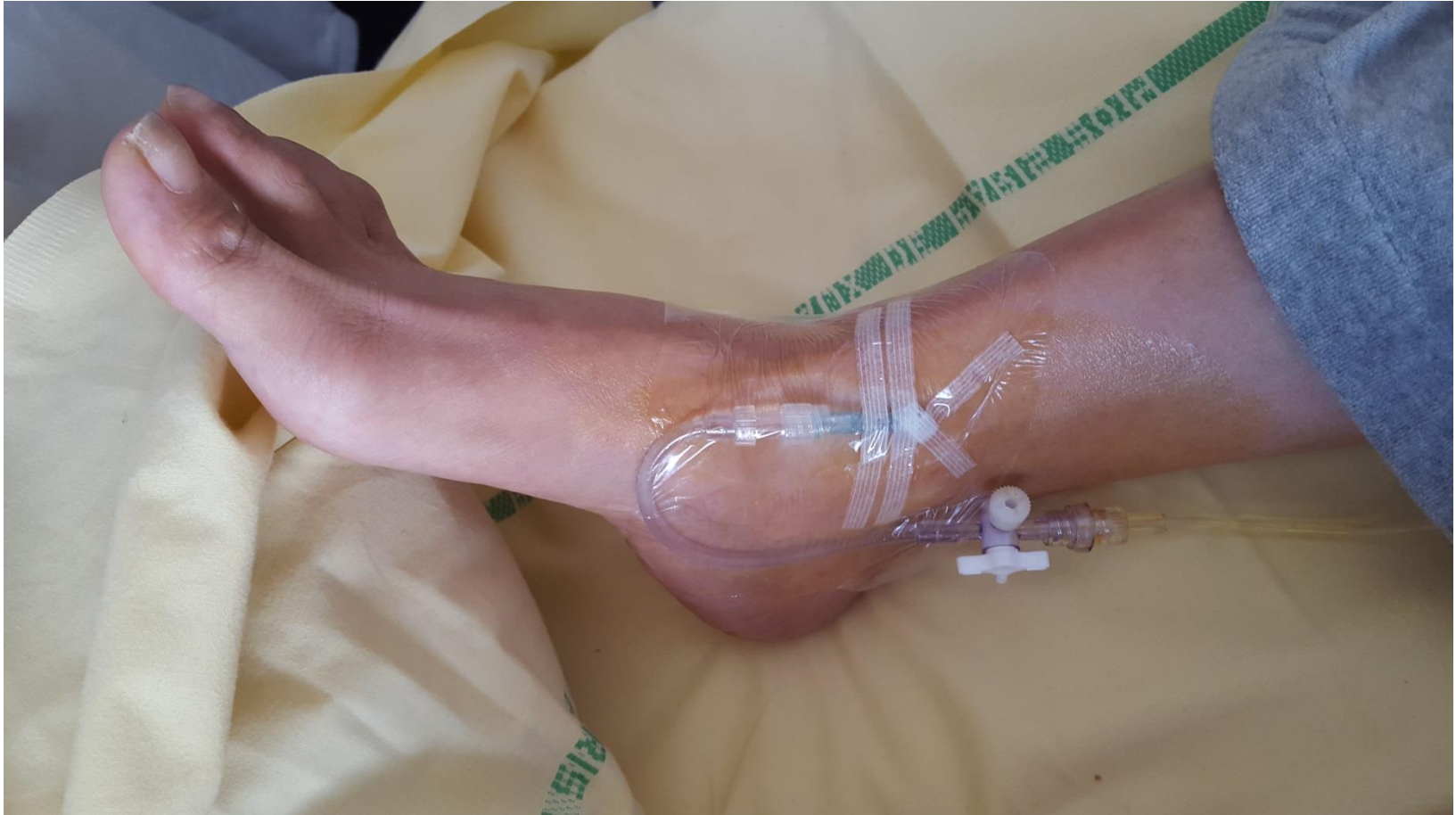


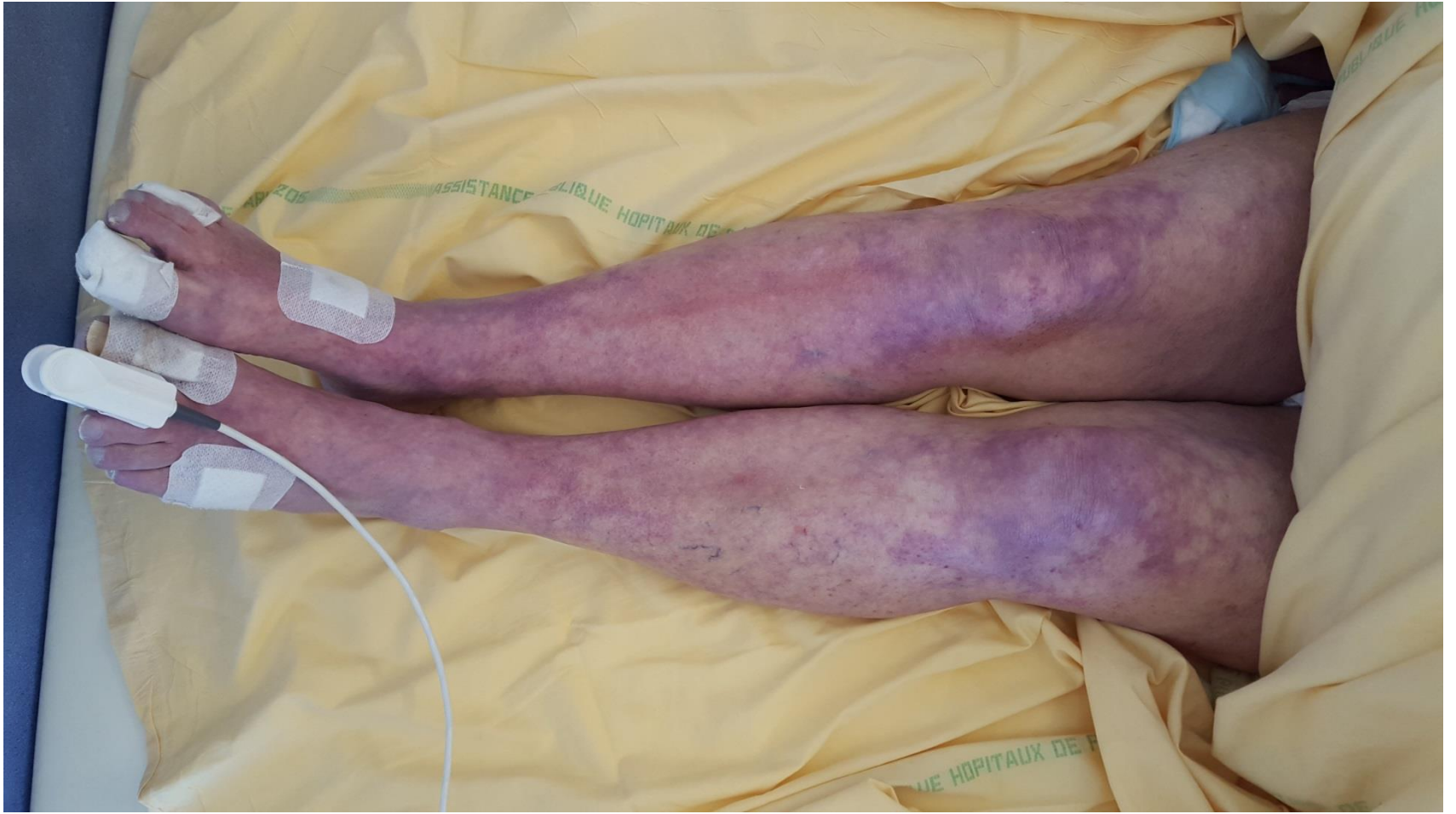

Perfusion difficile

- Trouver une voie veineuse périphérique n'est pas une mince affaire chez certains patients
- Il faut quelquefois envisager la pose d'une chambre implantable





Conclusions

- Atteinte cutanée: élément diagnostique majeur: contribution aux critères de classification (télangiectasies)
- Différentiel limité/diffus
- Score de Rodnan modifié: intérêt pronostique
- Evolution de la sclérose vers l'atrophie
- La clinique+++



Hôpital Cochin Paris



www.vascularites.org

Luc.mouthon@aphp.fr

Referral Center for
Rare Systemic and
Autoimmune Diseases

