Atteintes des couches externes

1er cas

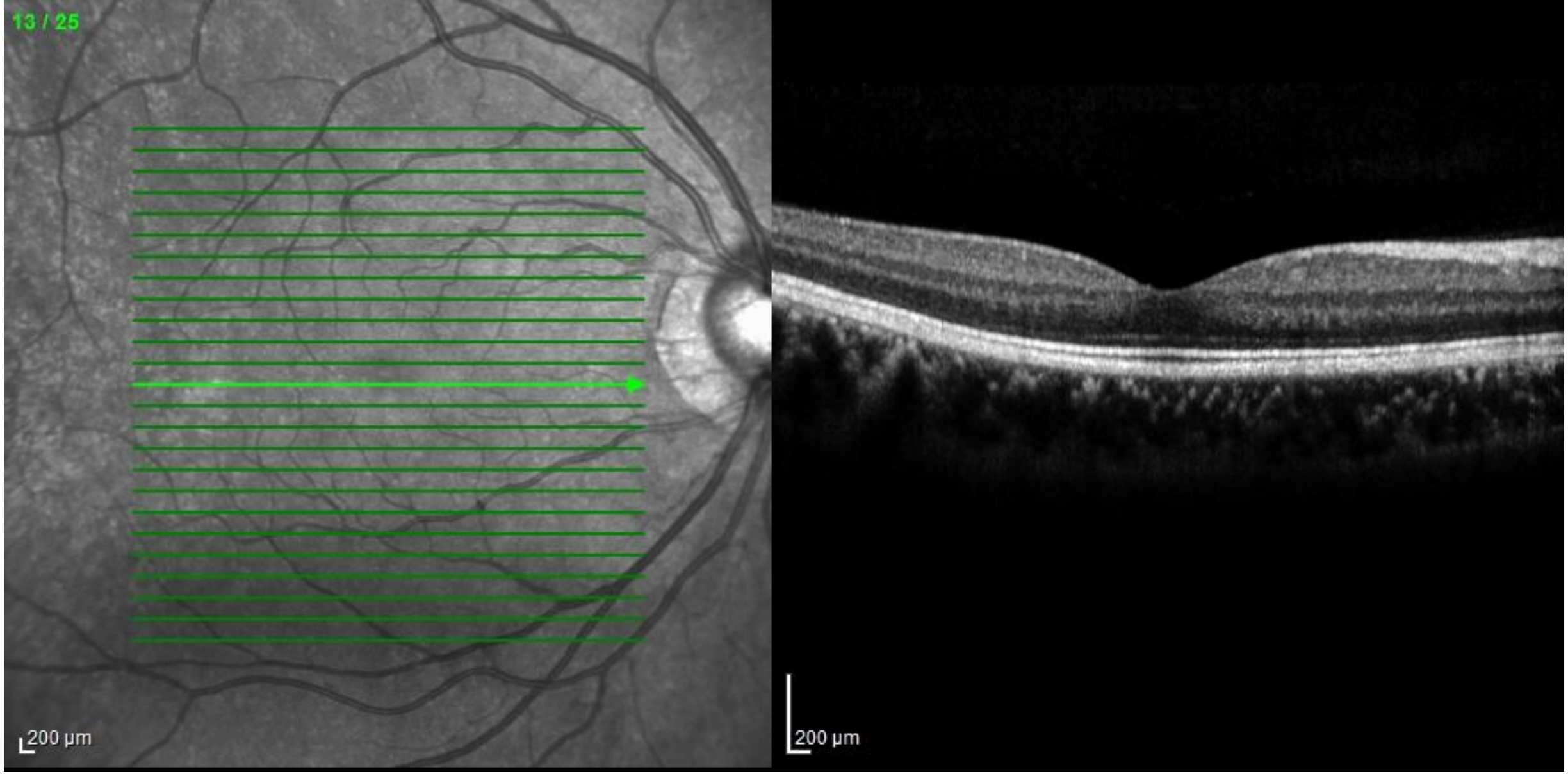
13 / 25
200 µm
200 µm

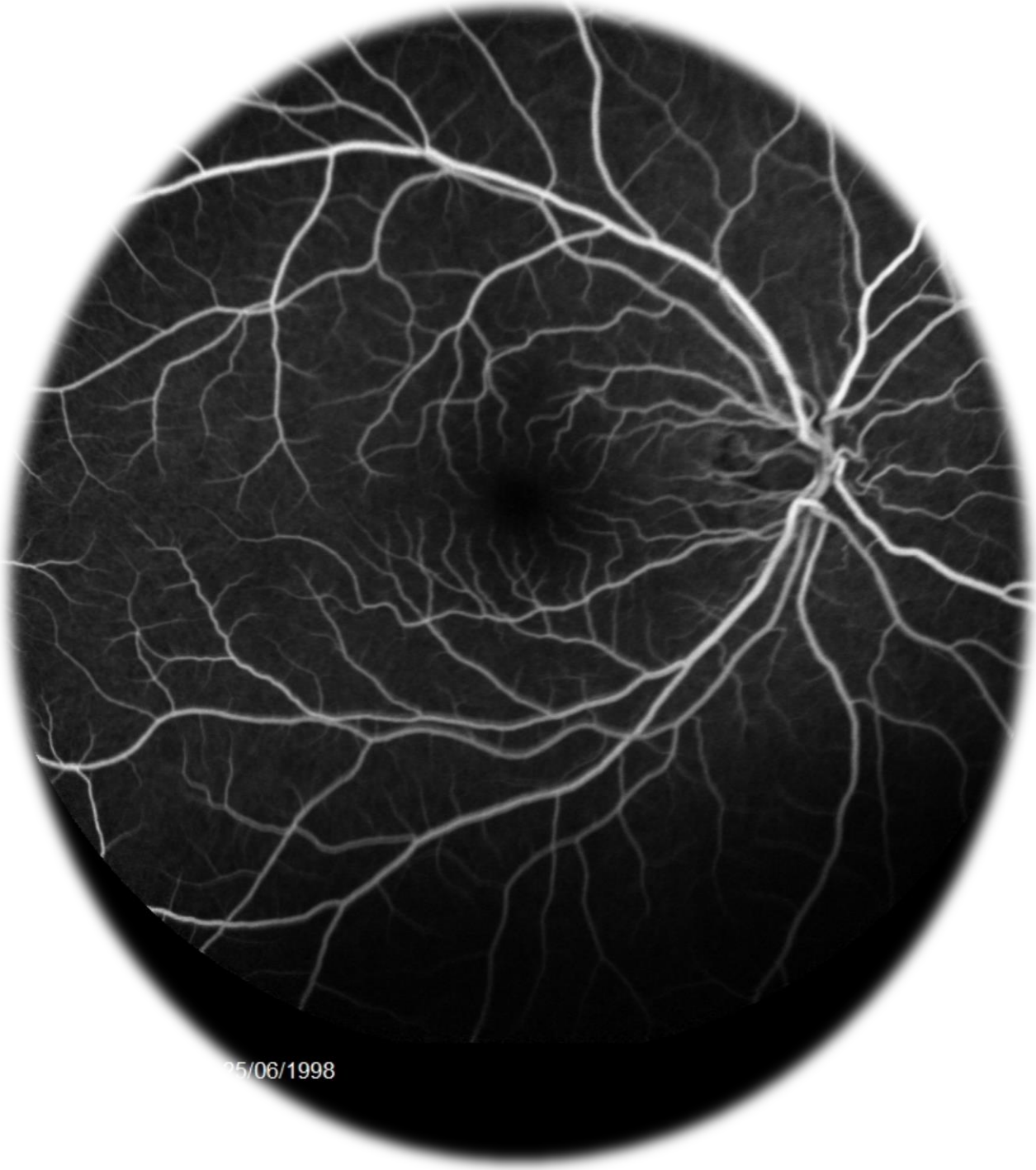
25/06/1998

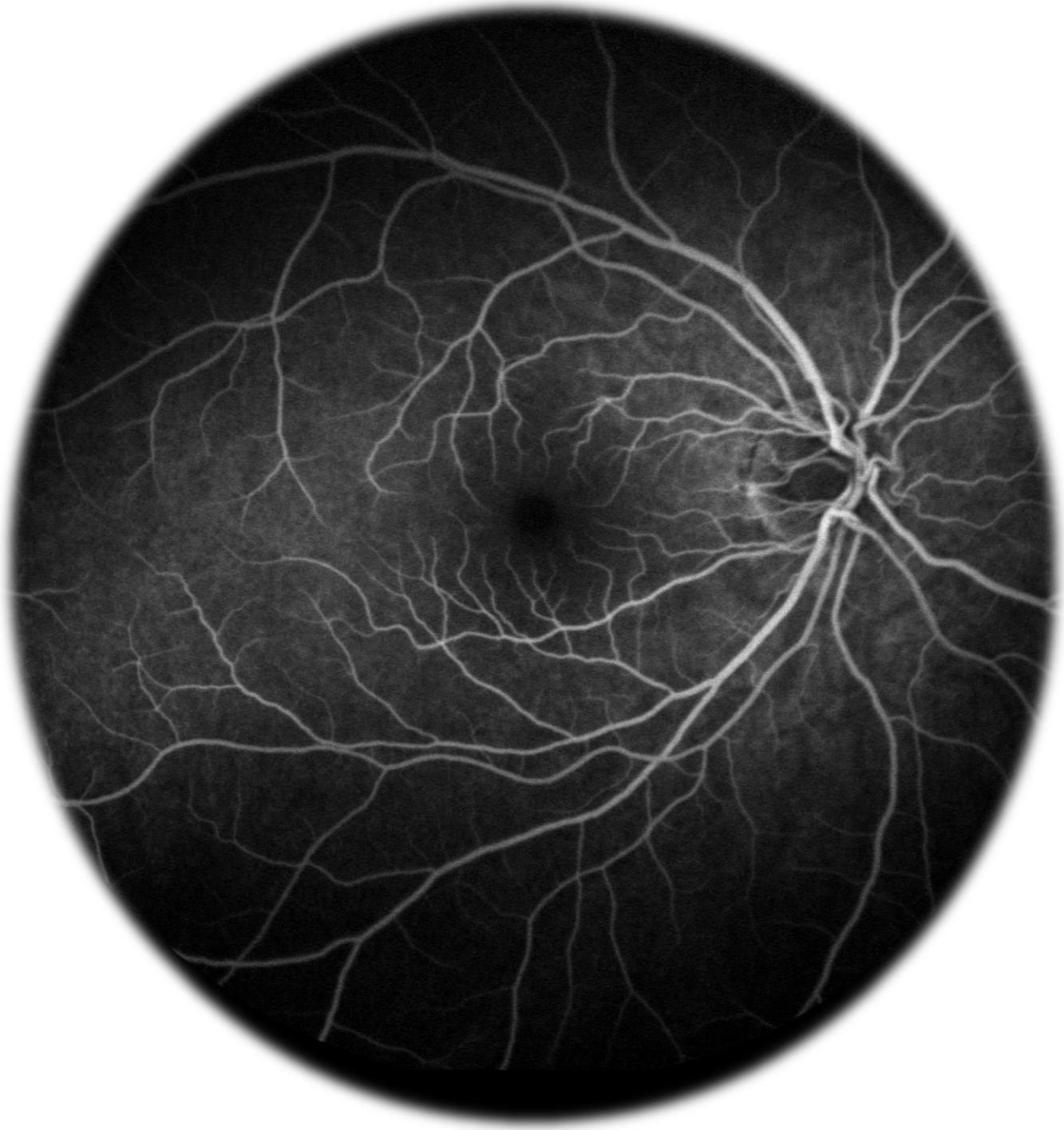

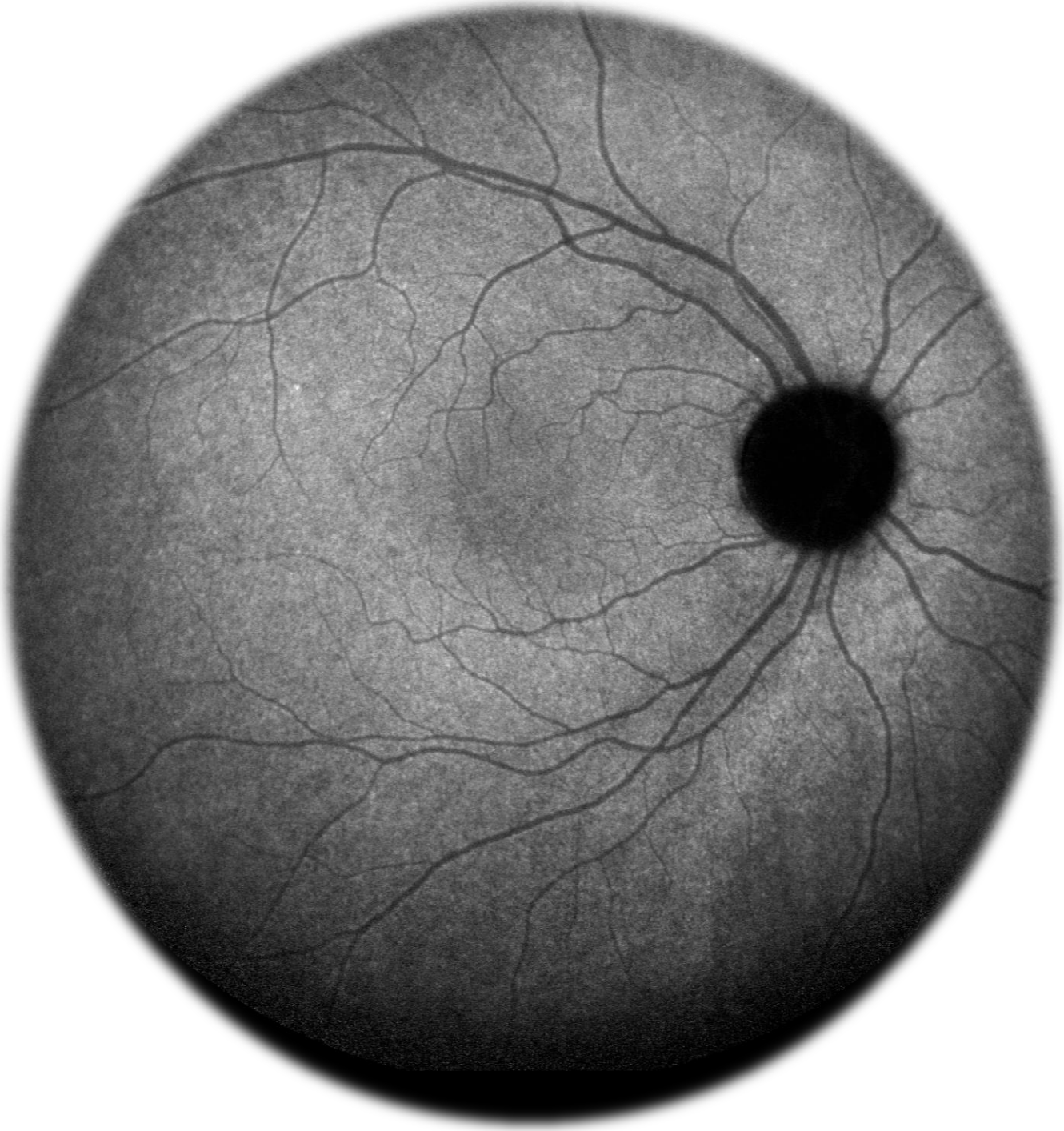

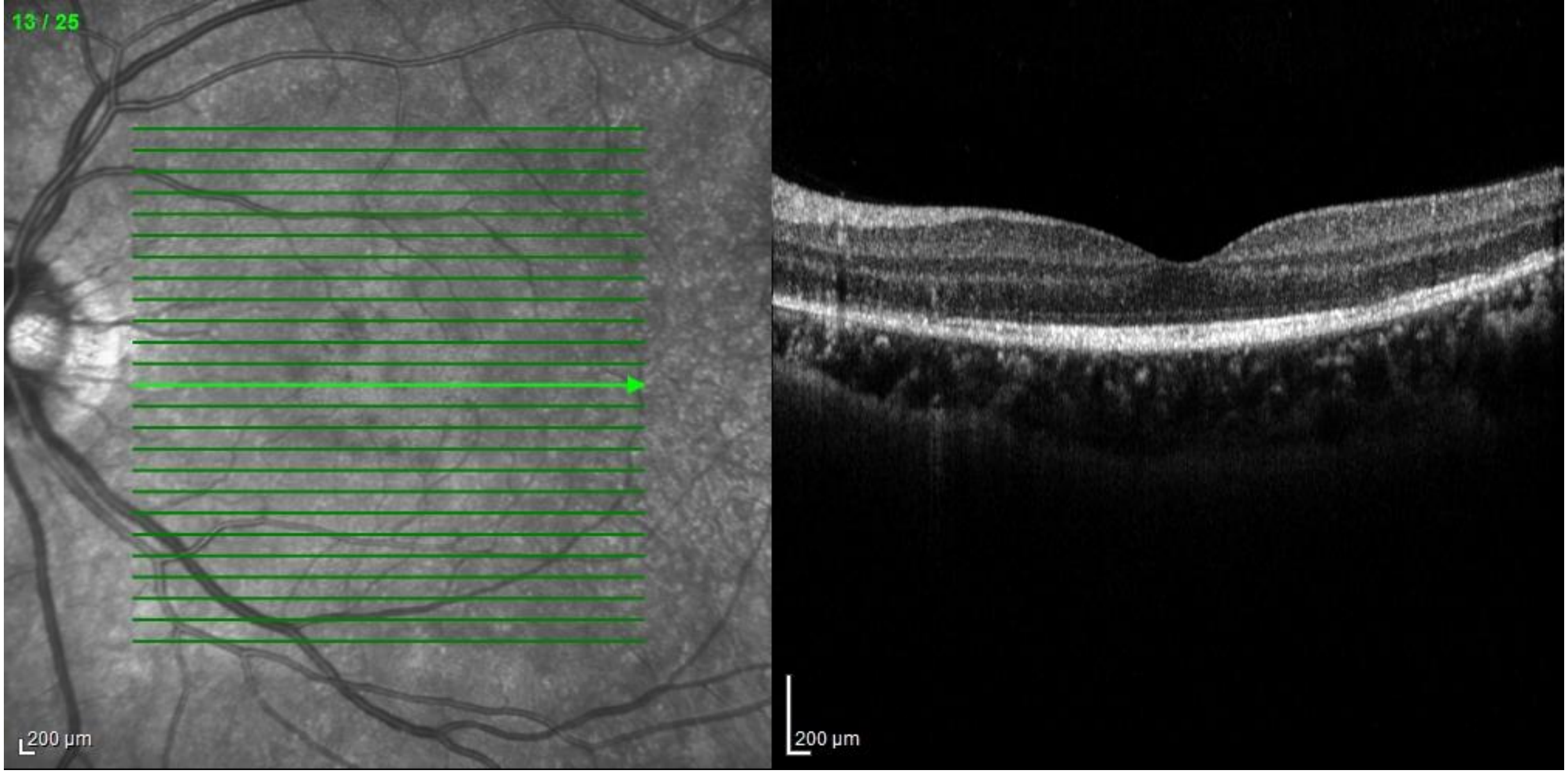
13 / 25
200 µm
200 µm

25/06/1998

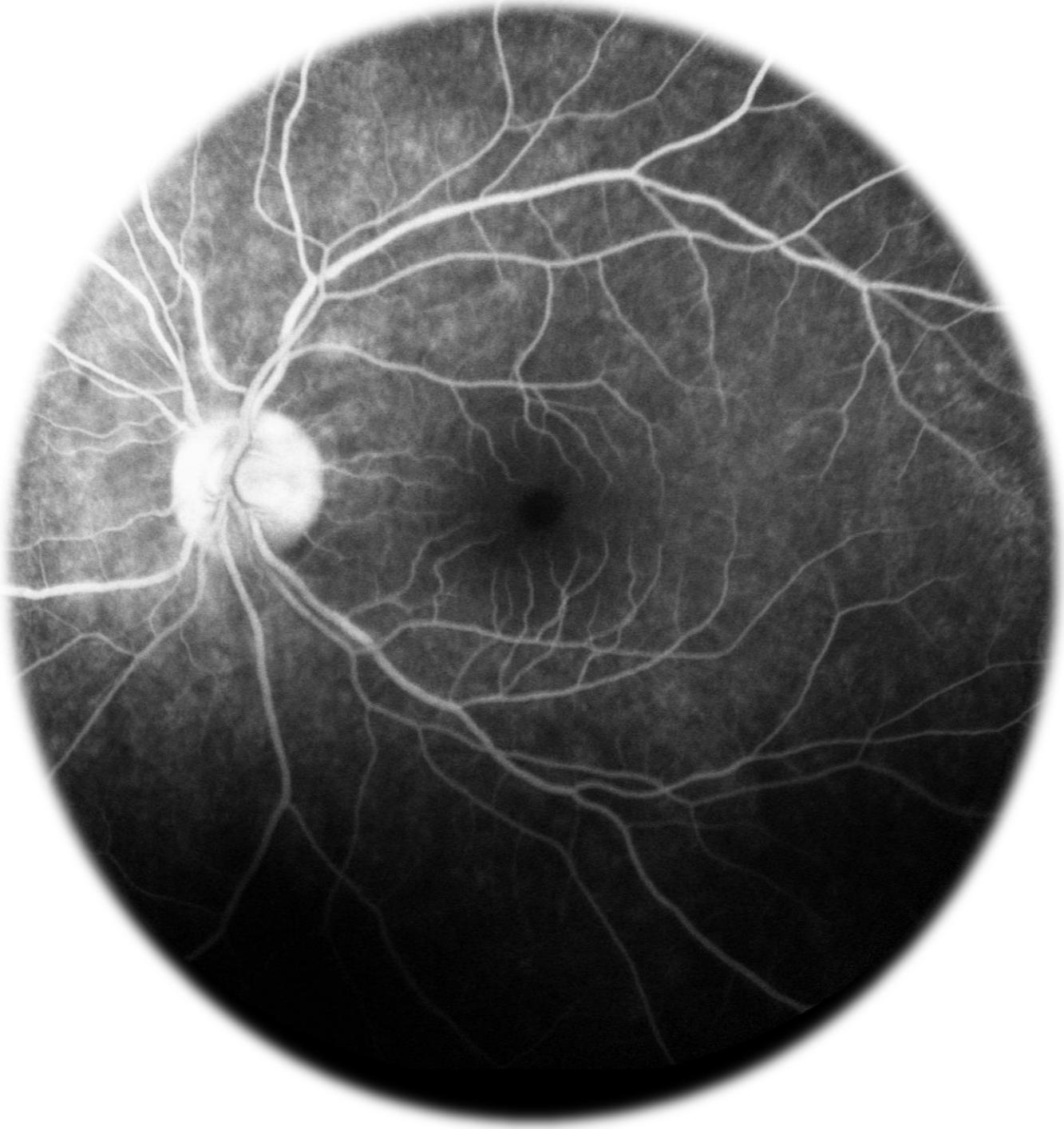

MEWDS

2e cas

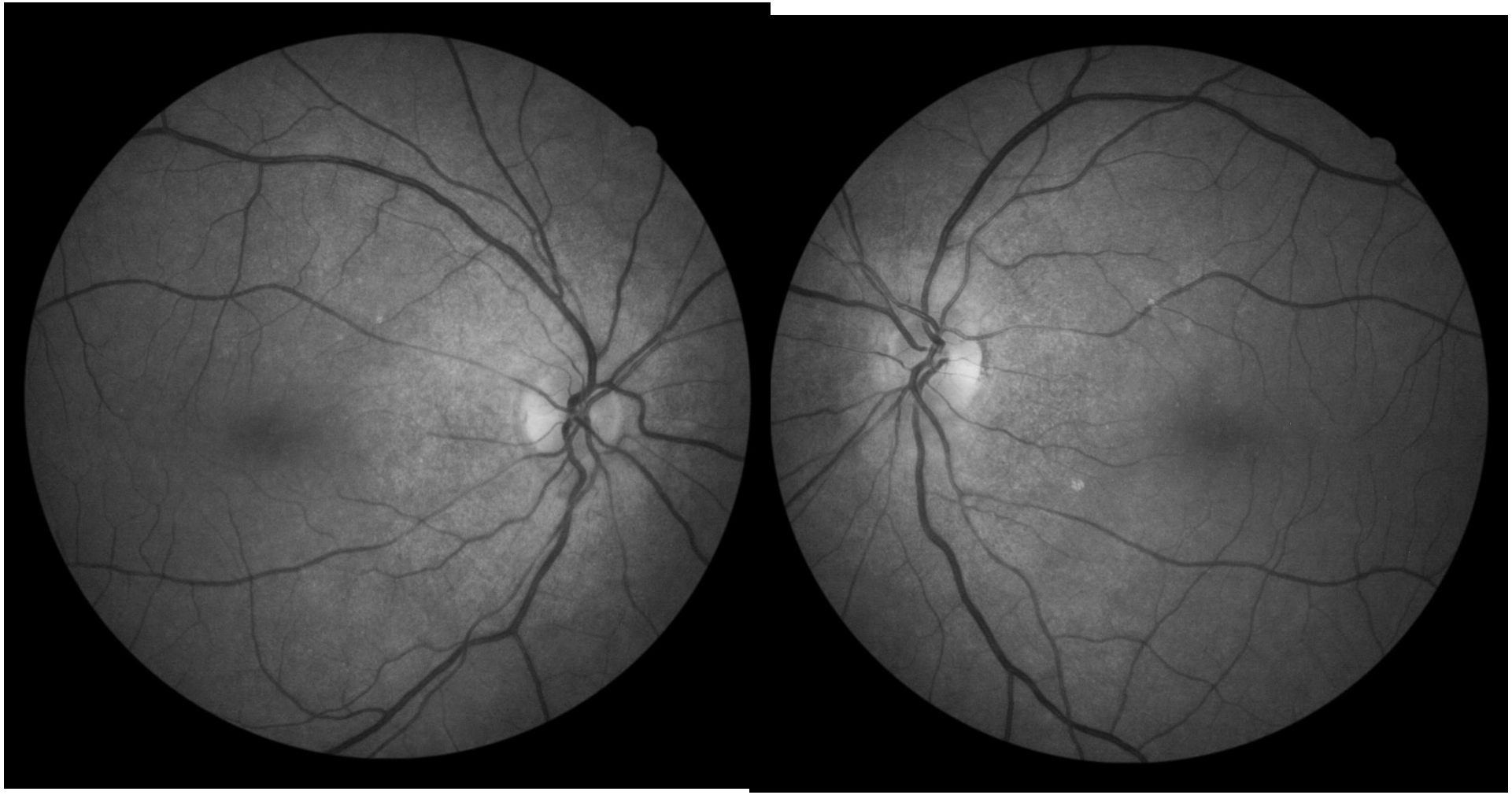

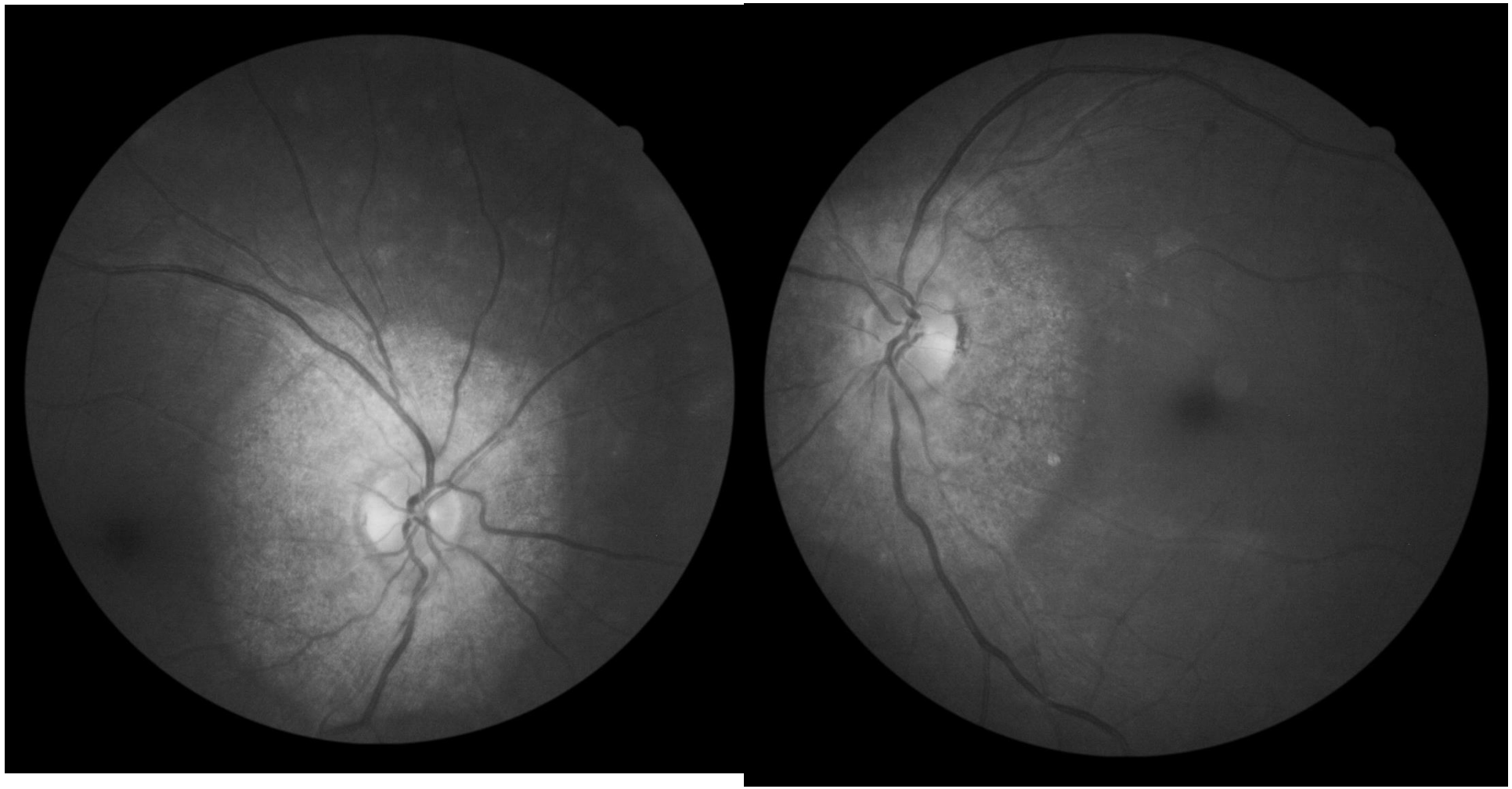

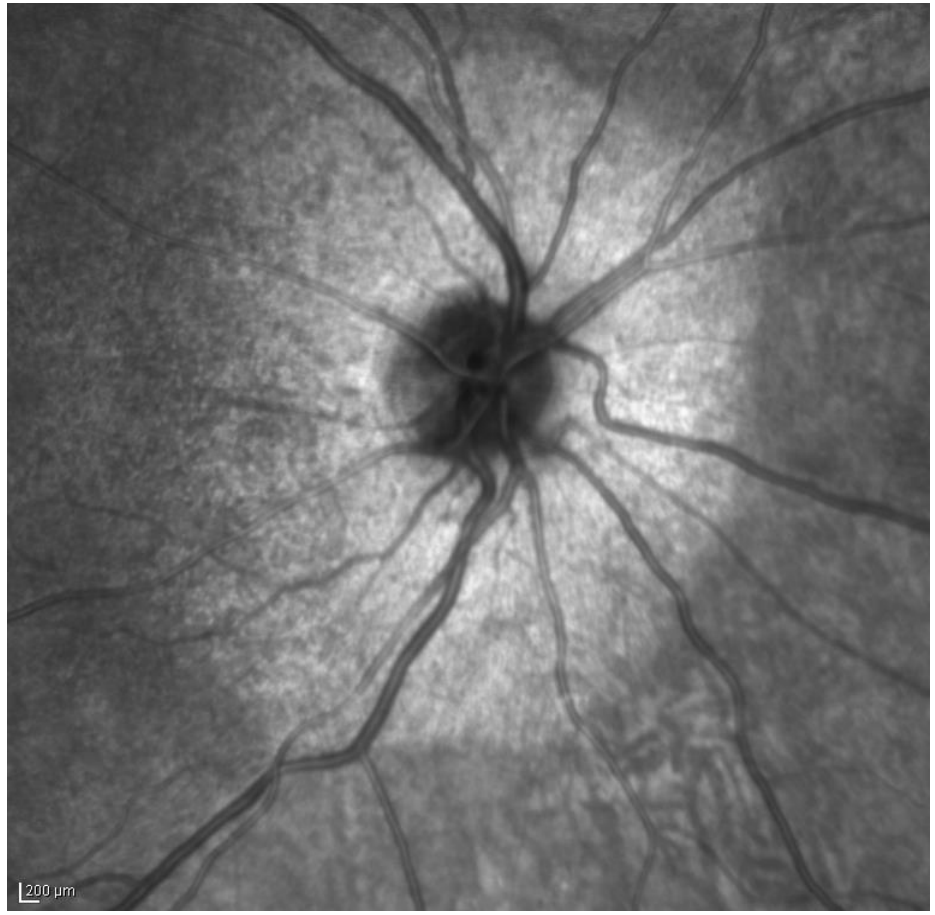
200 µm

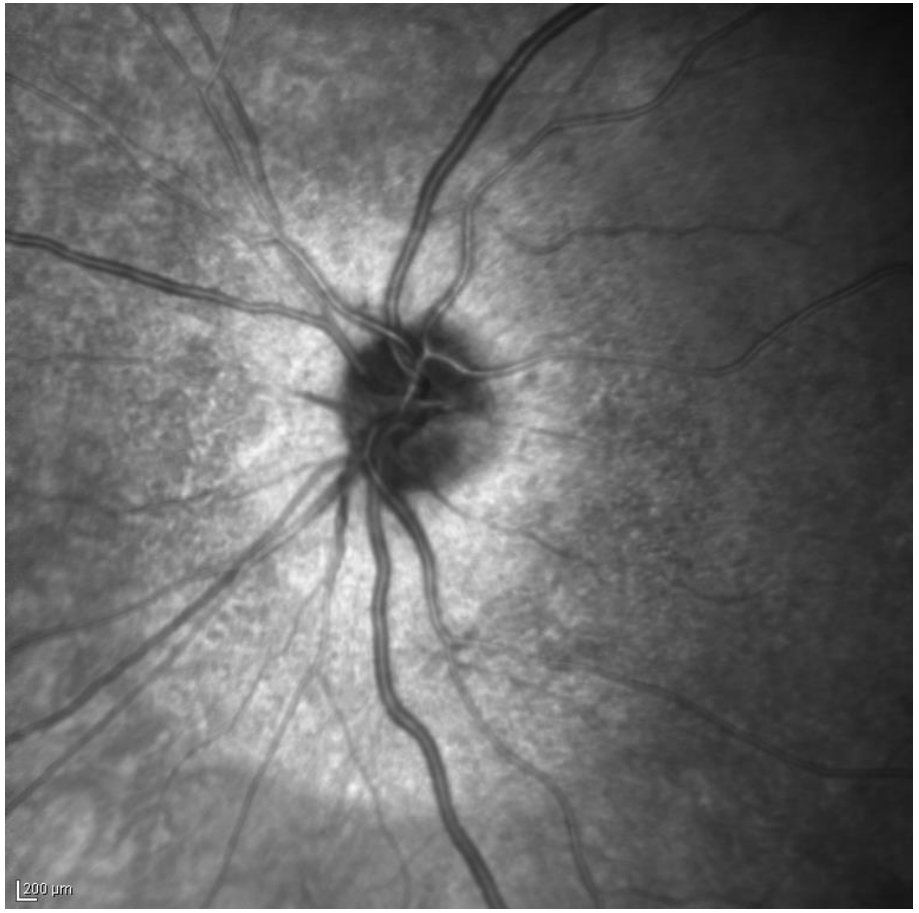
200 µm

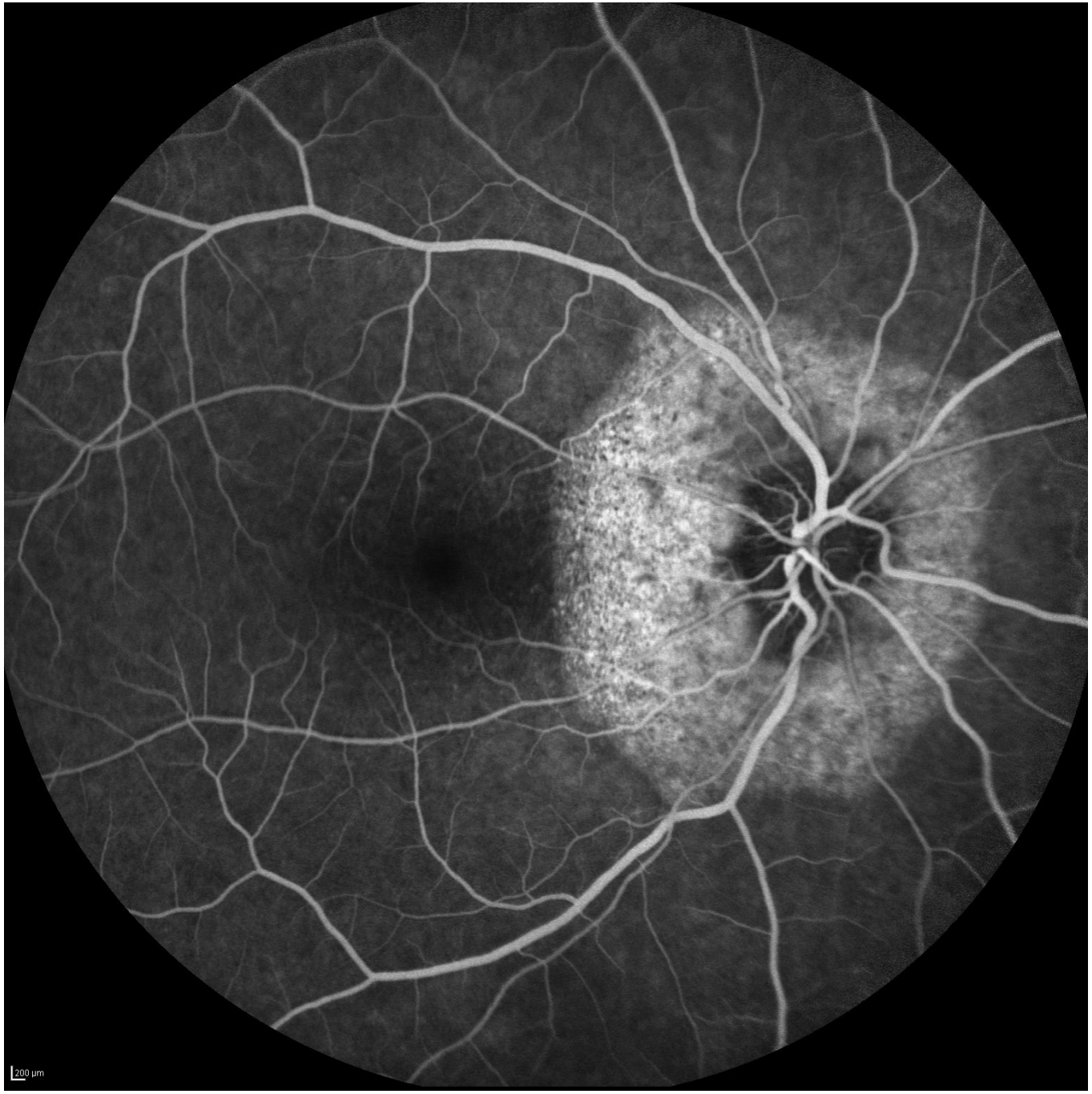
200 µm

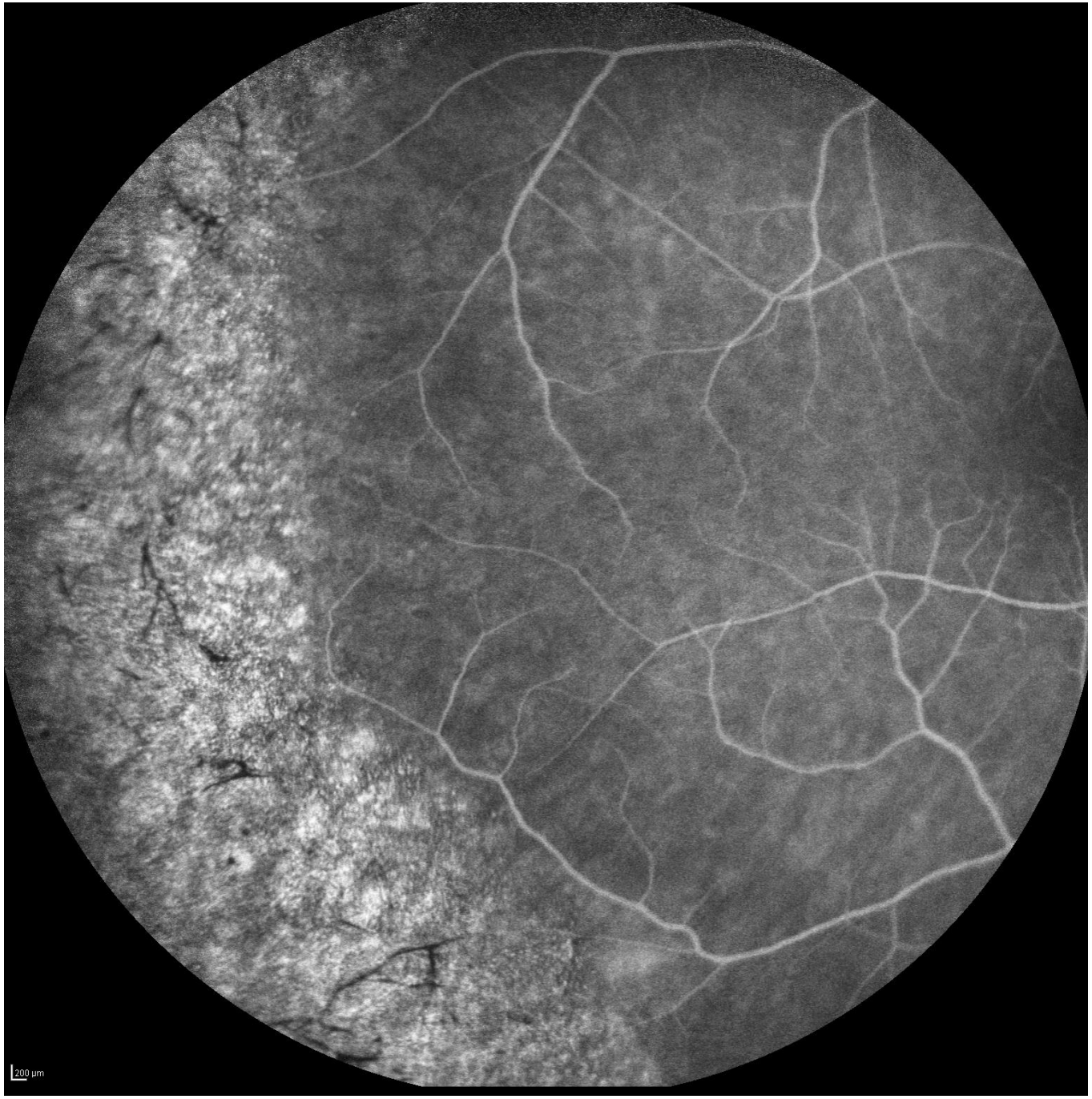
200 µm

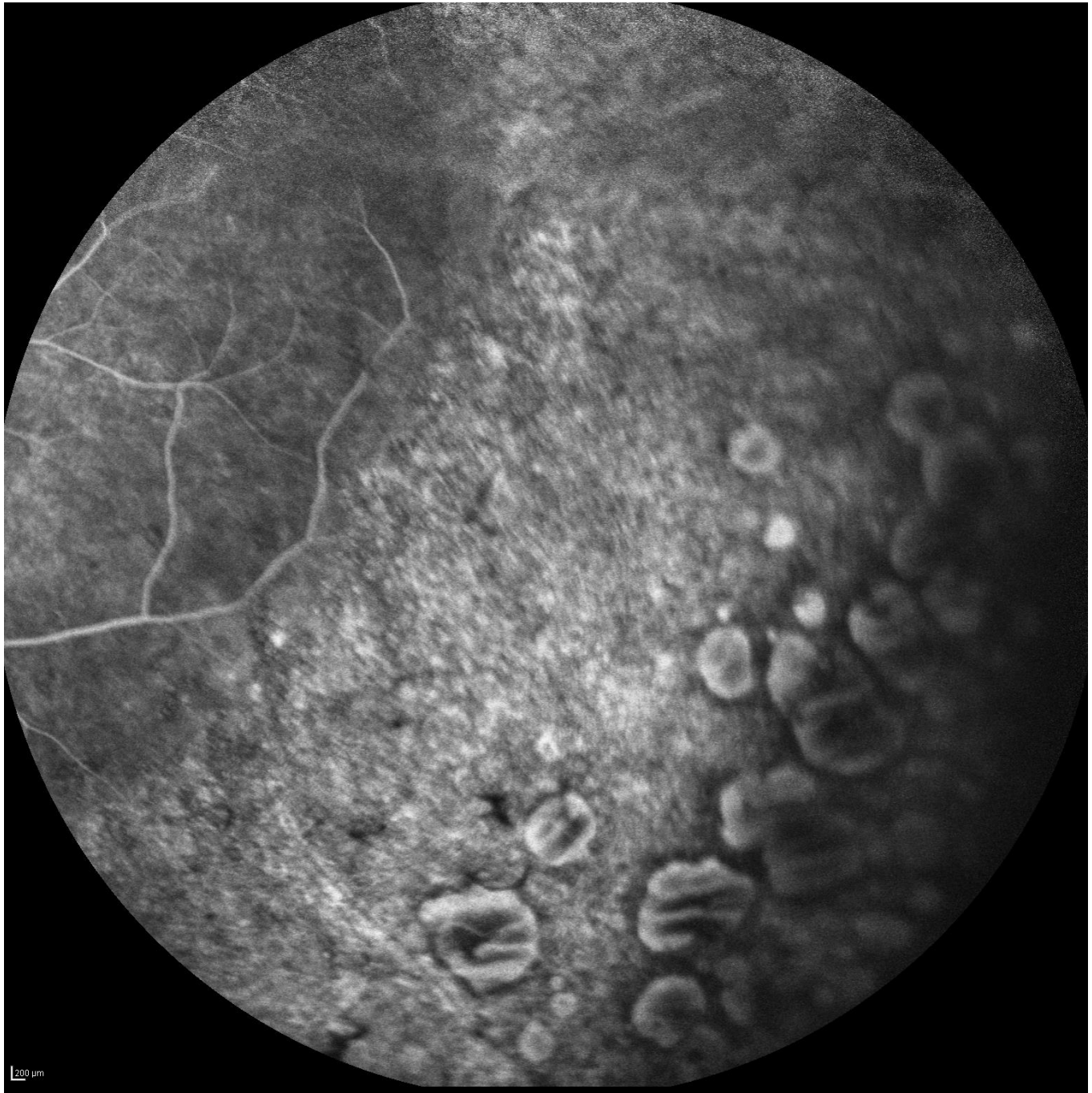
200 µm

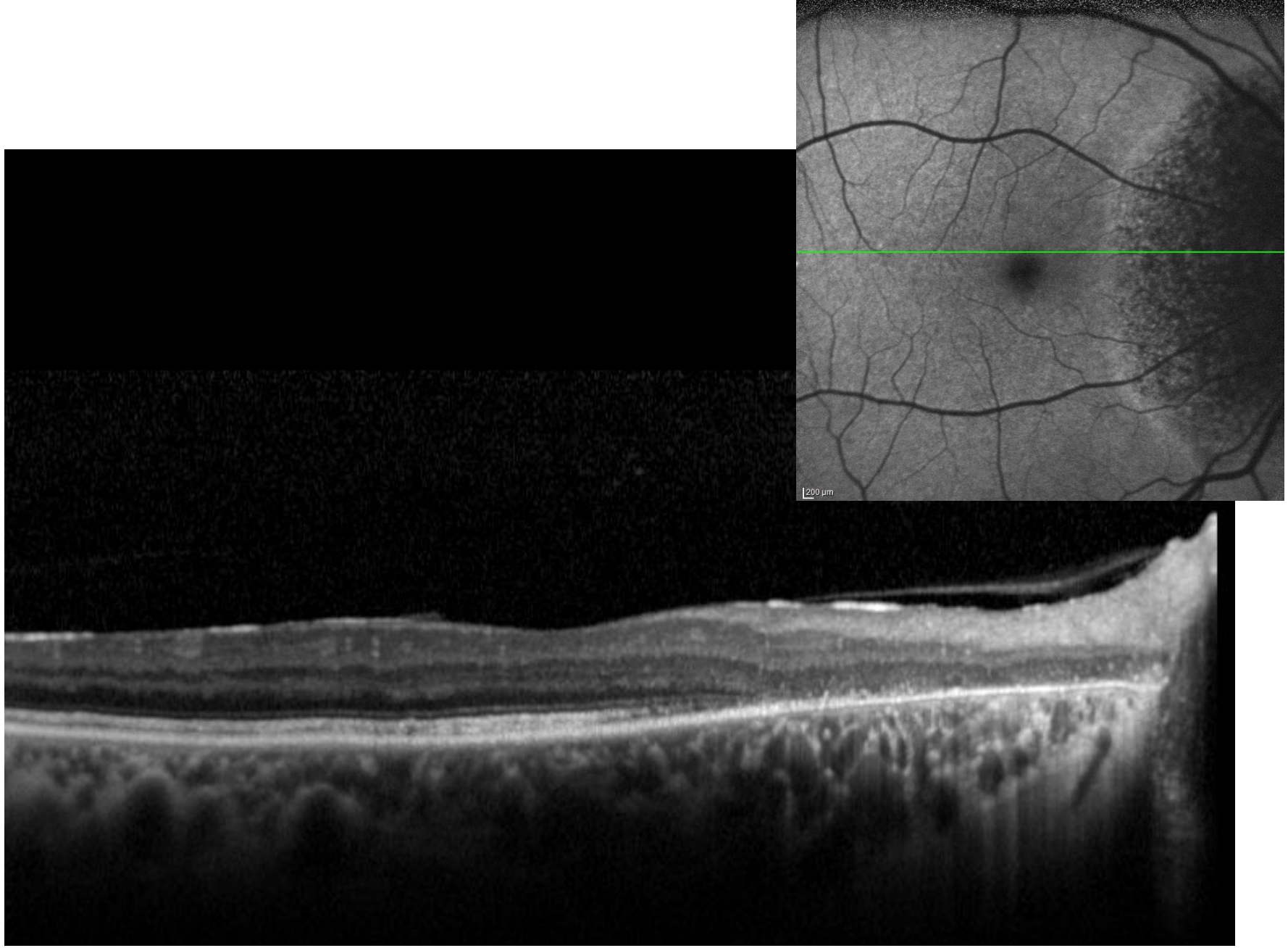
200 µm

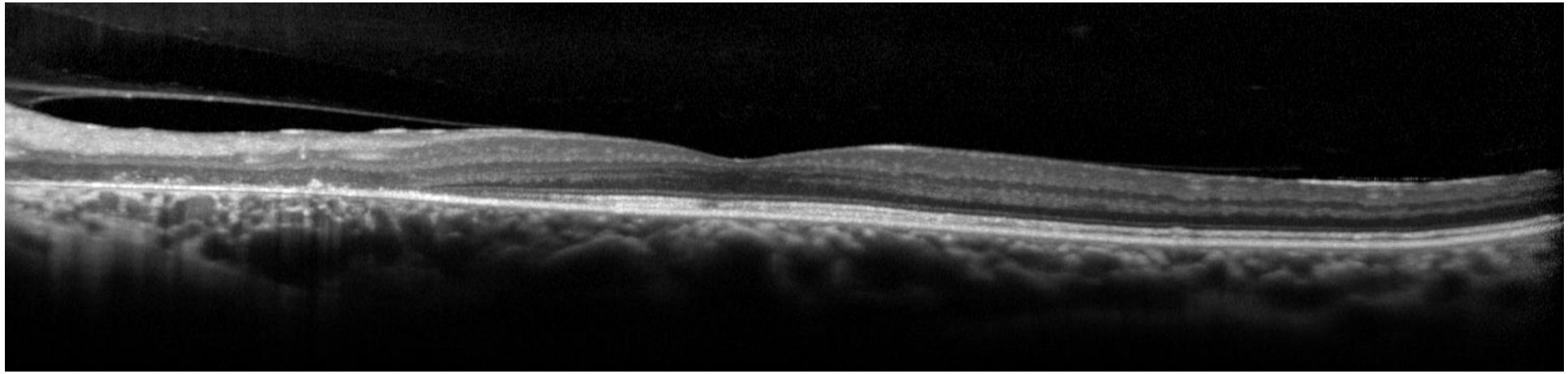

AZOOR

3ème cas

Examination

	RE	LE
BCVA	6/10, P3, M+/S+	10/10, P2, M-/S-
IOP	14	14
Slit Lamp	Normal	Normal

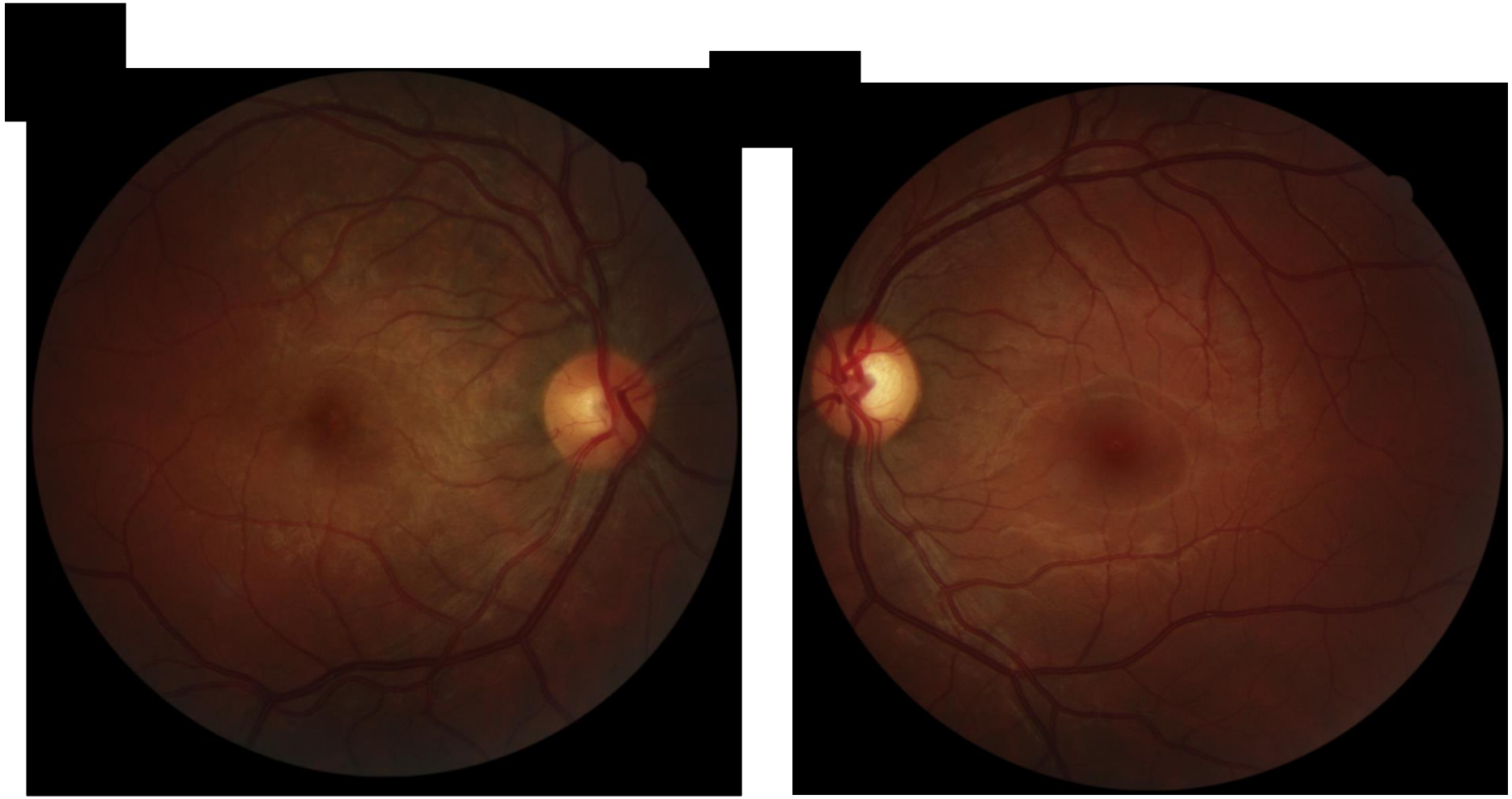

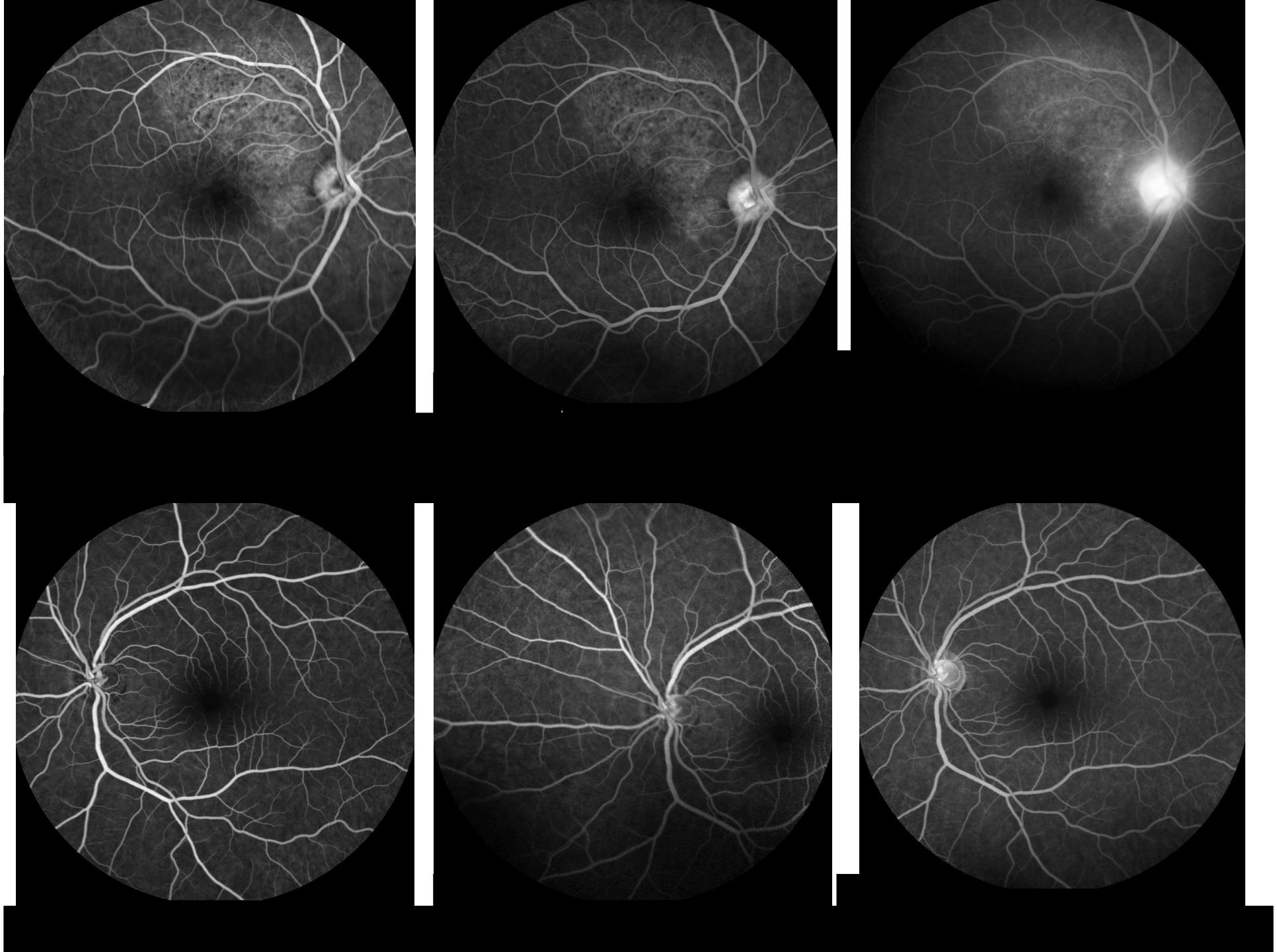

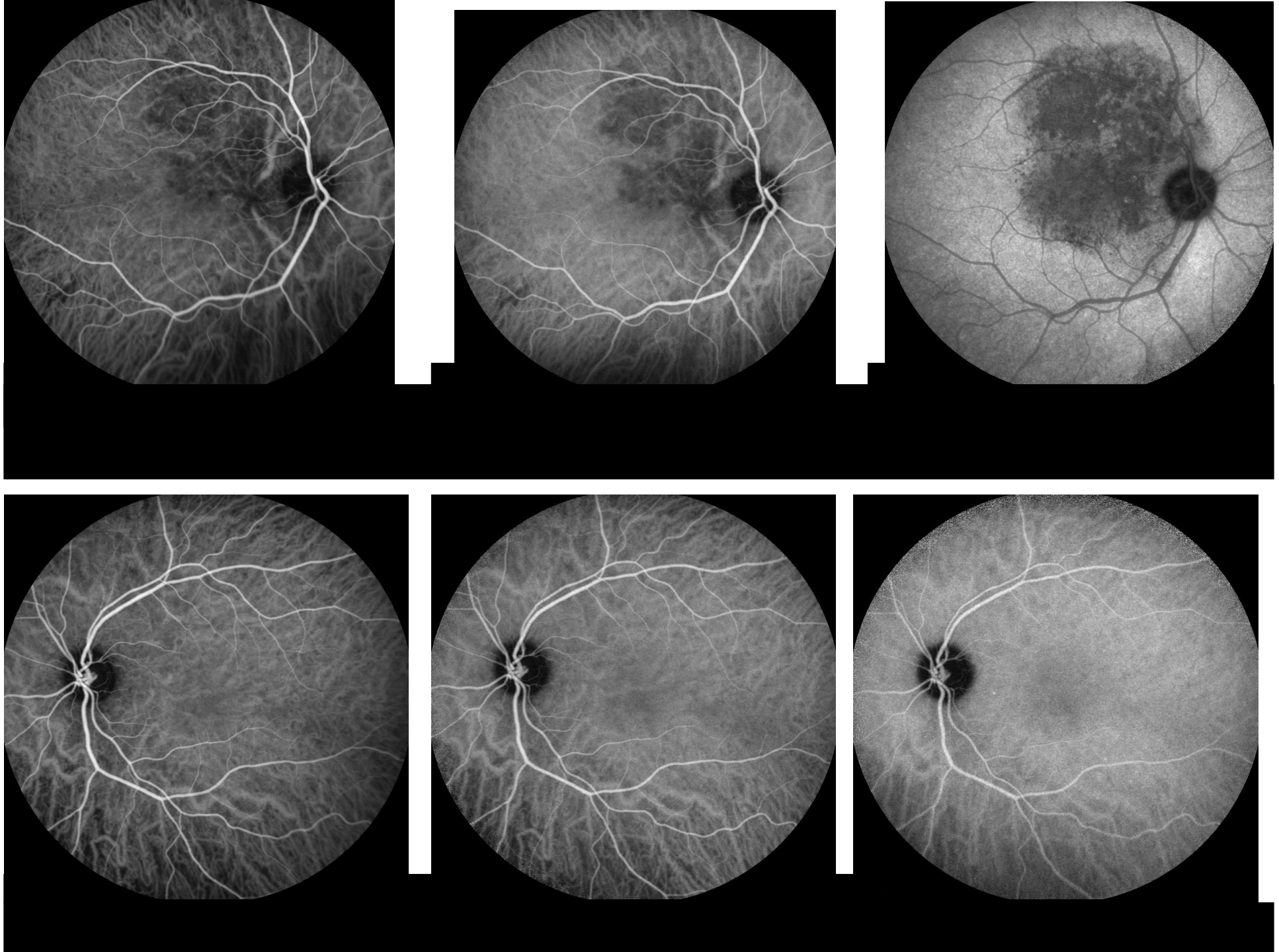

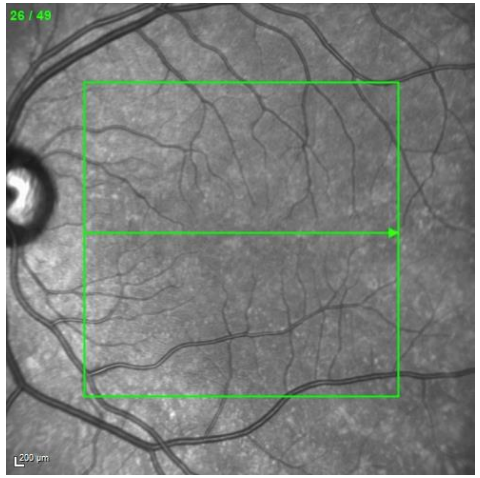
26 / 49
200 µm

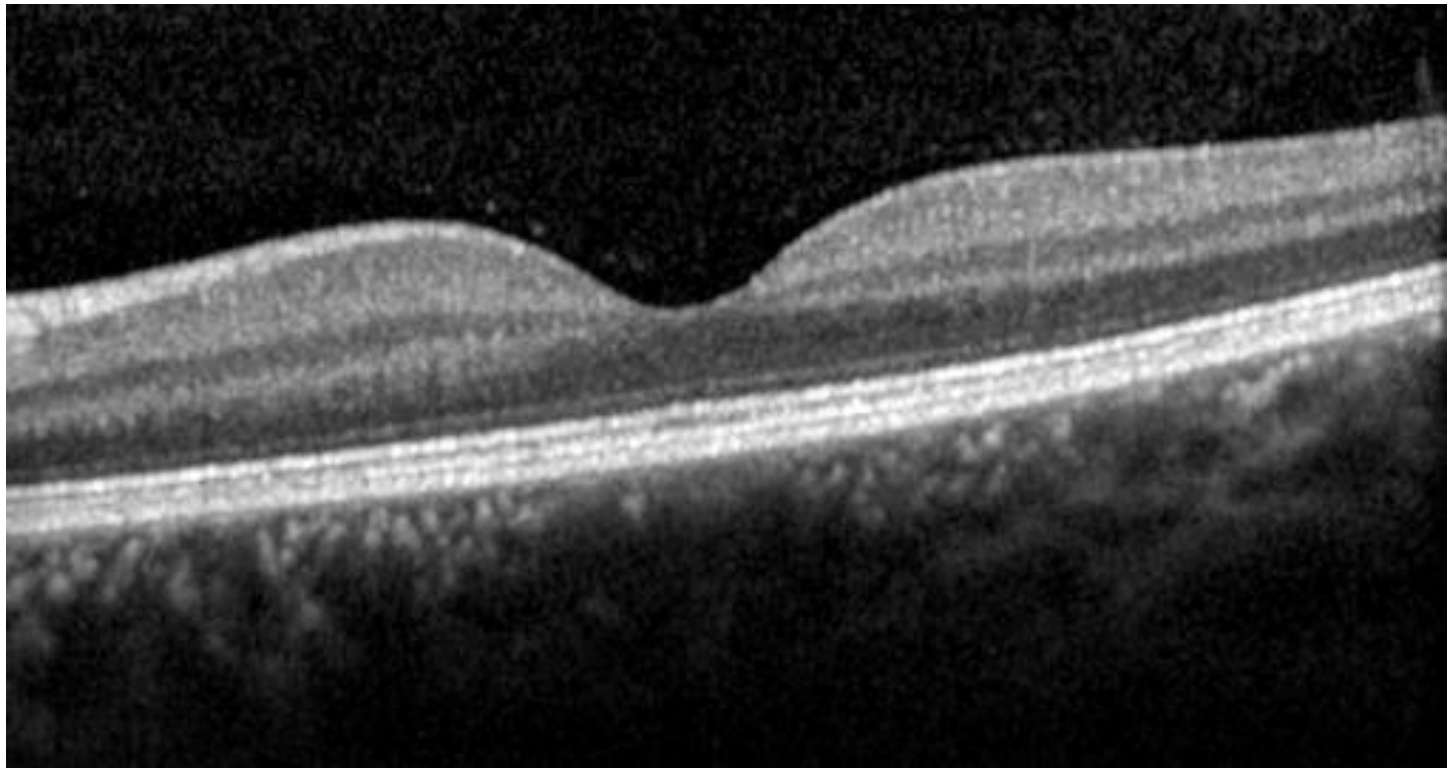

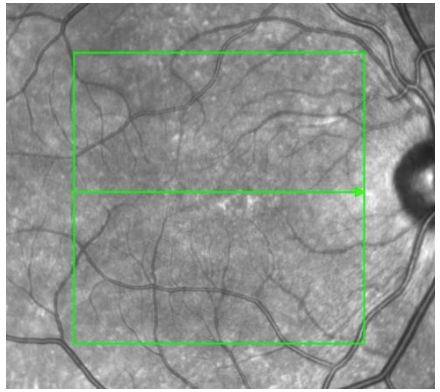

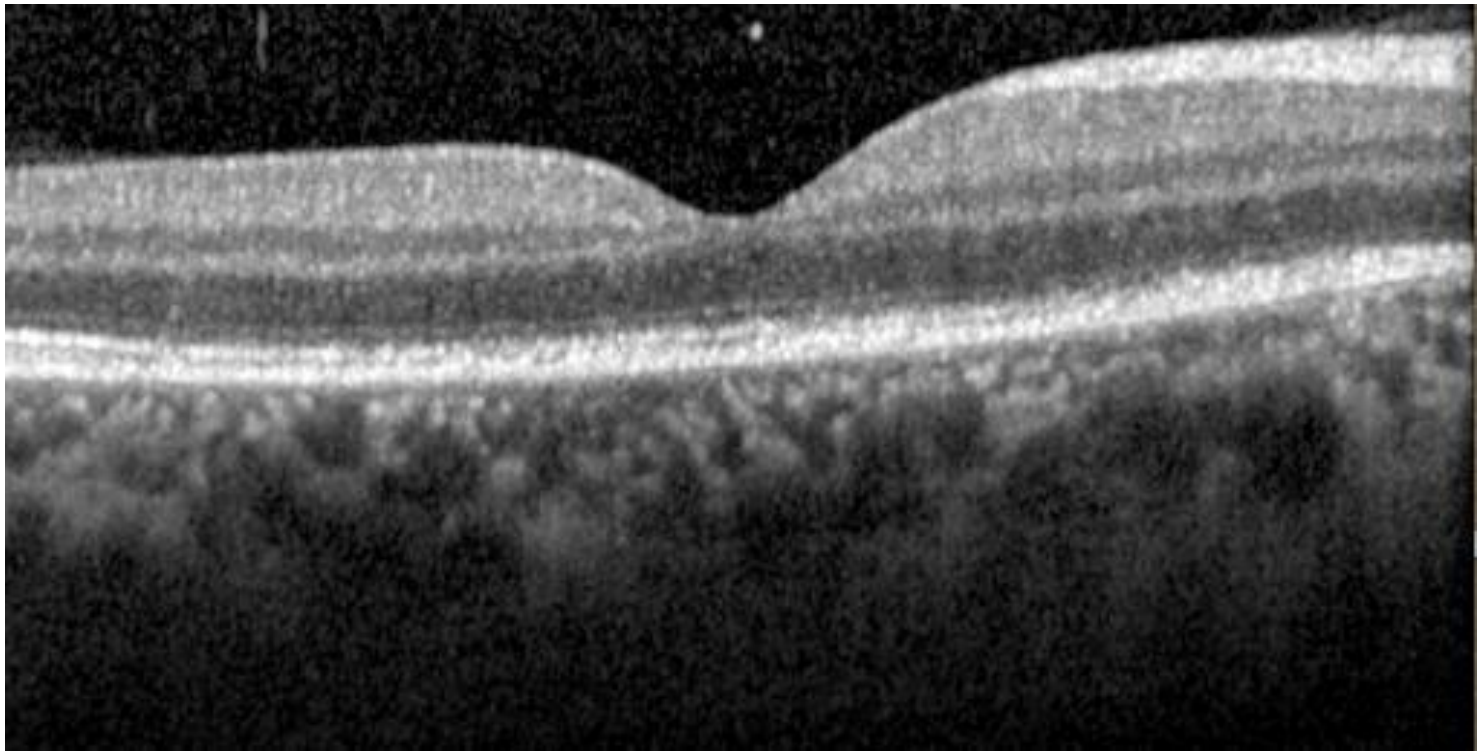

Placoïde syphilitique

4ème cas

Mme B 84 ans

Signes fonctionnels :

Baisse d'acuité visuelle de l'œil gauche

Myodesopsies bilatérales depuis plusieurs semaines

- Antécédents généraux :

-Lymphome B à grandes cellules stade IV - atteinte digestive initiale

Fin de chimiothérapie et rémission complète depuis Avril 2015

-Polyarthrite rhumatoïde, corticothérapie stoppée en 2016.

- Antécédents ophtalmologiques :

-Chirurgie de cataracte bilatérale en Juin 2016

Janvier 2017

0,6 AV 0,8
CA calme
0+ Hyalite 0,5+
Discret œdème Papille Œdème important

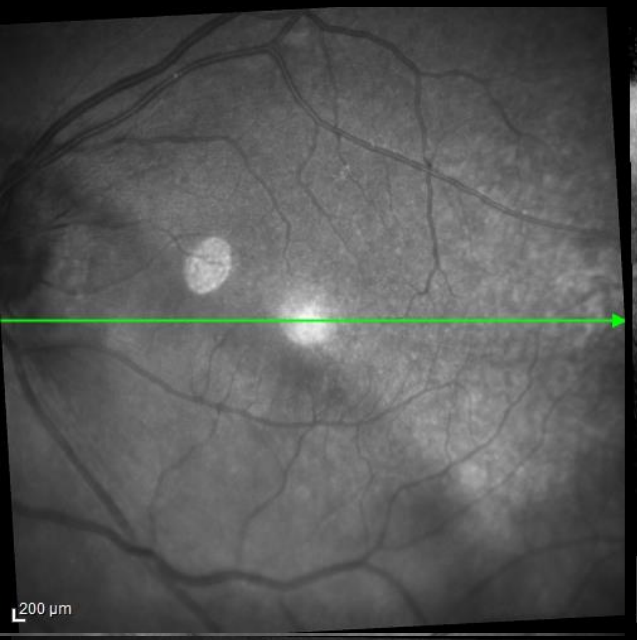

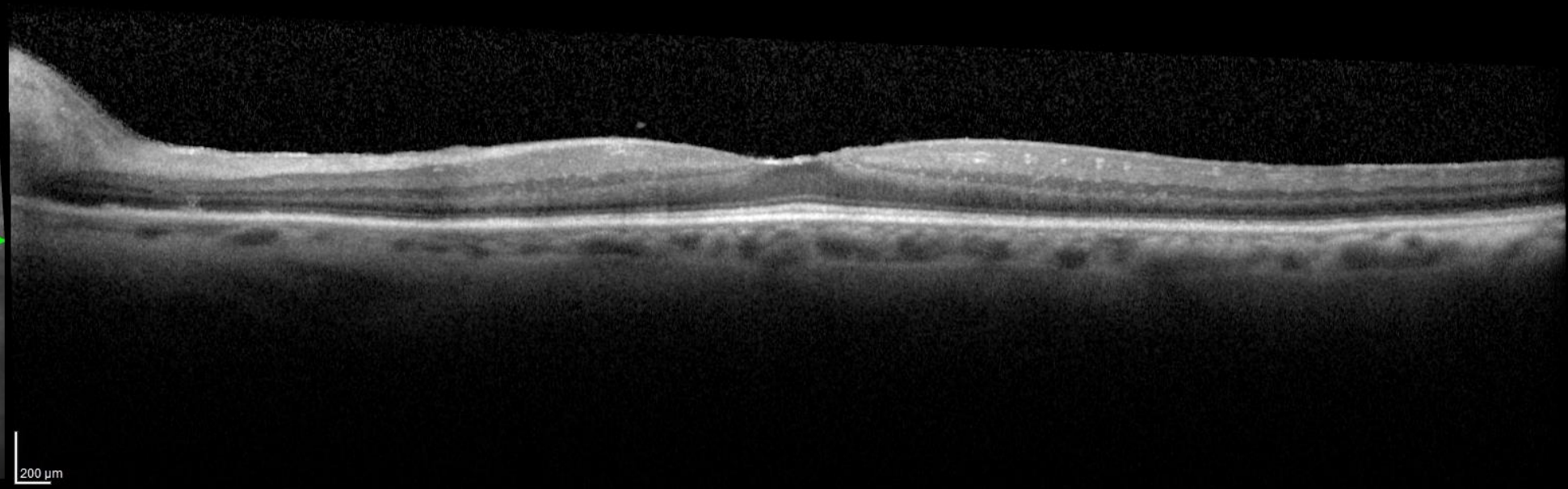

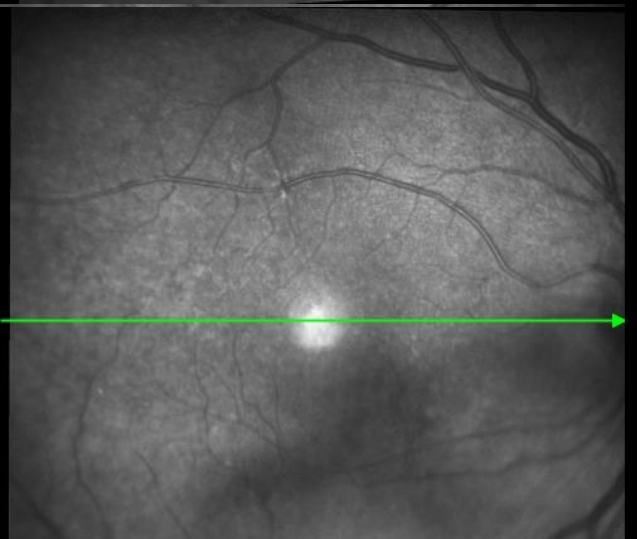

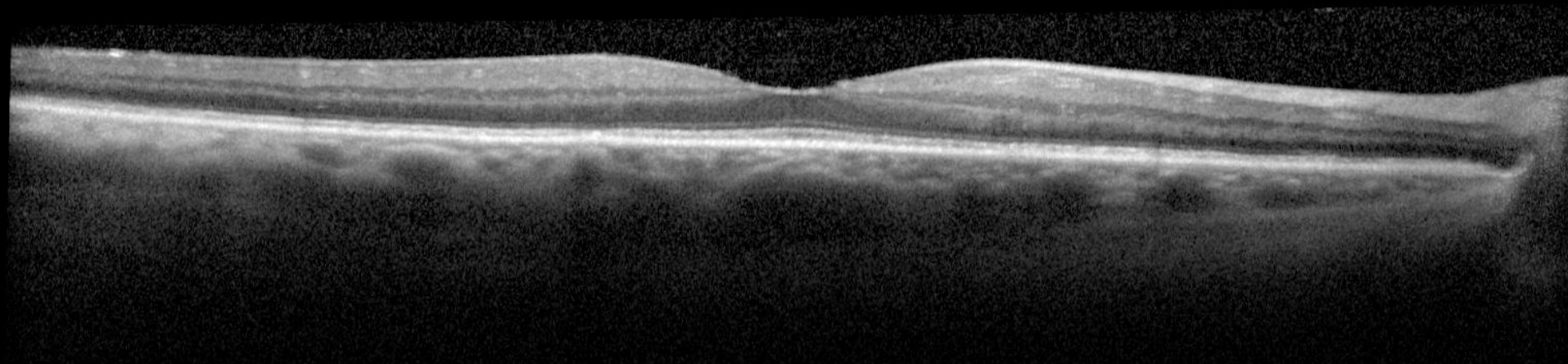

Contrôle de fixation: Tache aveugle
Cible de fixation: Central
Pertes de fixation: 3/16
Erreurs faux pos.: 0 %
Erreurs faux nég.: 4 %
Durée du test: 05:53

Fovéa: 33 dB

Stimulus: III, Blanc
Fond: 31,5 ASB
Stratégie: SITA-Standard

Diamètre de la pupille:
Acuité visuelle:
RX: +3.50 DS DC X

Date: 27-02-2017
Heure: 16:22
L'âge: 83

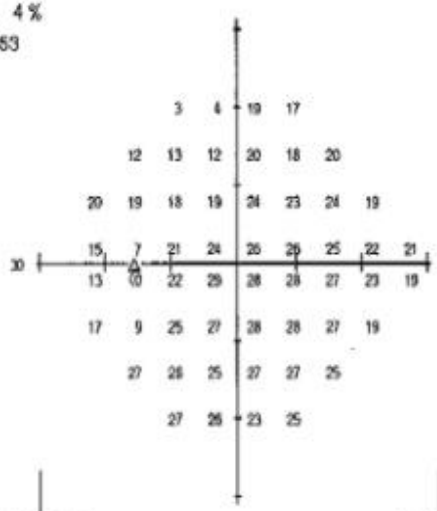



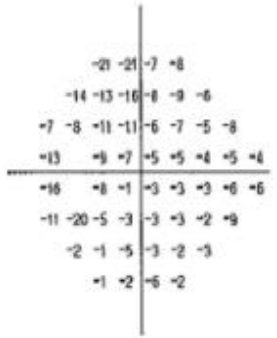

Déviation Totale



Déviation individuelle





:: < 5%
⊠ < 2%
▨ < 1%
■ < 0.5%

THG
Hors limites normales

VFI 85%

MD -5.97 dB P < 0.5%
PSD 4.46 dB P < 0.5%

NEAU

Nomen :

Datum

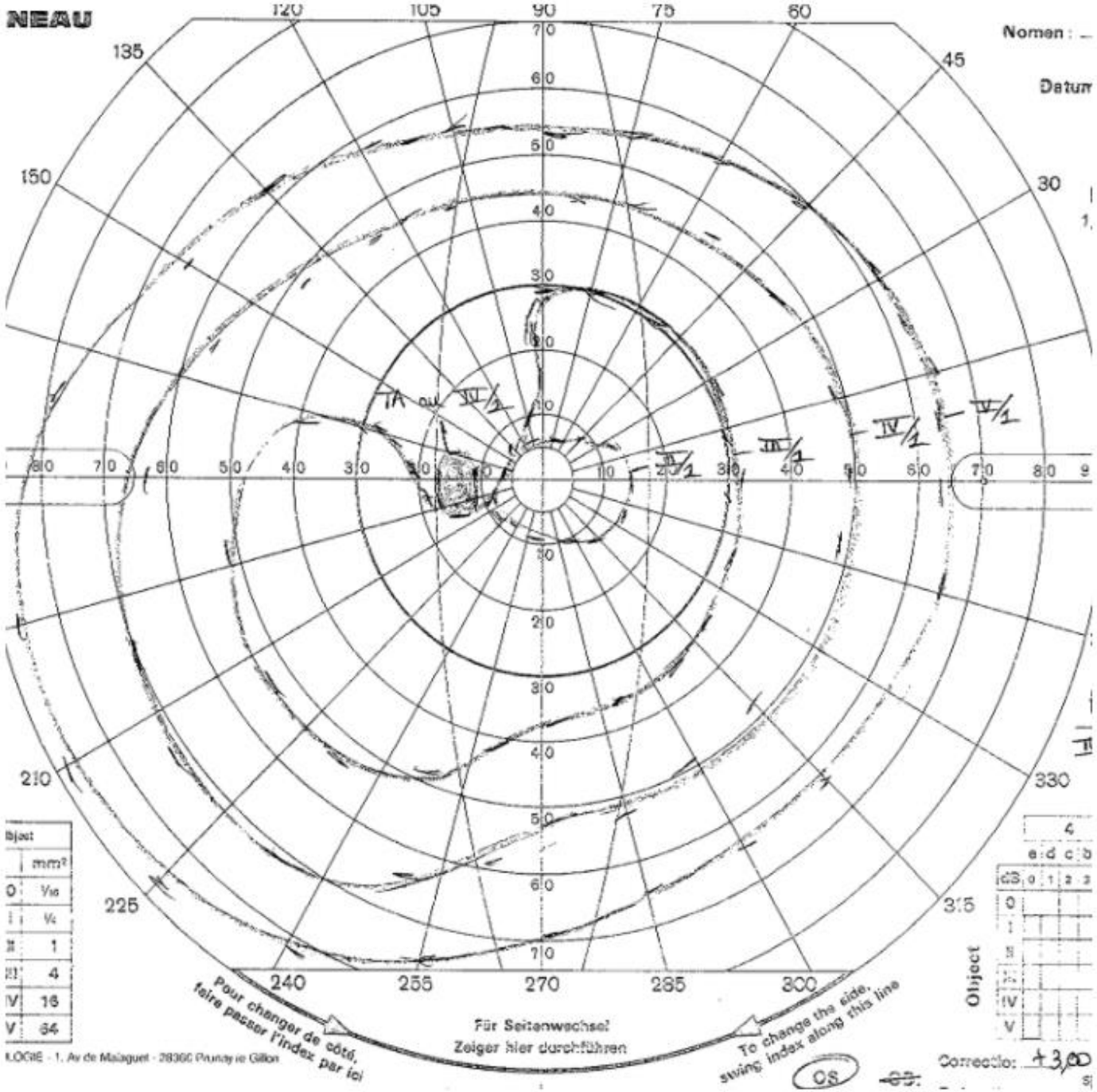

MAI 2017

0,6 AV 0,8
CA : Quelques cellules ODG
7,3 Flare 10,2
0,5+ Hyalite 0,5+

Bilan étiologique :

Juin 2017
Quantiferon négatif - ECA 49
Lymphopénie à 0,86 (<1,5 G/L)
Sérologies négatives :
Lyme TPHA VDRL Rickettsiose Bartonnella

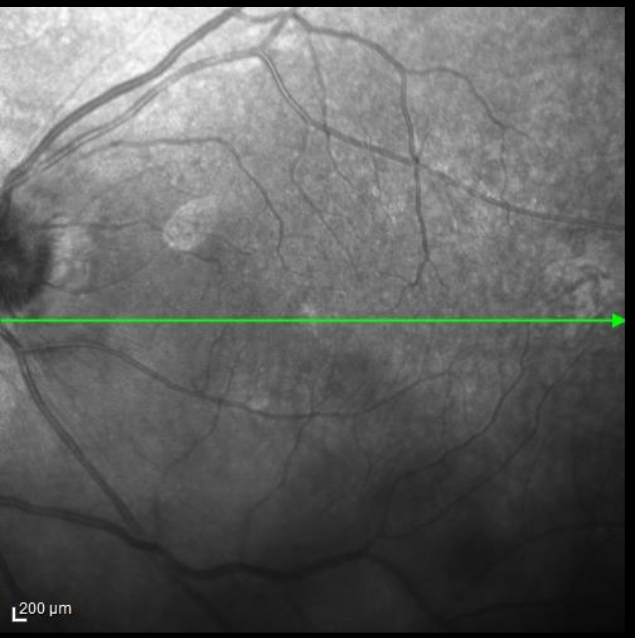

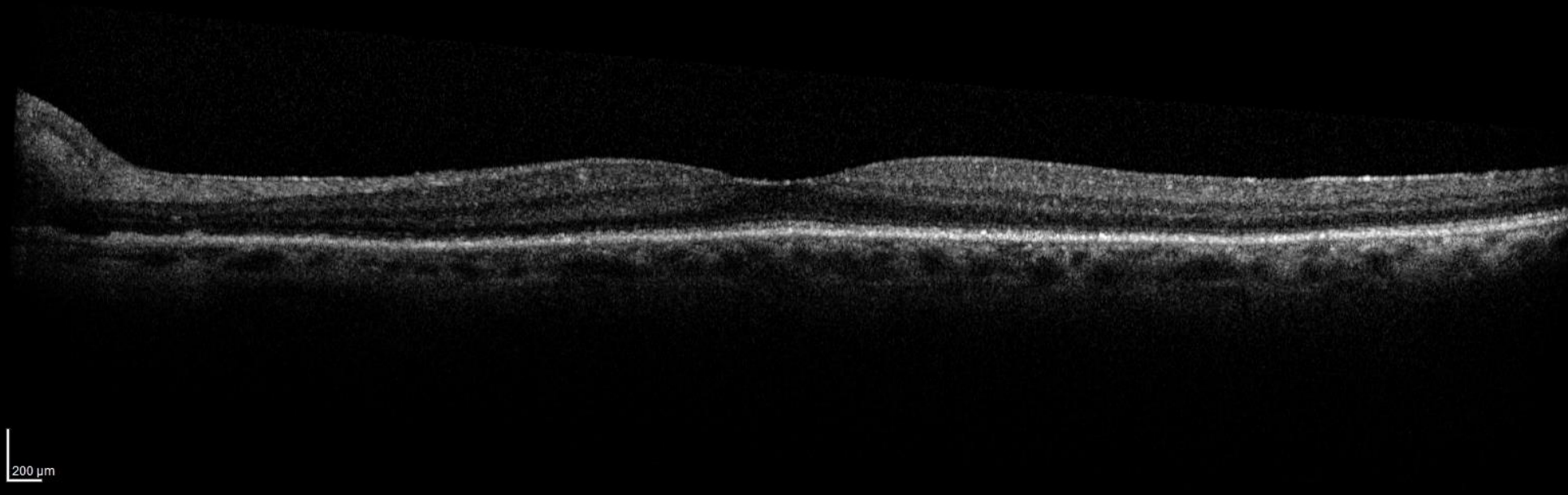

Juillet 2017

0,5 AV 0,2
CA calme ODG
1+ Hyalite 1+

Contrôle imagerie n°2
PET scanner normal
IRM cérébrale normale

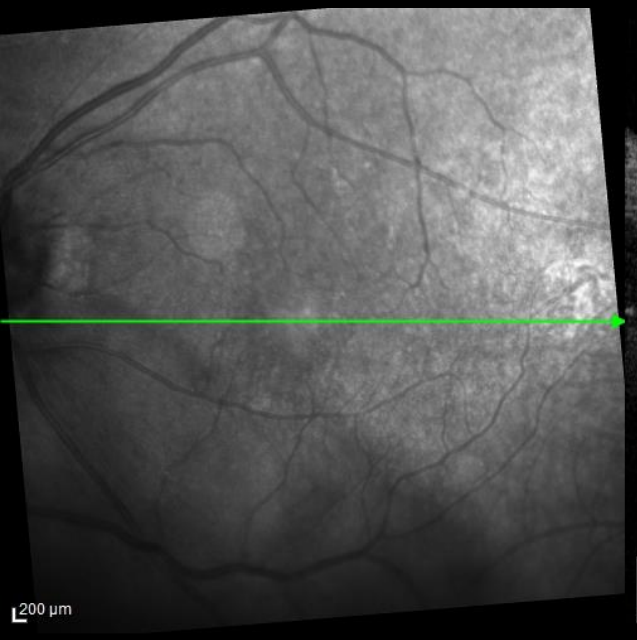

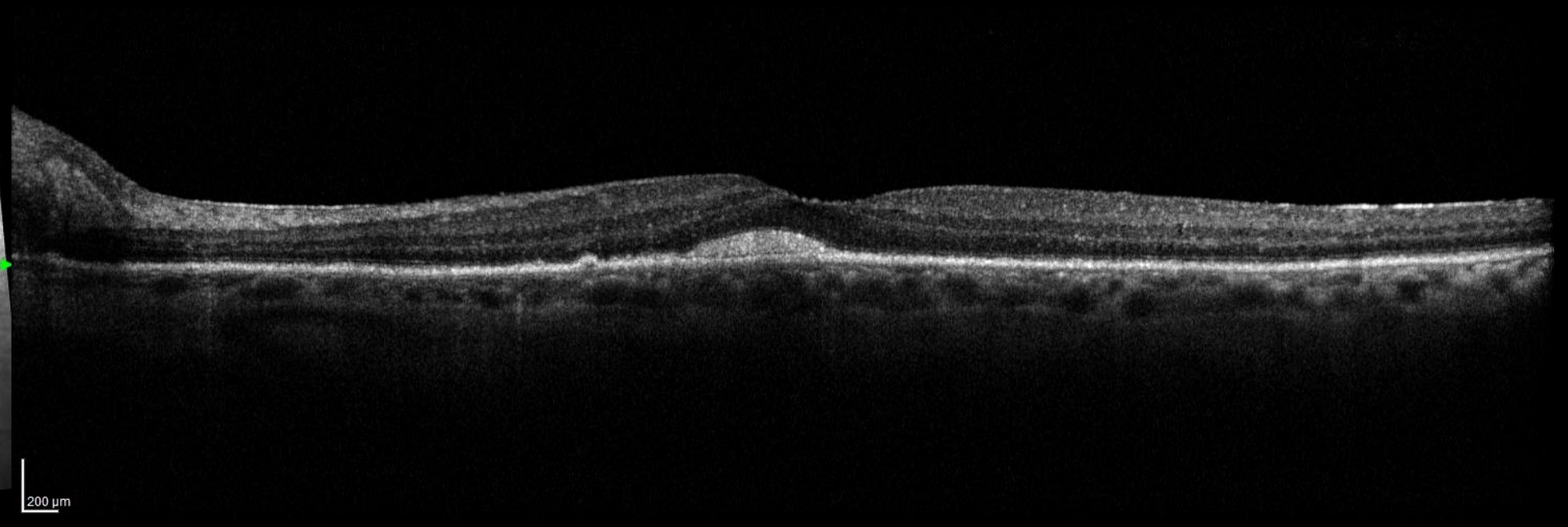

Juillet 2017

0,5 AV 0,2
CA calme ODG
1+ Hyalite 1+

Réunion de concertation pluri disciplinaire hématologique :
Nécessité réalisation prélèvement occulaire afin d'étayer l'hypothèse d'une rechute occulaire lymphomateuse

Refus de la patiente qui préfère attendre.

Contrôle imagerie n°2
PET scanner normal
IRM cérébrale normale

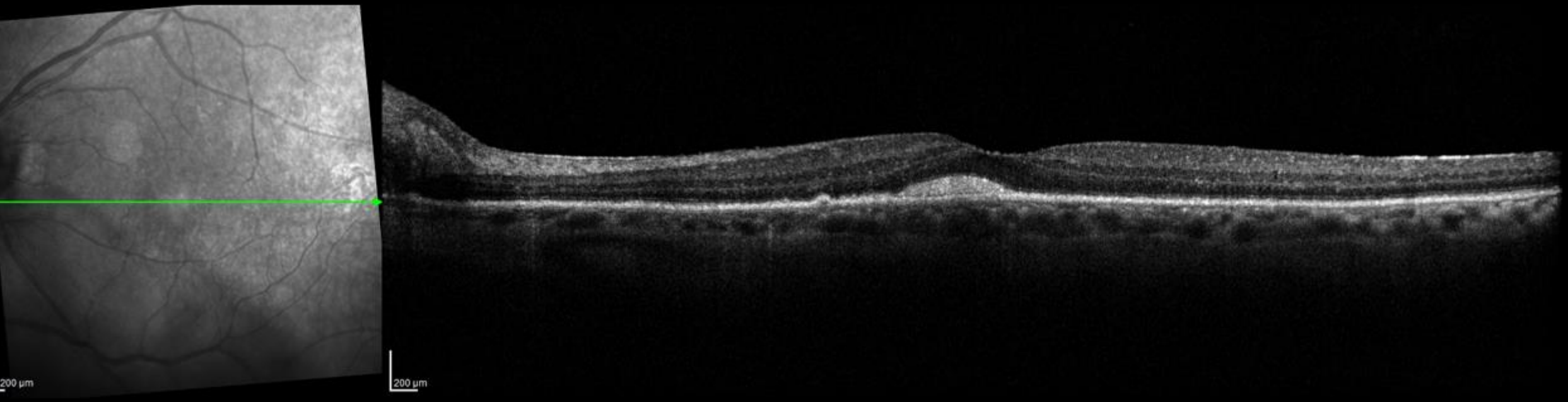

Septembre-Octobre 2017

0,4 AV 0,4
CA : quelques cellules ODG
1+ Hyalite 1+

Organisation vitrectomie diagnostique avec ponction de chambre antérieure

Patiente préfère temporiser : intervention programmée pour Janvier 2018

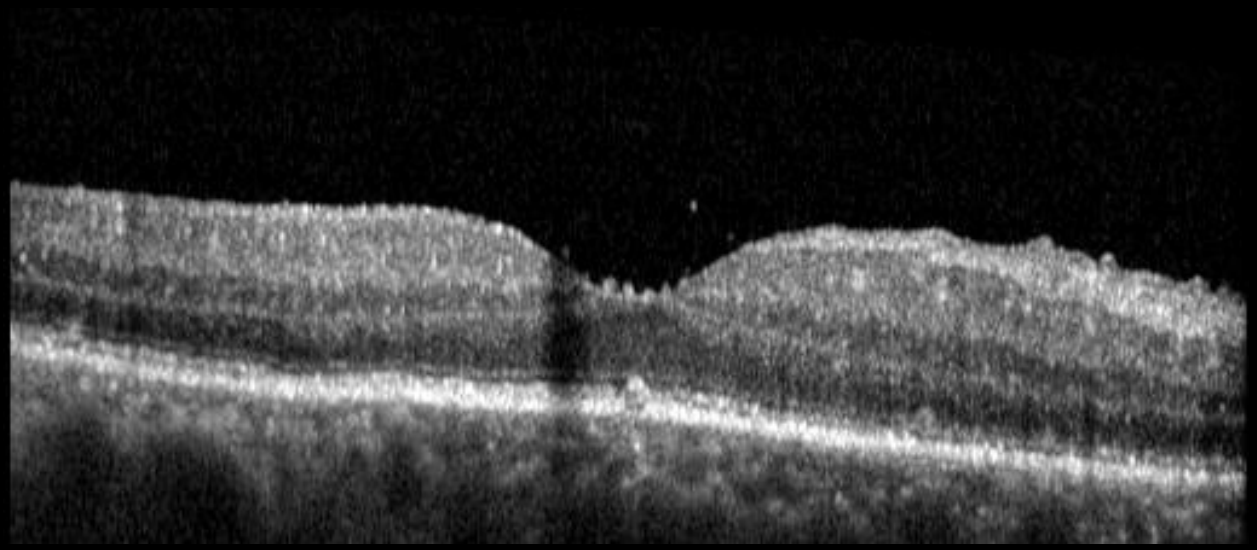

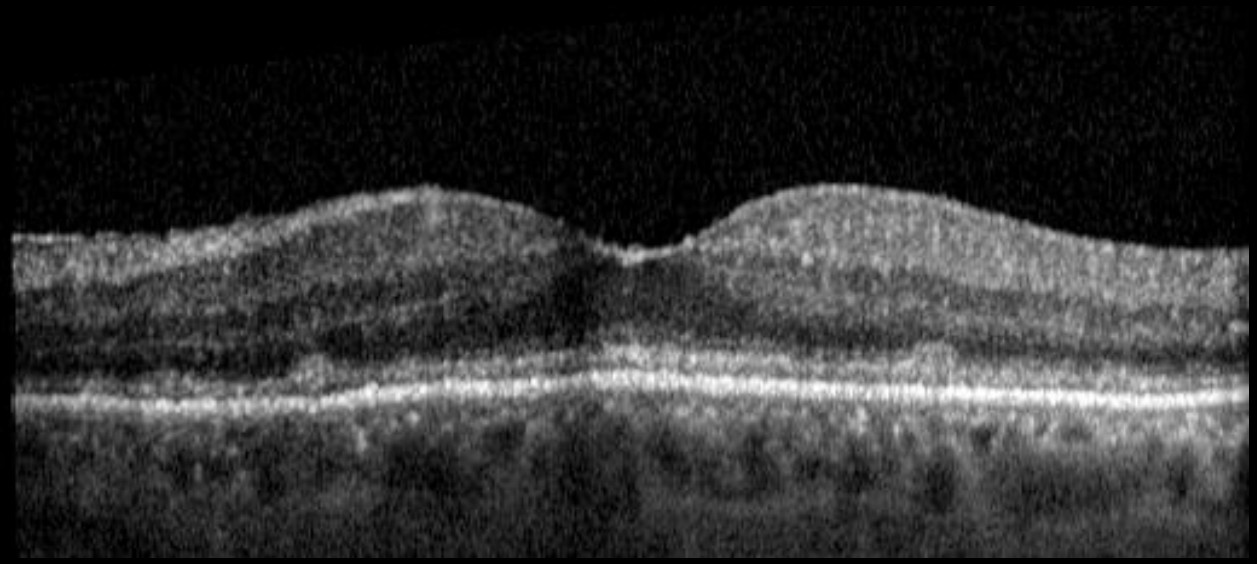

Décembre 2017 – Janvier 2018

Syndrome confusionnel, vertiges, déficit sensitif hémicorps droit.
Baisse de vision œil droit

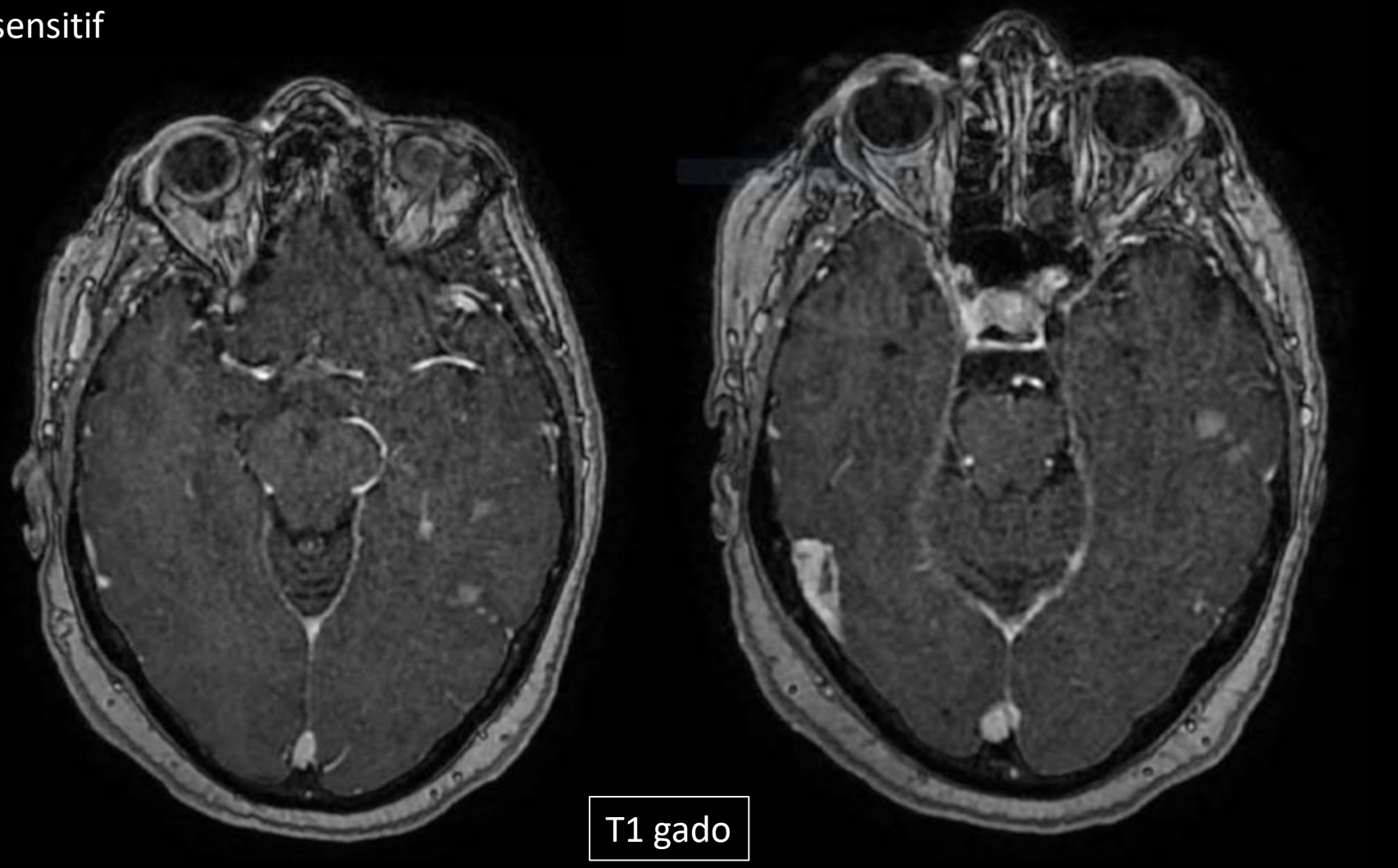

+Hypersignal T2 péri lésionnel
Effacement des sillons et collapsus du ventricule latéral gauche.

Prise en charge hématologique : Février 2018

- Lymphopénie à 60/mm3 Thrombopénie 67000
- Myélémie
- Scanner thoraco-abdomino-pelvien : pas de lésions suspectes.
- Reprise chimiothérapie :

Rituximab 750 mg

Méthotrexate 3g + Acide folinique à partir de h 24 post Méthotrexate

Mars 2018

PL+ AV 0,5
CA calme ODG
1+ Hyalite 0 à 0,5+

Au total :
Atteinte cérébrale et oculaire secondaire d’un lymphome systémique, de type lymphome B diffus à grandes cellules.

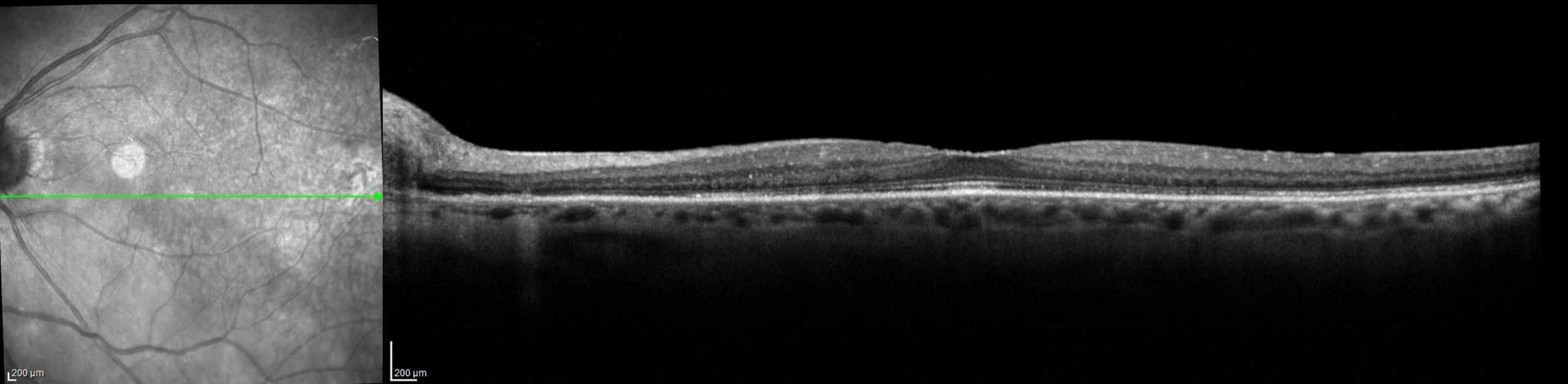

Cas clinique n°5

Monsieur L. 71 ans

BAV depuis
9 mois

0,3 – 0,2

Hyalite
1-2+

Œdème
maculaire
bilatéral

malgré
prednisone
per os
60➔10mg/j

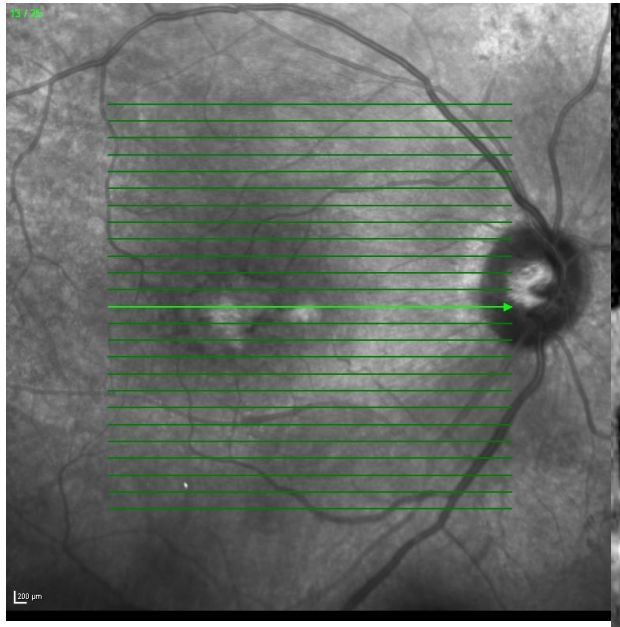
200 µm

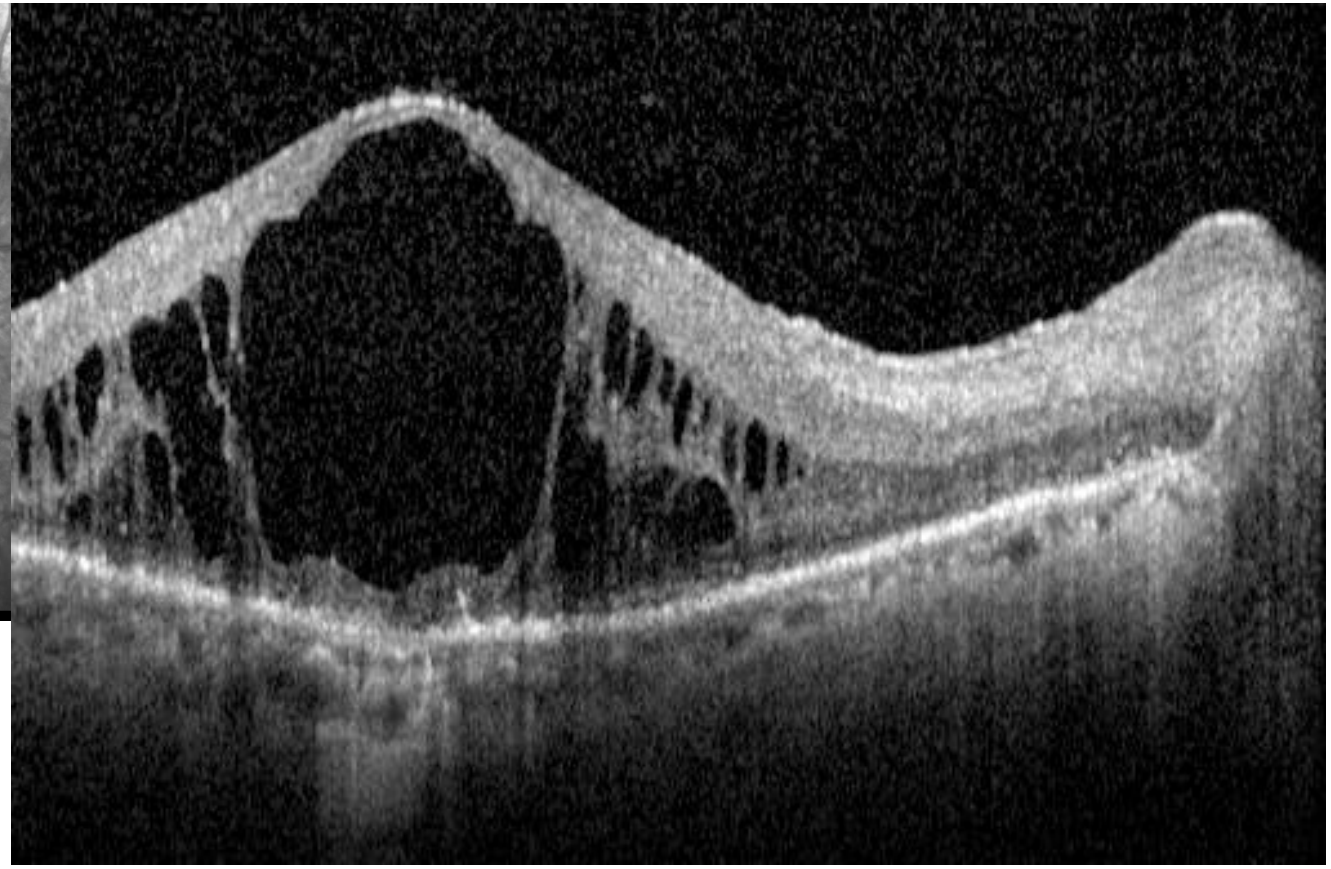

200 µm
12/03/2015, OD
AF 55° ART(17)
HEIDELBERG ENGINEERING
200 µm
12/03/2015, OS
AF 55° ART(64)
HEIDELBERG ENGINEERING

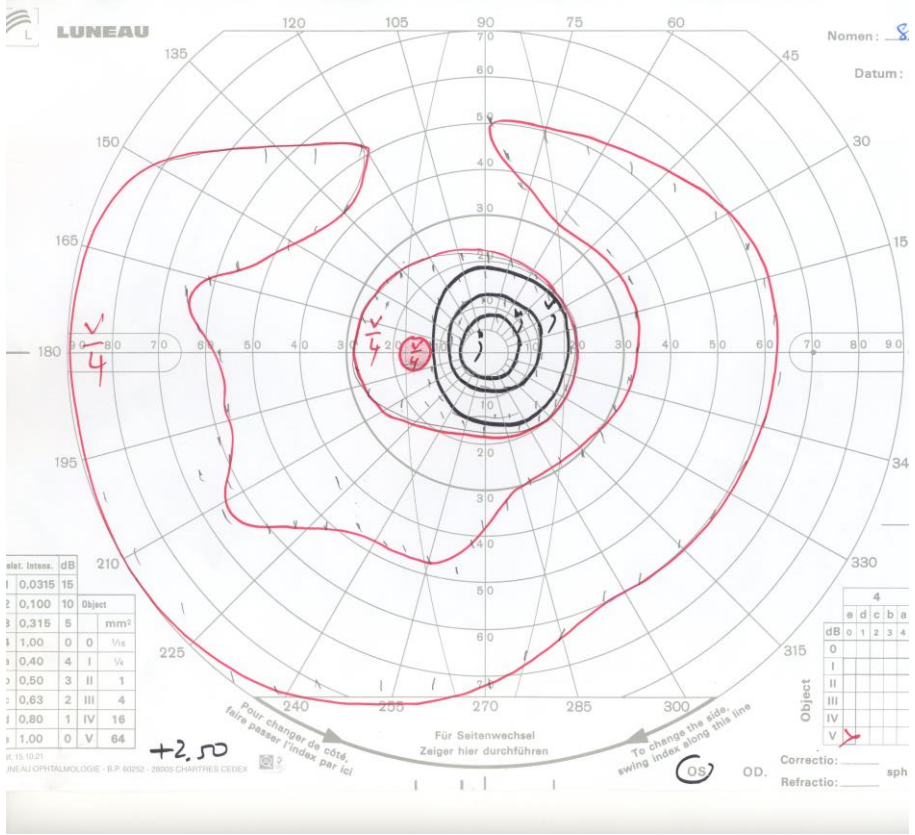
LUNEAU
Nomen:
Datum:
+2,50
Pour changer de côté, faire passer l'index par ici
Für Seitenwechsel Zeiger hier durchführen
To change the side, swing index along this line
OS.
OD.
Correctio:
Refractio:
sph
Object
mm²
LUNEAU OPHTALMOLOGIE - B.P. 60252 - 28005 CHARTRES CEDEX

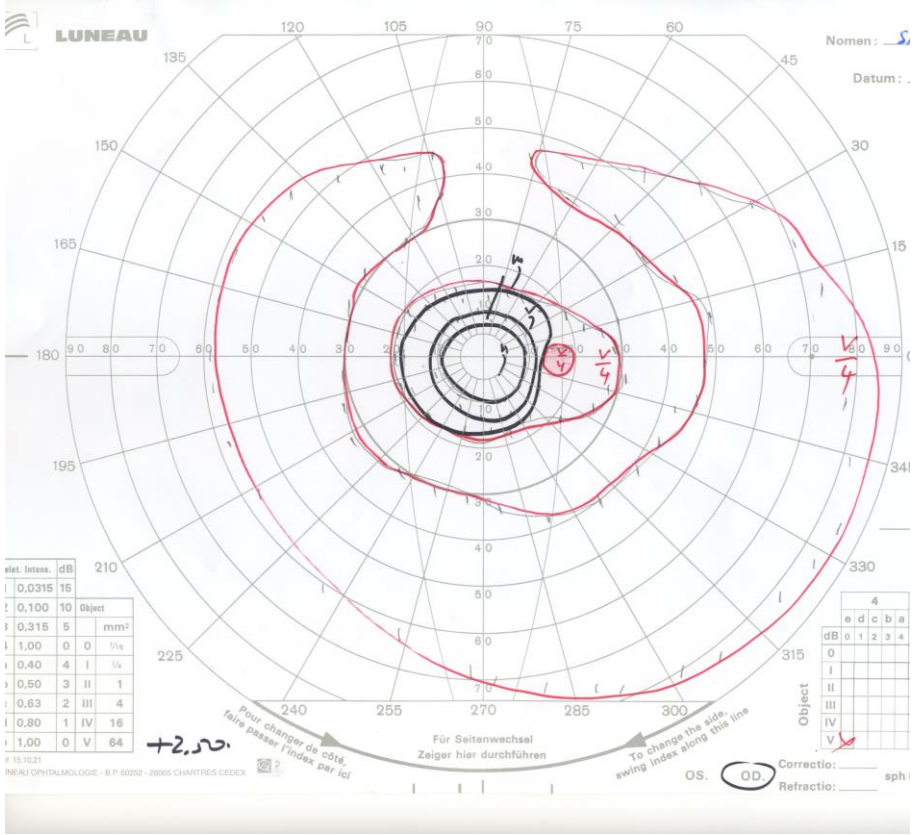
LUNEAU
Nomen:
Datum:
+2,50
Pour changer de côté, faire passer l'index par ici
Für Seitenwechsel Zeiger hier durchführen
To change the side, swing index along this line
OS.
OD.
Correctio:
Refractio:
sph
Object
mm²
LUNEAU OPHTALMOLOGIE - B.P. 60252 - 28005 CHARTRES CEDEX

PHOTOPIQUE

EXAMEN D'ELECTROPHYSIOLOGIE VISUELLE

ERG des cônes: flash blanc — 3mn 7s — Val= 30 — Rej= 0

Bl stimulé

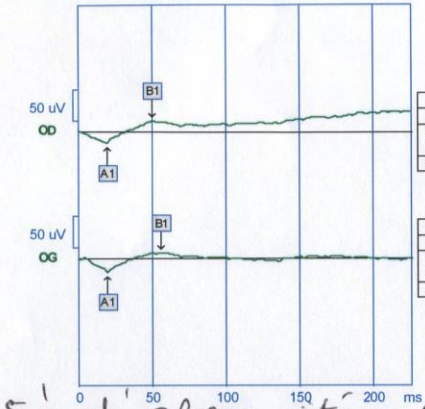

OD			
N°	ms	uV	%
A1	18,6	-17,2	99
B1	49,6	32,4	99
B/A = 1,9			

OG			
N°	ms	uV	%
A1	18,6	-19,4	99
B1	54,9	27,7	99
B/A = 1,4			

ERG des cônes: flash rouge — 5mn 3s — Val= 30 — Rej= 0

Bl stimulé

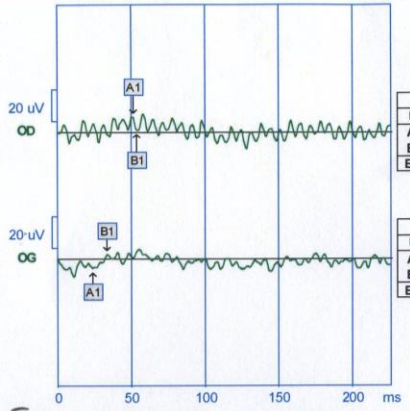

OD			
N°	ms	uV	%
A1	50,5	9,0	99
B1	53,1	-8,0	99
B/A = 0,9			

OG			
N°	ms	uV	%
A1	23,0	-5,5	96
B1	32,8	8,1	96
B/A = 1,5			

ERG des cônes: flicker 30Hz — 5mn 33s — Val= 30 — Rej= 0

Bl stimulé

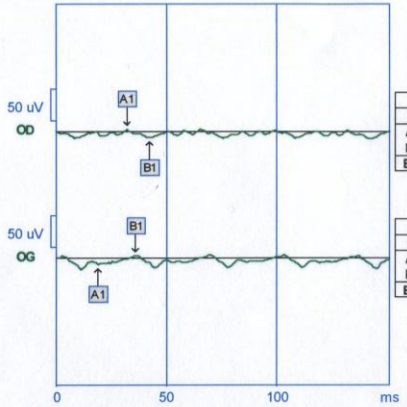

OD			
N°	ms	uV	%
A1	31,3	2,4	99
B1	41,3	-12,4	99
B/A = 5,1			

OG			
N°	ms	uV	%
A1	18,3	-8,9	99
B1	35,4	12,6	99
B/A = 1,4			

S' d'obscurité : SCOTOPIQUE

ERG des bâtonnets (-25dB) — 12mn 45s — Val= 8 — Rej= 0

Bl stimulé



OD			
N°	ms	uV	%
A1	23,9	-6,3	80
B1	33,6	16,3	80
B/A = 2,6			

OG			
N°	ms	uV	%
A1	31,0	4,6	85
B1	42,5	-9,3	85
B/A = 2,0			

ERG mixte: cônes +bâtonnets — 14mn 55s — Val= 8 — Rej= 0

Bl stimulé

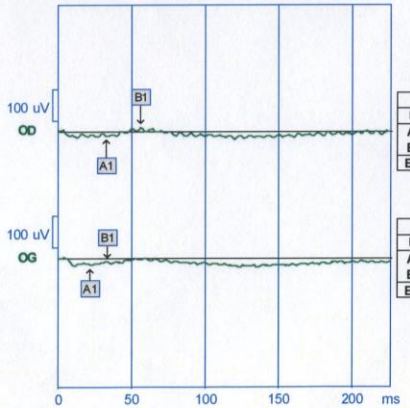

OD			
N°	ms	uV	%
A1	31,9	-13,3	99
B1	54,9	24,9	99
B/A = 1,9			

OG			
N°	ms	uV	%
A1	21,3	-18,0	96
B1	32,8	9,4	96
B/A = 0,5			

ERG potentiels oscillatoires — 16mn 21s — Val= 8 — Rej= 0

Bl stimulé

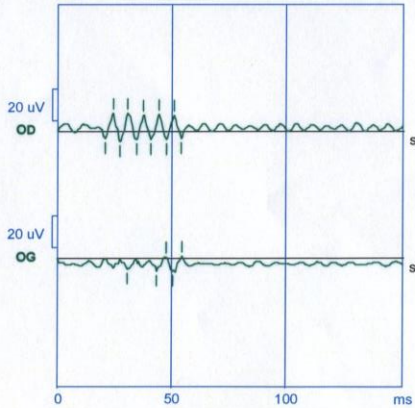

somme OP = 140,0 uV

somme OP = 23,0 uV

Cinq ans plus tard

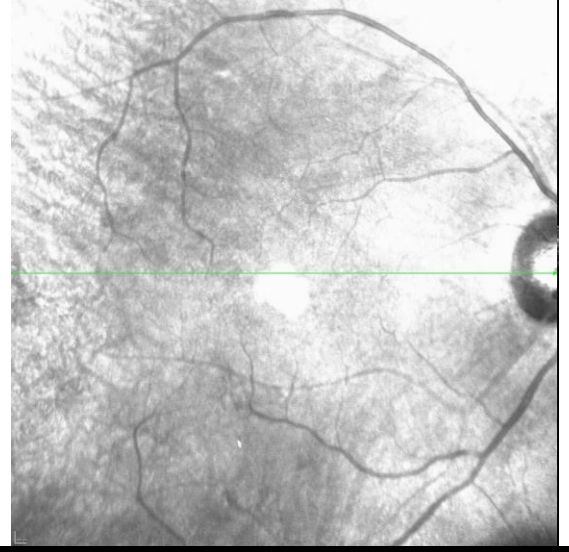

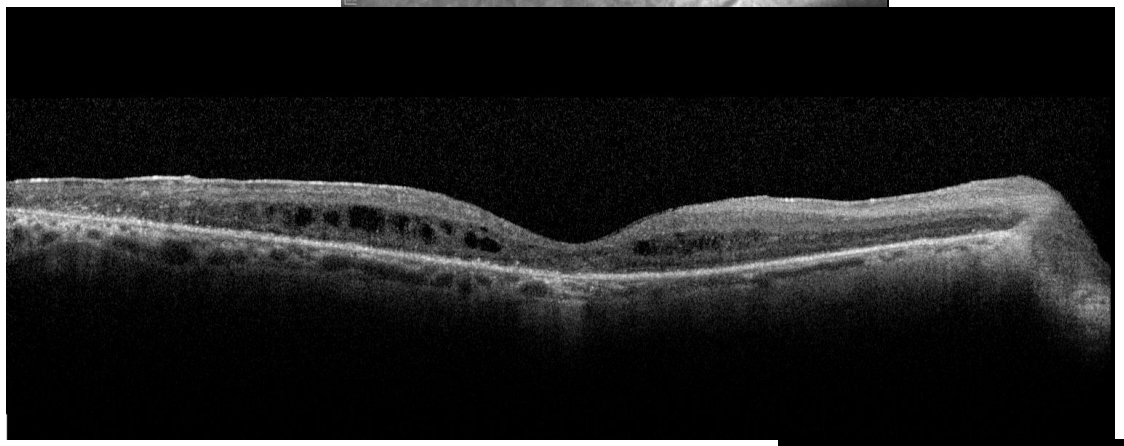

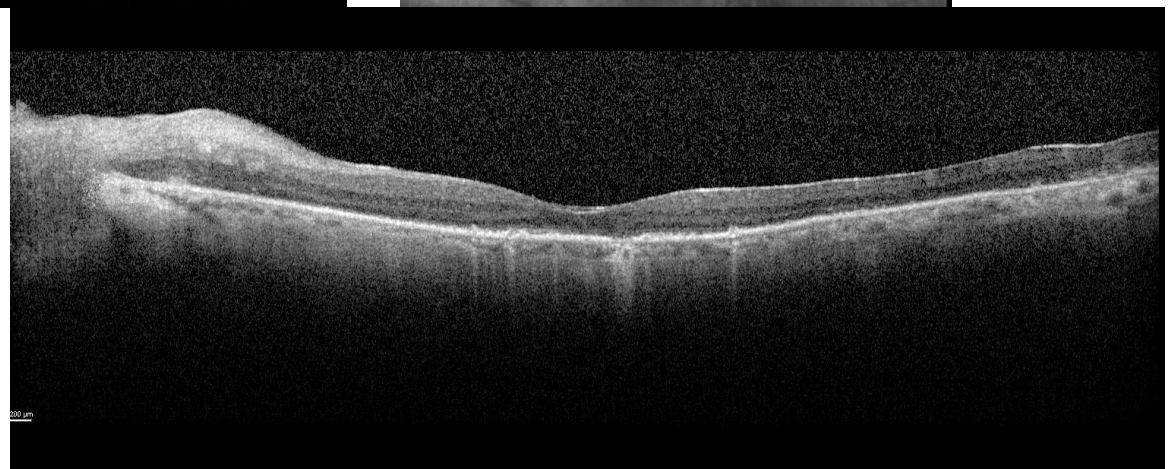

5 ans plus tard

Mr L., 71 ans

- **Antécédents**
  - **Hypertension artérielle**
  - **Dyslipidémie sous statines**
  - **Ictus amnésique**

- **Mode de vie**
  - **Patiente d'origine française**
  - **Père de 2 enfants en bonne santé**
  - **Instituteur à la retraite**

Mr L., 71 ans

- **Examen clinique :**
  - **Absence d’altération de l’état général**
  - **Nombreux naevi et tâches rubis**
  - **Examen cardio-pulmonaire et abdominal sans particularité**

Mr L., 71 ans

- **Bilan biologique :**
  - **lymphopénie à 1130/mm^3**
  - **Phénotypage lymphocytaire normal**
  - **Créatininémie 85 µmol/l, urée 8,1 mmol/l**
  - **PSA à 2,82 µg/l, avec un ratio PSA libre/PSA total à 14,1 %**
  - **Electrophorèse des protéines plasmatiques : albumine 40 g/l, gammaglobulines 14,3 g/l**
  - **TDM thoraco-abdo-pelvien normal**
  - **TEP scan normal**

Nouveau bilan étiologique

- **Augmentation du taux de PSA à 10 µg/l avec un ratio PSA libre/PSA total à 7 %**

- **Toucher rectal : prostate augmentée de volume, nodules durs**

IRM pelvienne

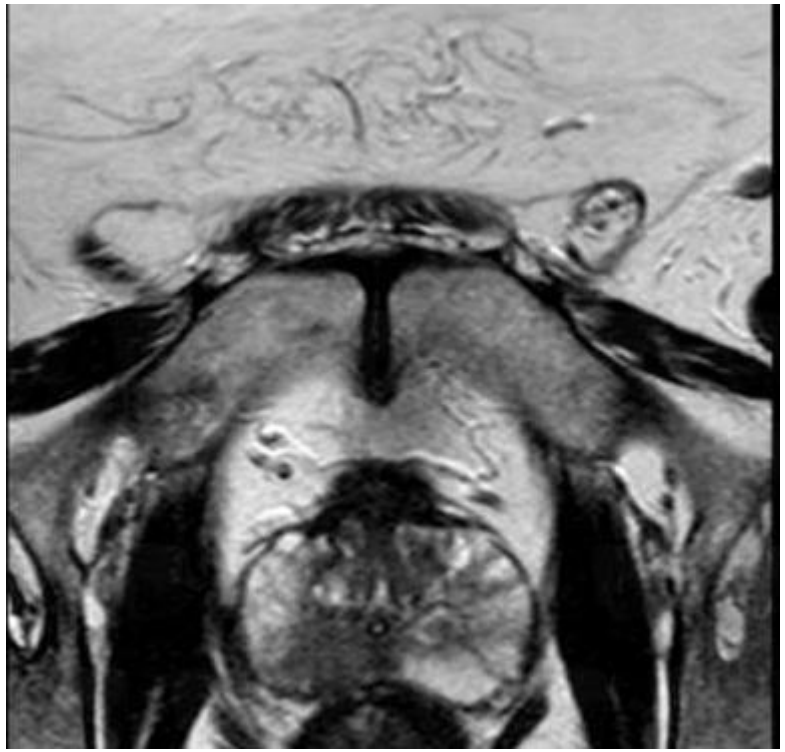

Biopsie de prostate
Adénocarcinome de prostate

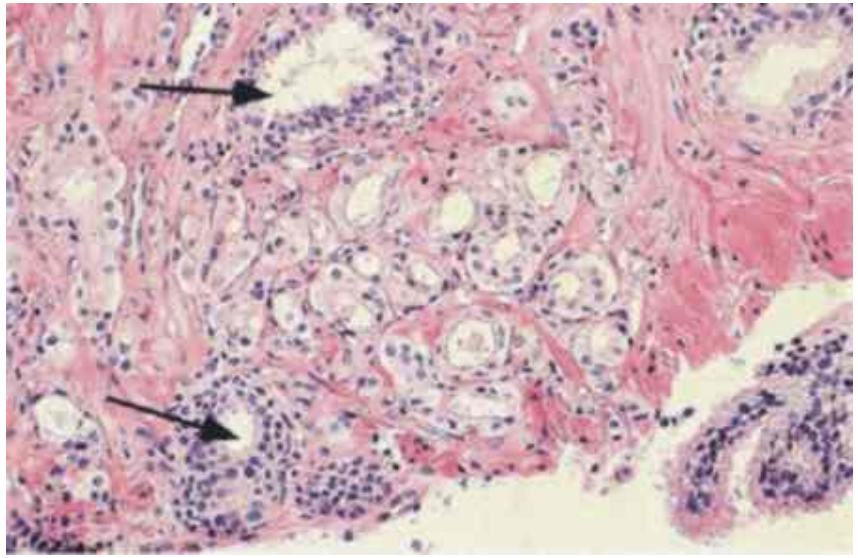

Mr L., 71 ans

- **Diagnostic de rétinopathie associée au cancer, satellite d'un cancer de la prostate**
- **Maladie néoplasique confirmée**
- **Traitement par prostatectomie et hormonothérapie**

Key messages

- **Rétinopathie associée au cancer**

- **Importance de rechercher les cancers pulmonaires, gynécologiques chez la femme et l'homme, et coliques**

- **Importance de renouveler le bilan en cas de modification clinique <u>et en systématique</u>**

Cas n°6

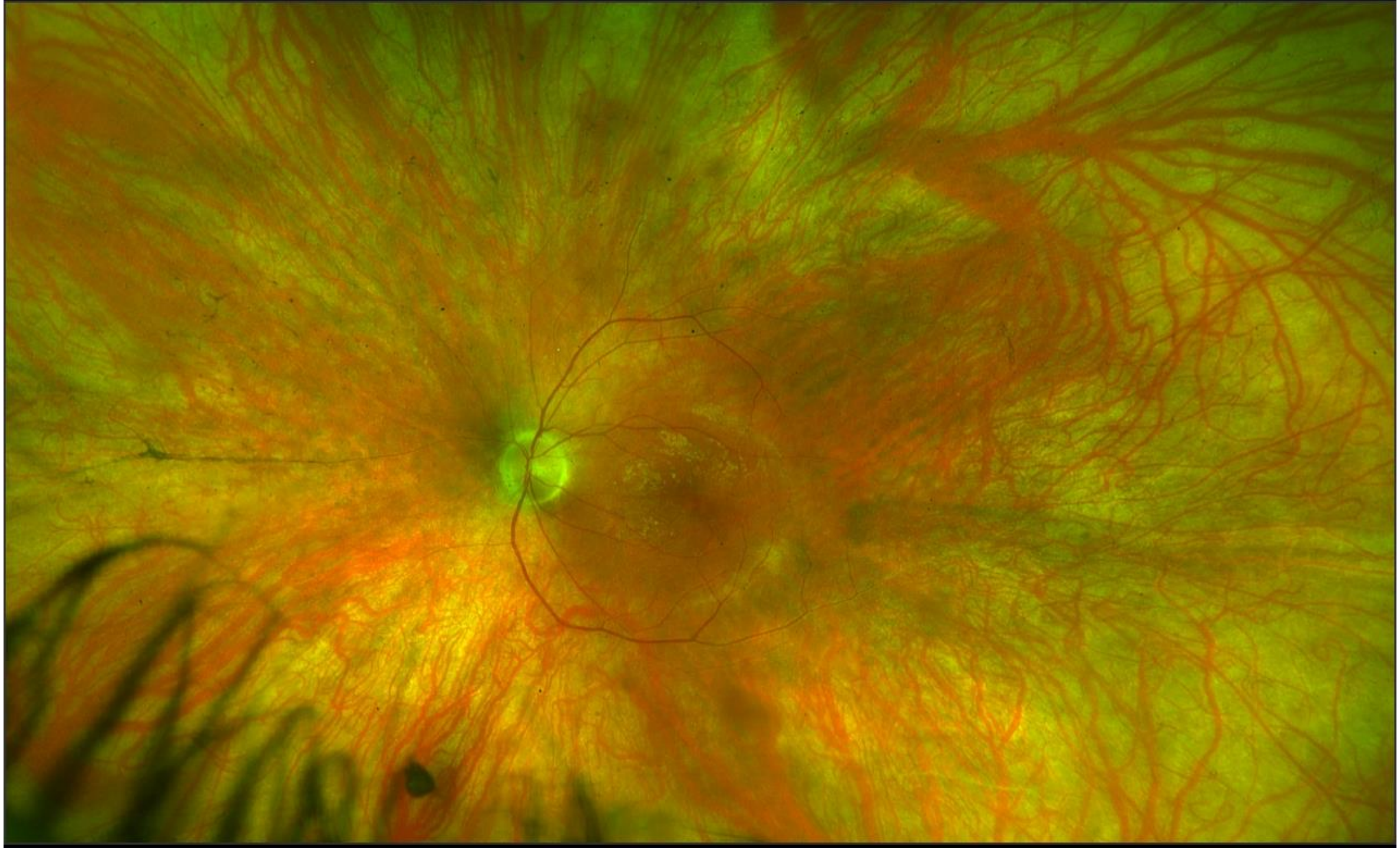

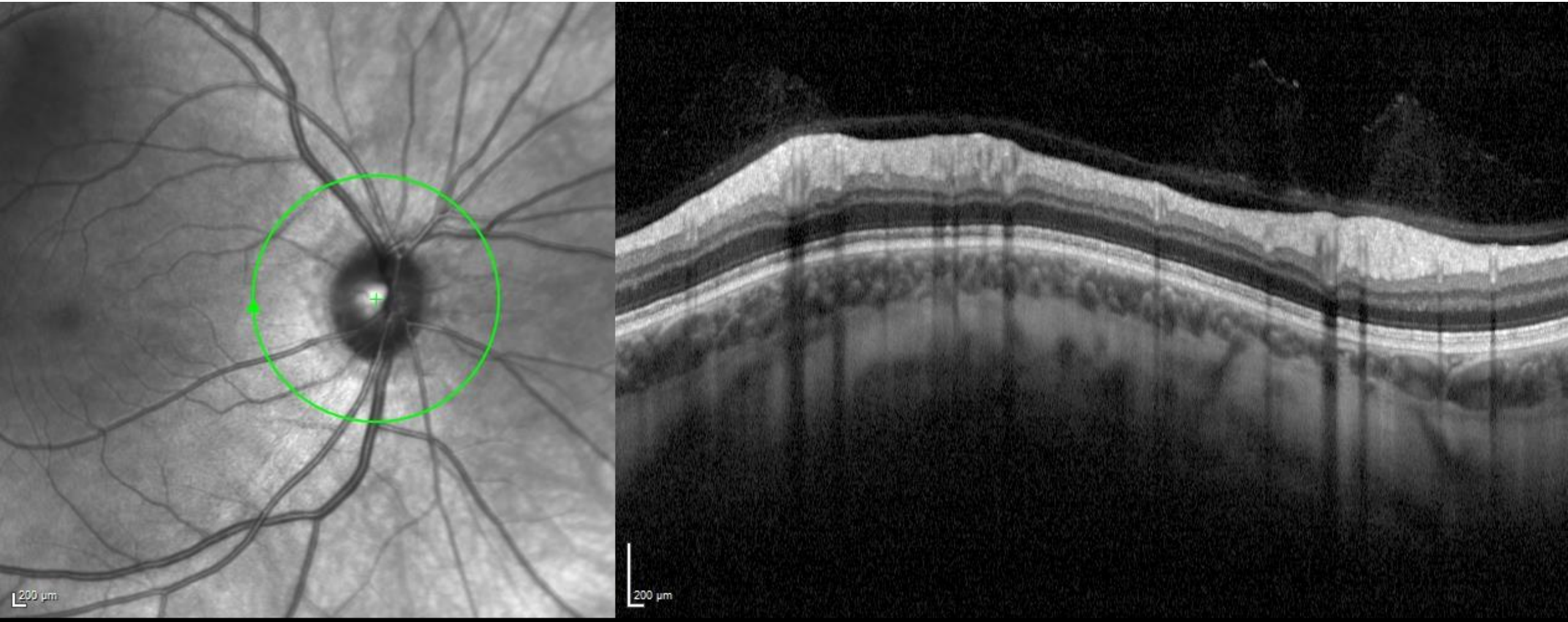

28/12/2018, OD

IR&OCT 30° ART [HS] ART(100) Q: 25

HEIDELBERG ENGINEERING

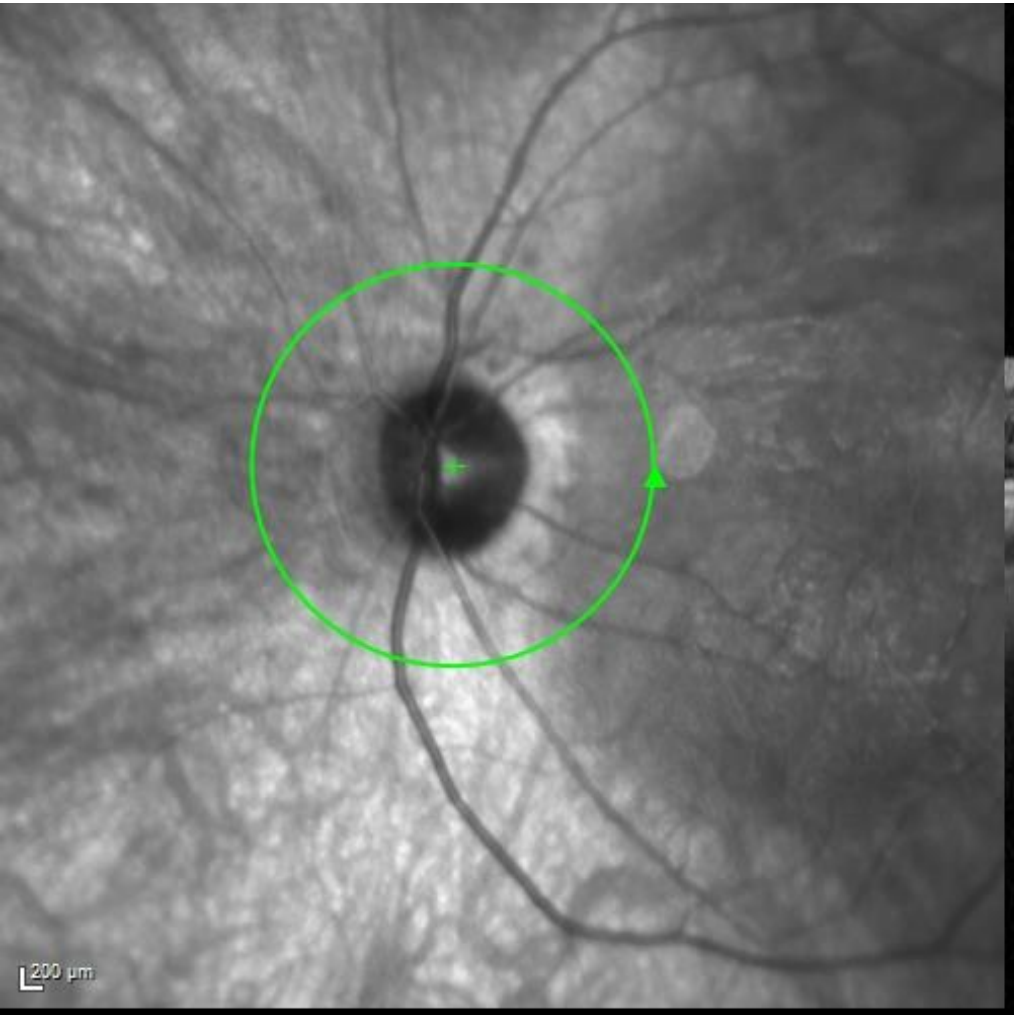

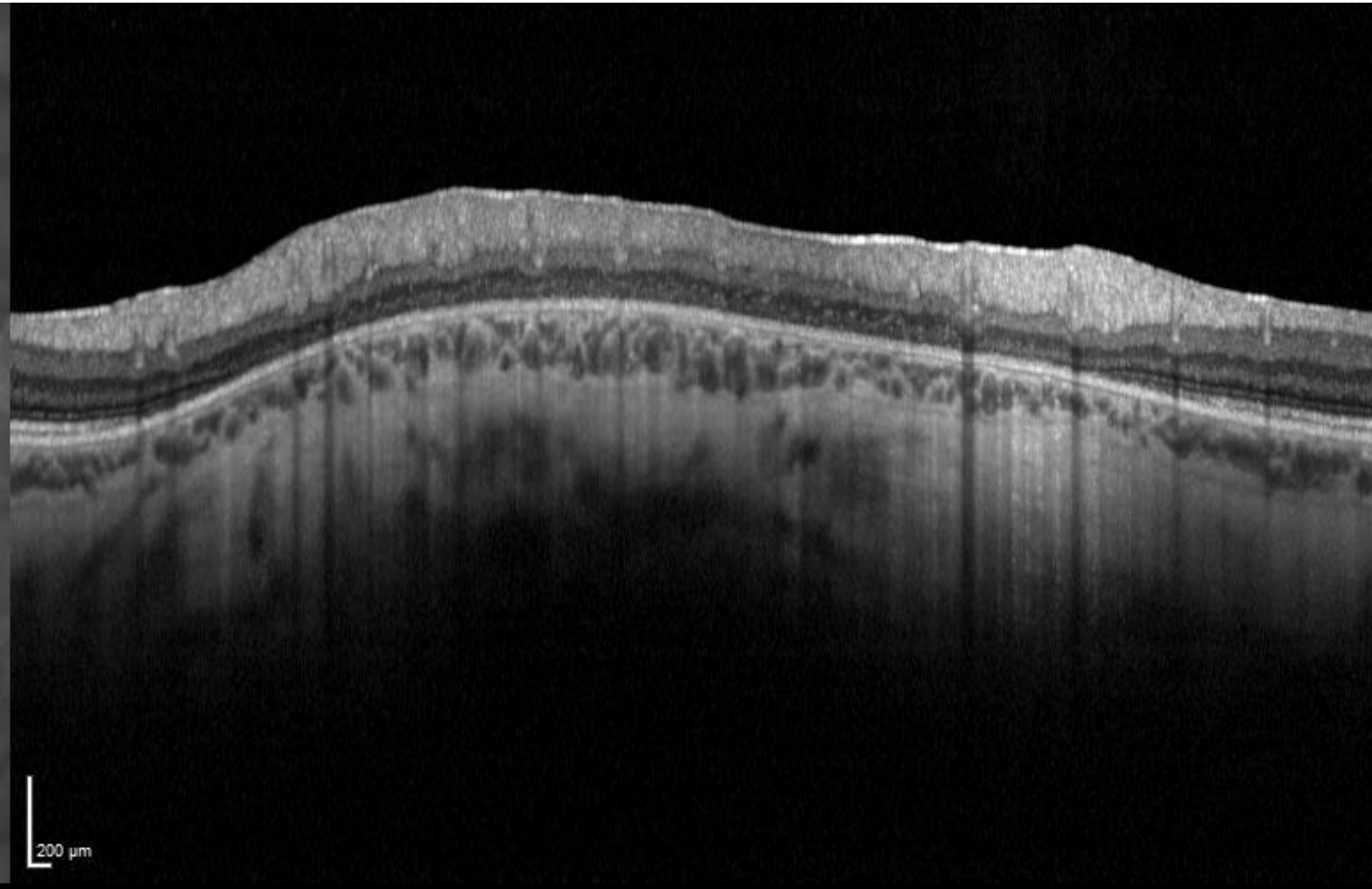

28/12/2018, OS

IR&OCT 30° ART [HS] ART(100) Q: 33

HEIDELBERG ENGINEERING

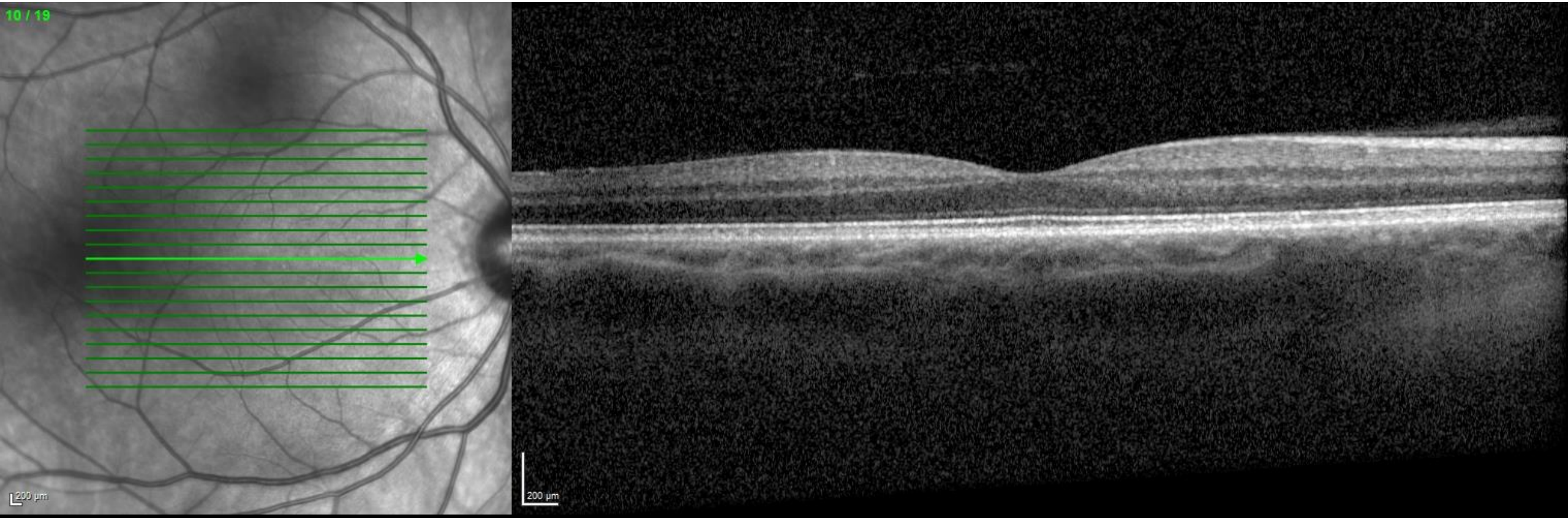

28/12/2018, OD

IR&OCT 30° ART [HR] ART(8) Q: 27

HEIDELBERG ENGINEERING

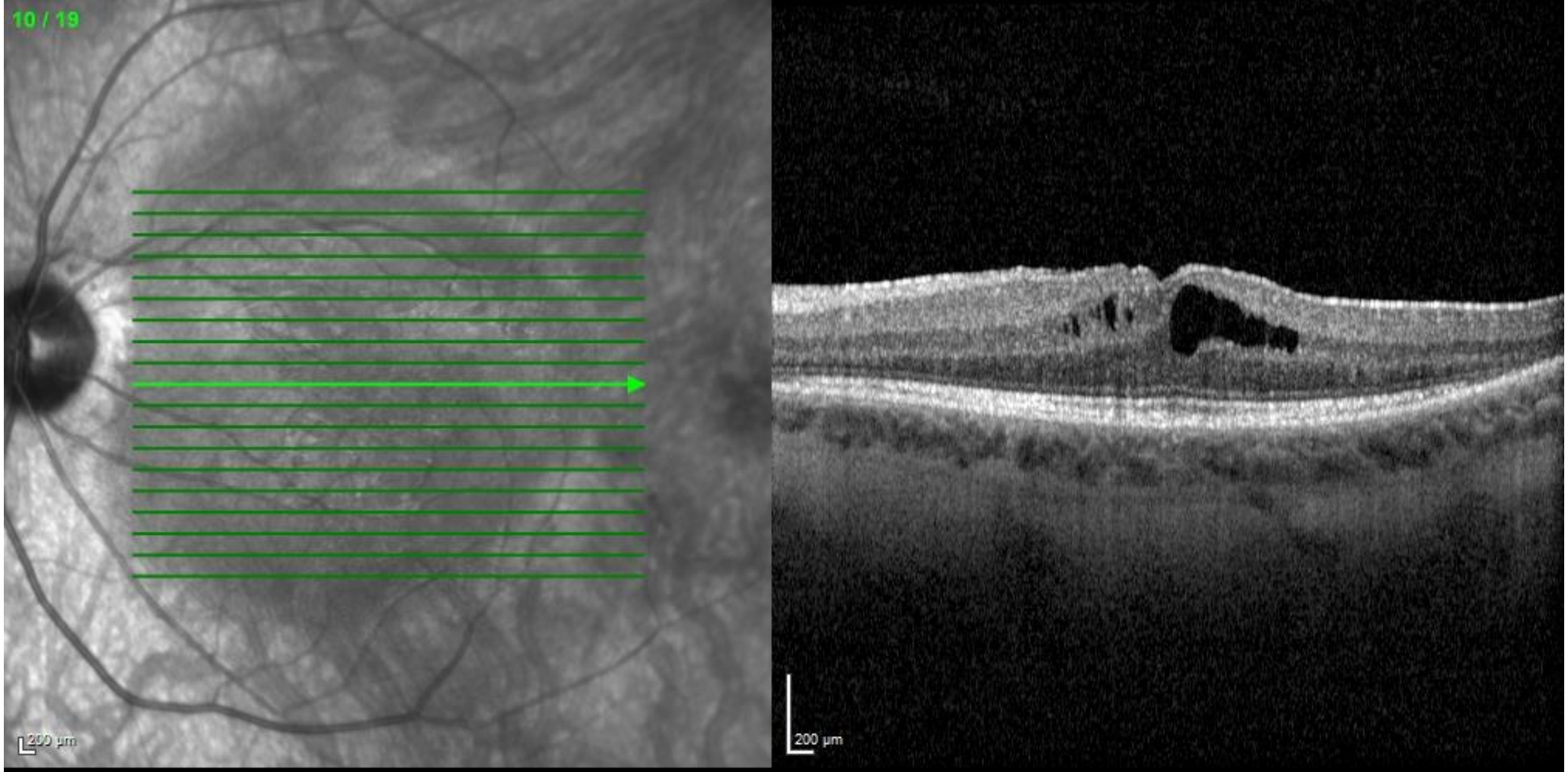

28/12/2018, OS

IR&OCT 30° ART [HS] ART(11) Q: 32

HEIDELBERG ENGINEERING

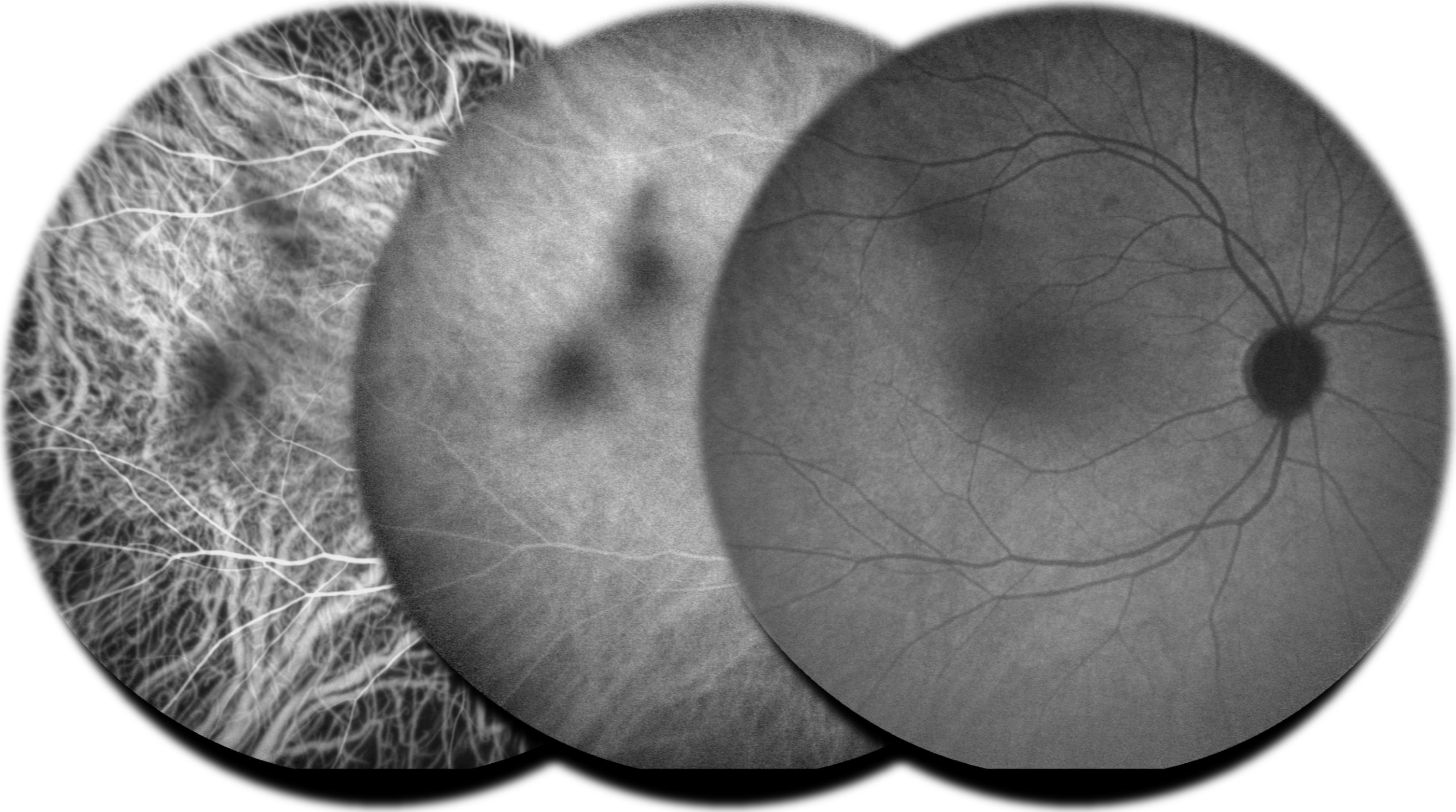

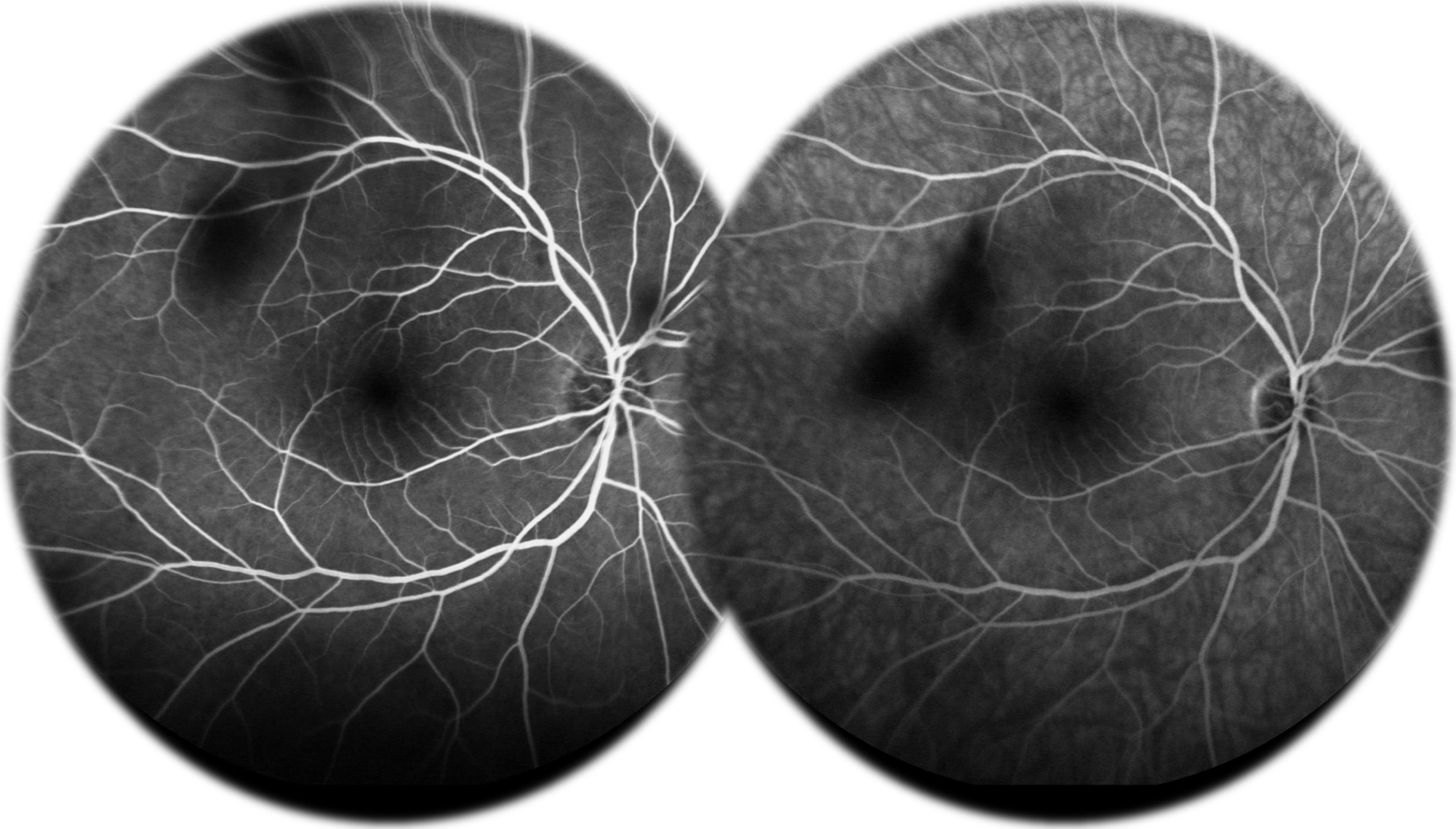

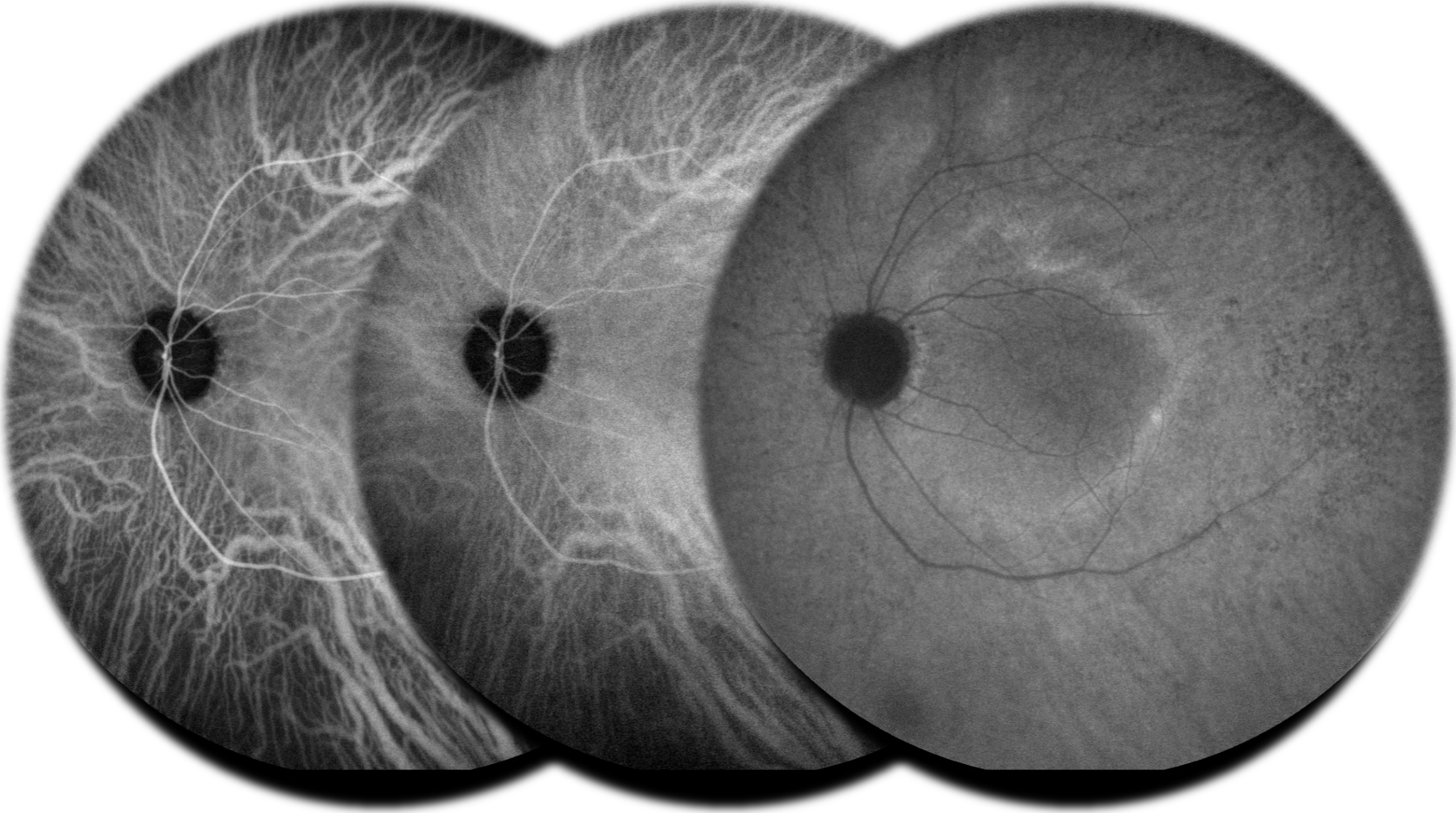

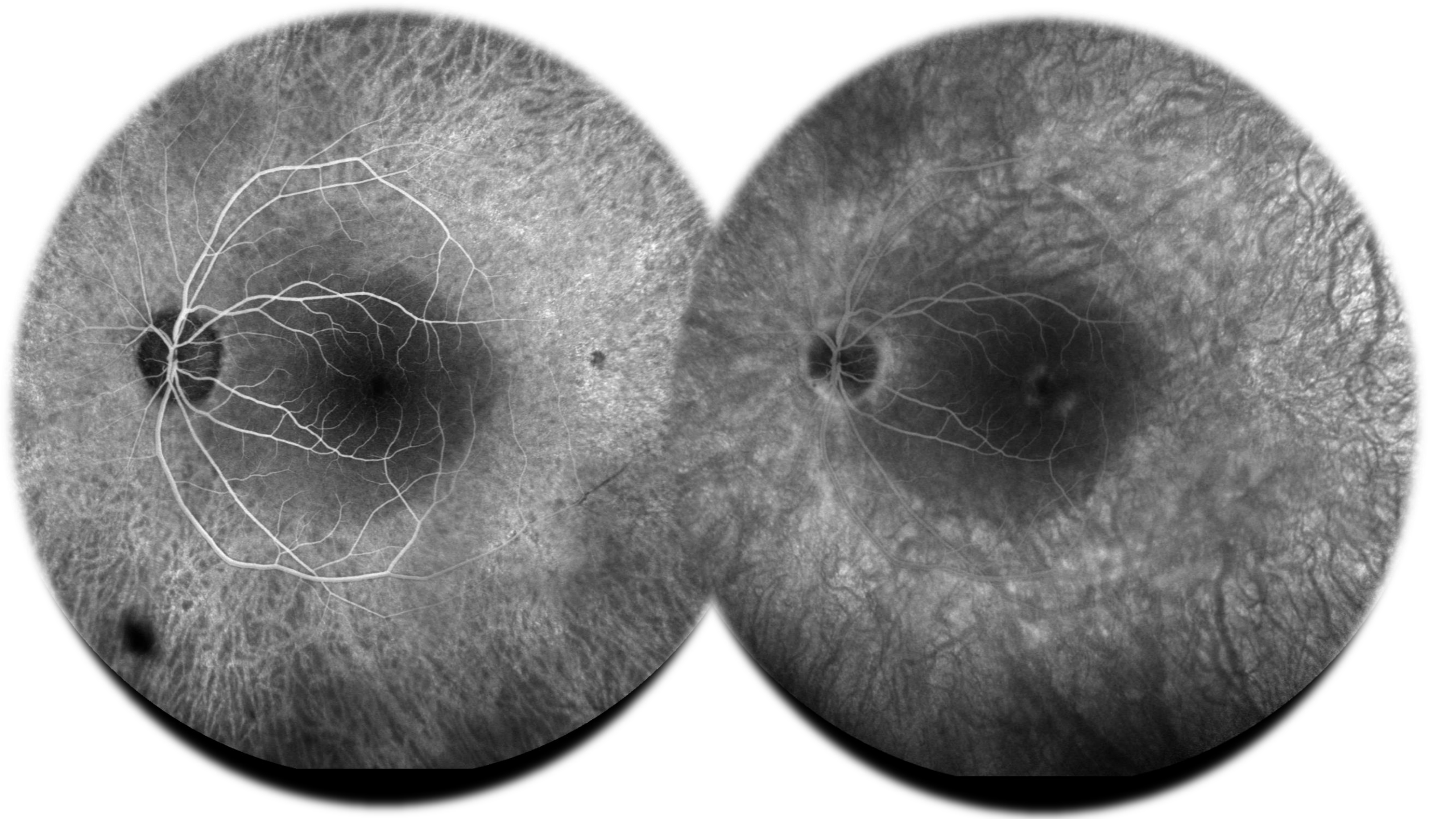

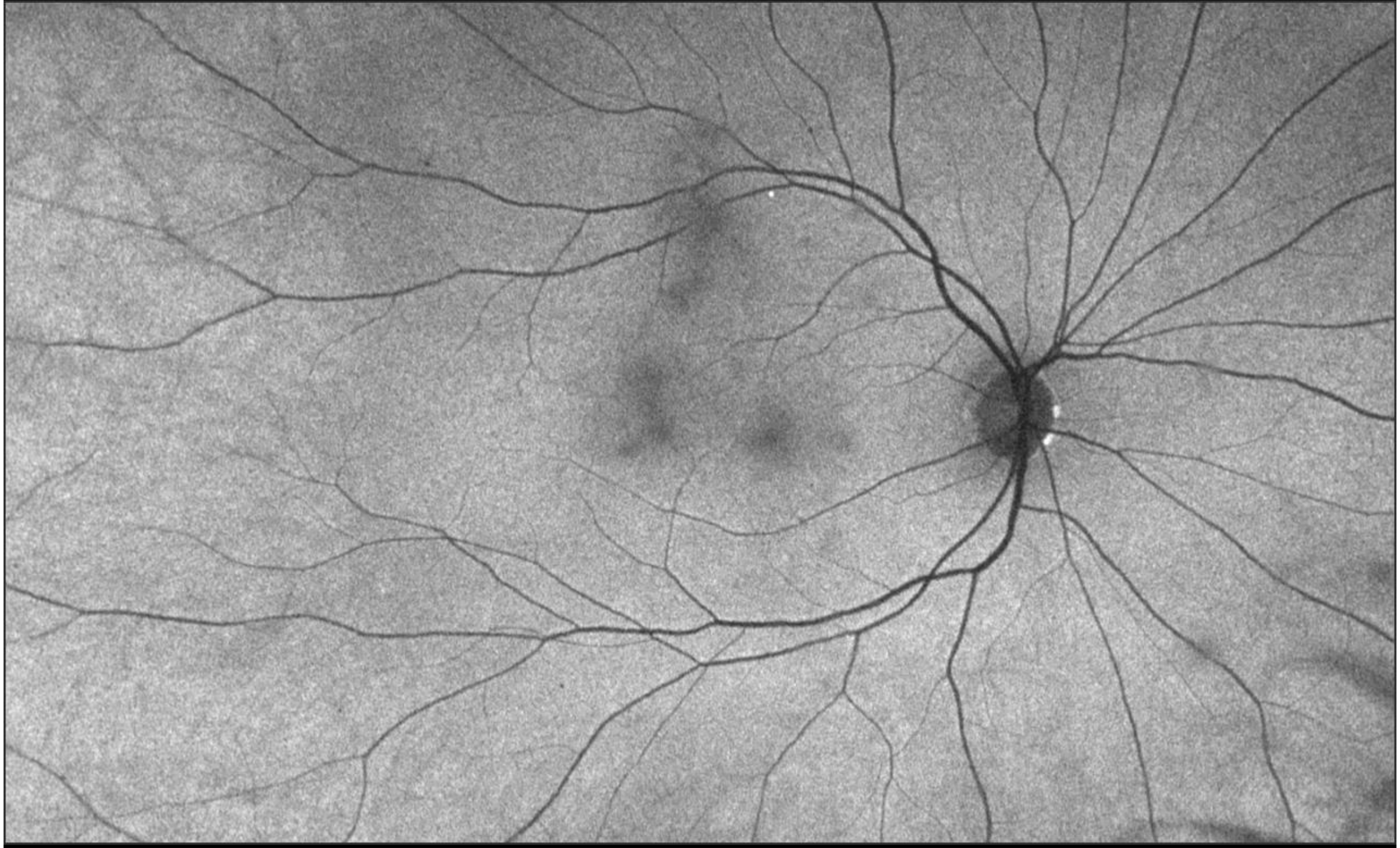

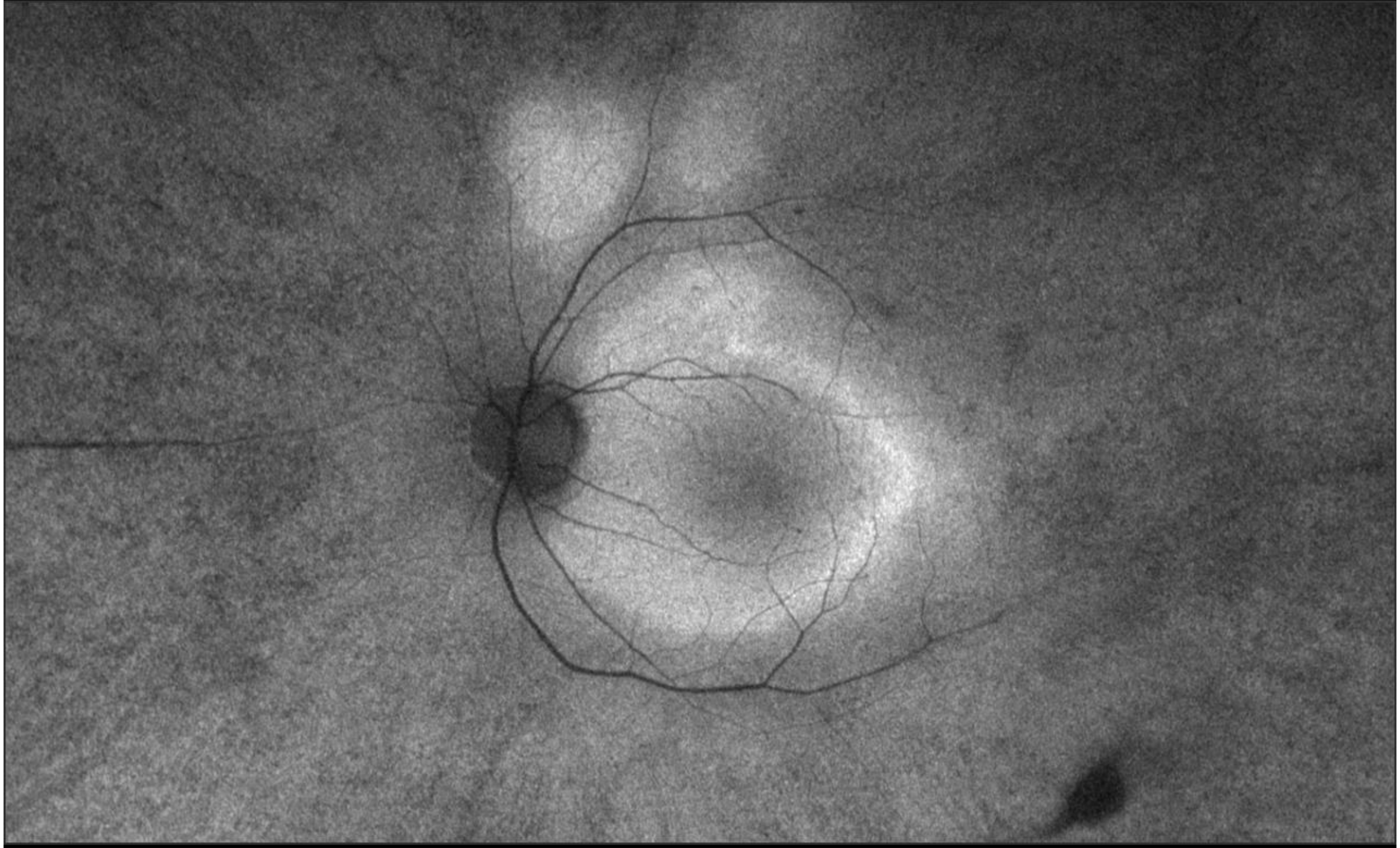

LUNEAU

Nomen: [redacted]

Datum: 23/11/2018

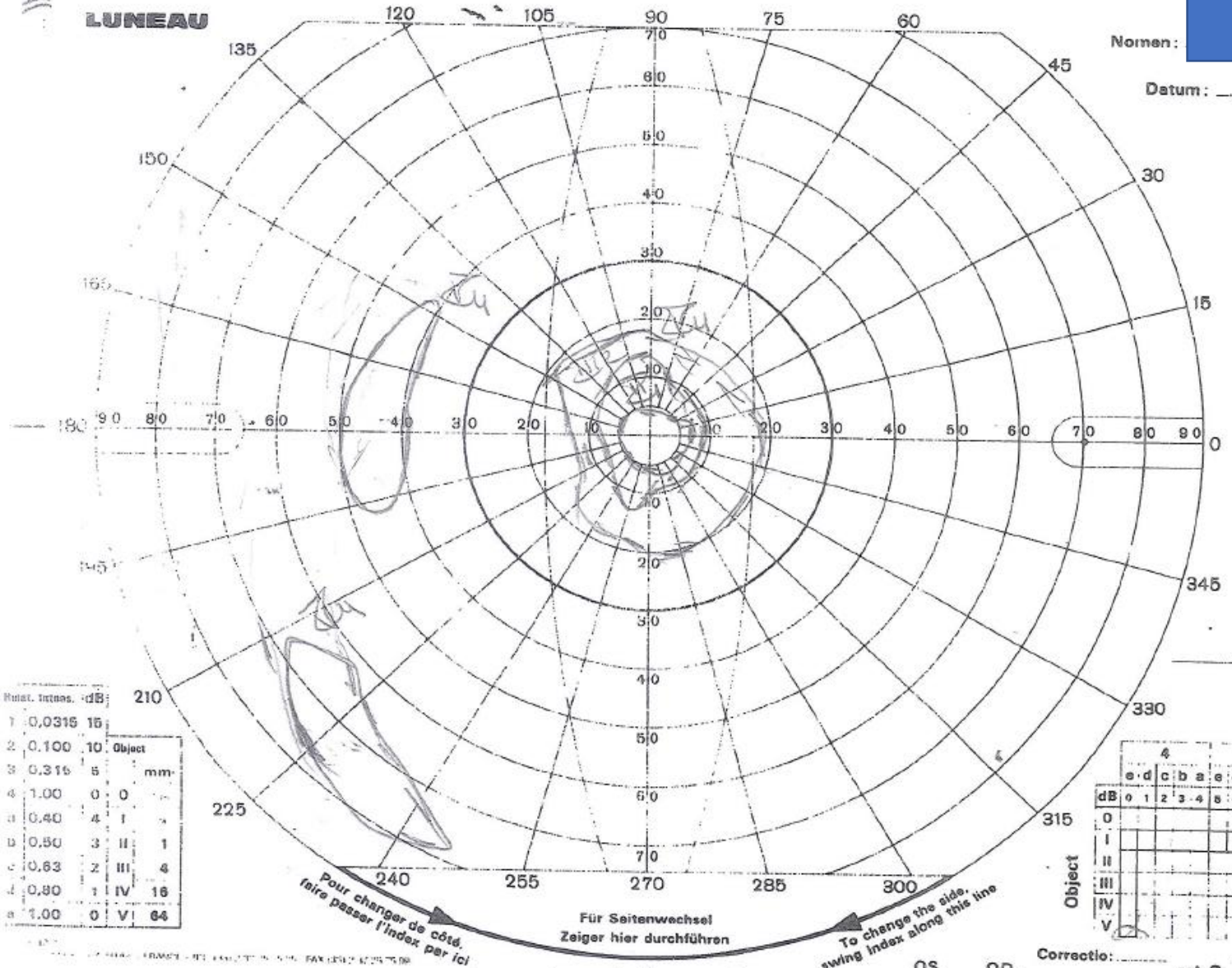

OG

Avec ABLC

Relat. Intens.		dB
1	0,0315	15
2	0.100	10
3	0.315	5
4	1.00	0
a	0.40	4
b	0.50	3
c	0.63	2
d	0.80	1
e	1.00	0

Object	mm
0	
I	
II	1
III	4
IV	16
V	64

mm Diameter pupillae

Relat. Intens.

	4				3				2				1				
	e	d	c	b	a	e	d	c	b	a	e	d	c	b	a	e	d	c	b	a
dB	0	1	2	3	4	5	6	7	8	9	10	11	12	13	14	15	16	17	18	19
Object 0																				
I																				
II																				
III																				
IV																				
V																				

Correctio: ..... sph ○ ..... cyl ..... ° Visus

OS. OD.

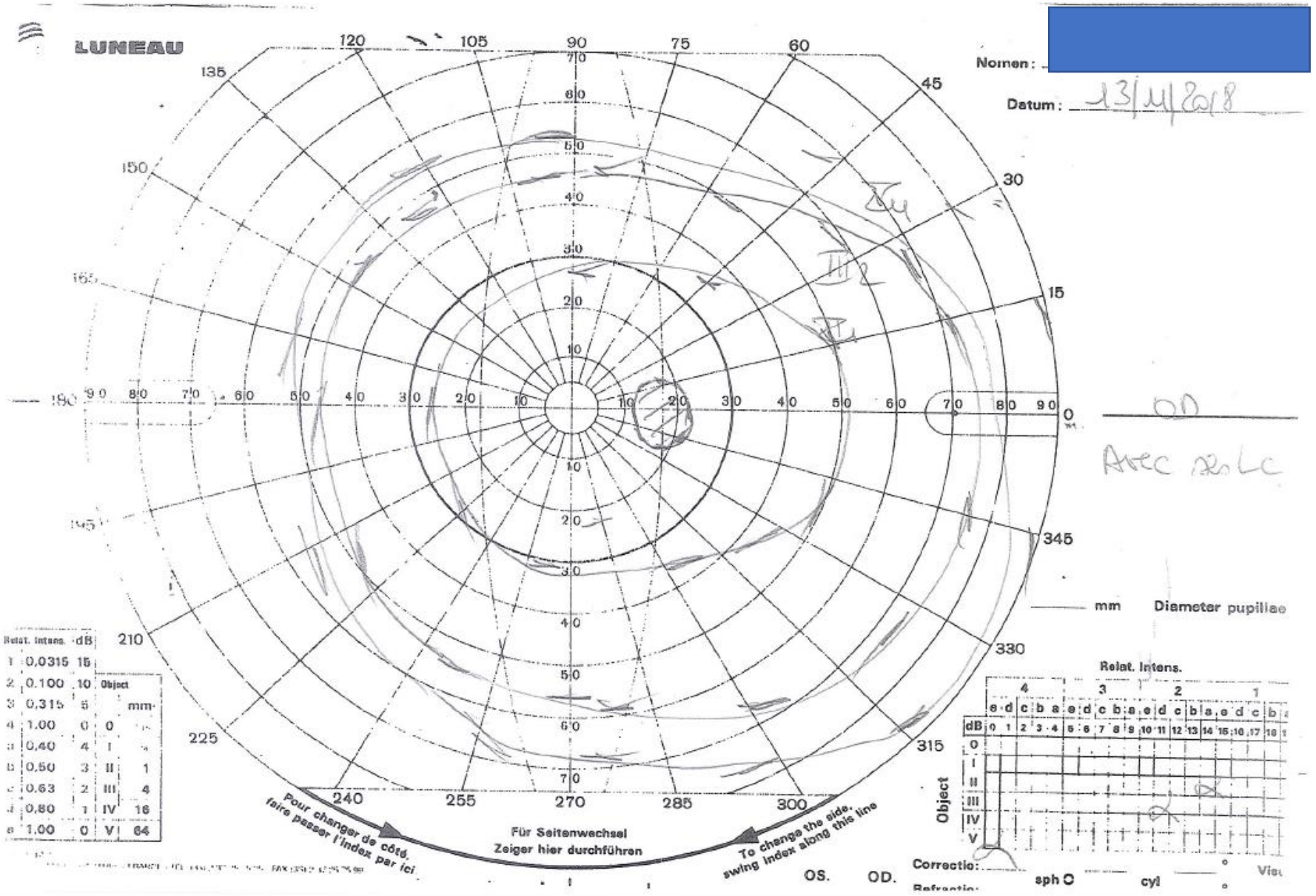
LUNEAU
Nomen: [redacted]
Datum: 13/11/2018
OD
Avec ses LC
mm Diameter pupillae
Relat. Intens. dB
1 0,0315 15
2 0,100 10
3 0,315 5
4 1,00 0
a 0,40 4
b 0,50 3
c 0,63 2
d 0,80 1
e 1,00 0
Object mm
0
I 1
II 4
III 16
IV 64
V
Relat. Intens.
Object
Für Seitenwechsel
Zeiger hier durchführen
Pour changer de côté, faire passer l'index par ici
To change the side, swing index along this line
OS.
OD.
Correction:
sph
cyl

EXAMEN D'ELECTROPHYSIOLOGIE VISUELLE

ERG des bâtonnets (-25dB) 16mn 55s Val= 8 Rej= 1

Bl stimulé

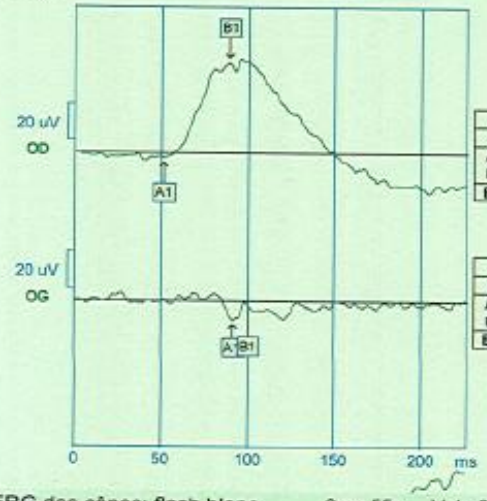

OD			
N°	ms	uV	%
A1	50,5	-2,5	99
B1	88,5	48,5	99
B/A = 19,1			

OG			
N°	ms	uV	%
A1	90,3	-9,8	97
B1	99,2	8,2	
B/A = 0,8			

ERG mixte: (-15dB) 18mn 5s Val= 8 Rej= 1

Bl stimulé

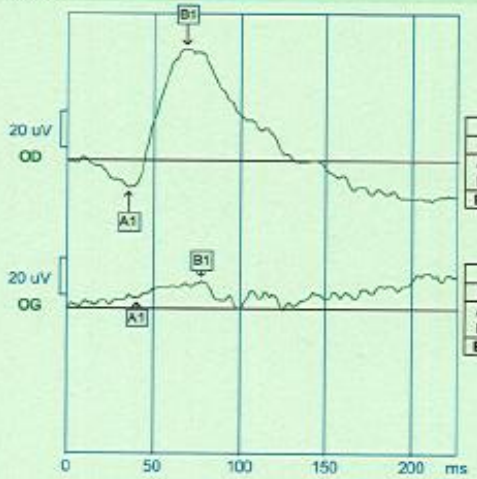

OD			
N°	ms	uV	%
A1	34,5	-13,7	99
B1	68,2	70,2	99
B/A = 5,1			

OG			
N°	ms	uV	%
A1	39,8	5,0	68
B1	77,0	8,6	72
B/A = 1,7			

ERG potentiels oscillatoires 19mn 32s Val= 8 Rej= 0

Bl stimulé

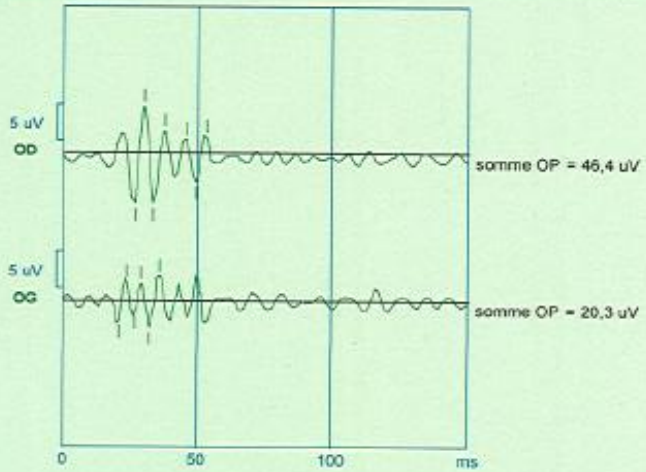

ERG des cônes: flash blanc 3mn 55s Val= 30 Rej= 5

Bl stimulé

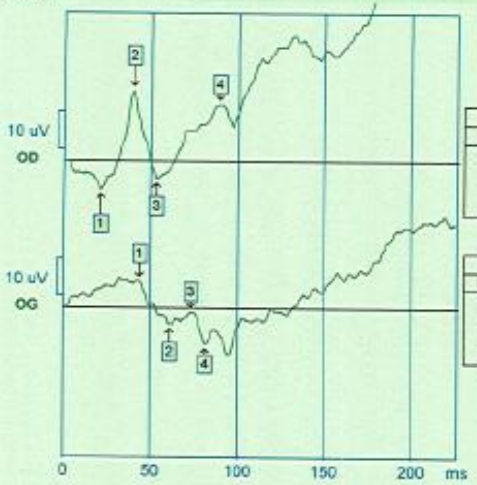

OD			
N°	ms	uV	%
1	20,4	-7,1	99
2	39,0	17,7	99
3	52,2	-4,2	97
4	83,5	14,4	72

OG			
N°	ms	uV	%
1	42,5	6,9	97
2	60,2	-4,1	97
3	72,6	-0,8	58
4	80,6	-8,9	58

ERG des cônes: flicker 30Hz 4mn 36s Val= 30 Rej= 0

Bl stimulé

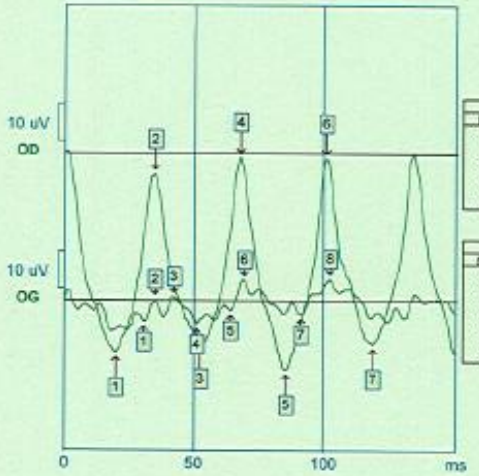

OD			
N°	ms	uV	%
1	19,5	-50,2	99
2	34,2	-5,4	99
3	51,9	-46,0	99
4	67,3	-1,1	99
5	84,4	-54,7	99
6	100	-1,3	99
7	118	-48,1	99

OG			
N°	ms	uV	%
1	30,1	-5,4	80
2	34,2	0,2	80
3	41,3	0,9	80
4	50,2	-5,8	80
5	63,2	-2,3	92
6	68,5	5,4	92
7	90,3	-3,5	93
8	102	5,7	93

ASSISTANCE PUBLIQUE HÔPITAUX DE PARIS

Groupe Hospitalier Cochin - Saint Vincent de Paul

Service d'Ophtalmologie

Pr Antoine BRÉZIN

Hôpital Cochin - 27 rue du Faubourg Saint Jacques - 75679 PARIS Cedex 14

Moniteur Ophtalmologique

WIN8000F

Metrovision

4 rue des platanes

59840 Pérenchies

France

tel 33 (0)3 20 17 19 50

http://www.metrovision.fr

METROVISION

Héméralopie œil gauche ancienne

Rétinite pigmentaire unilatérale

Anomalies pouvant également survenir dans des formes de Birdshot atrophiques…