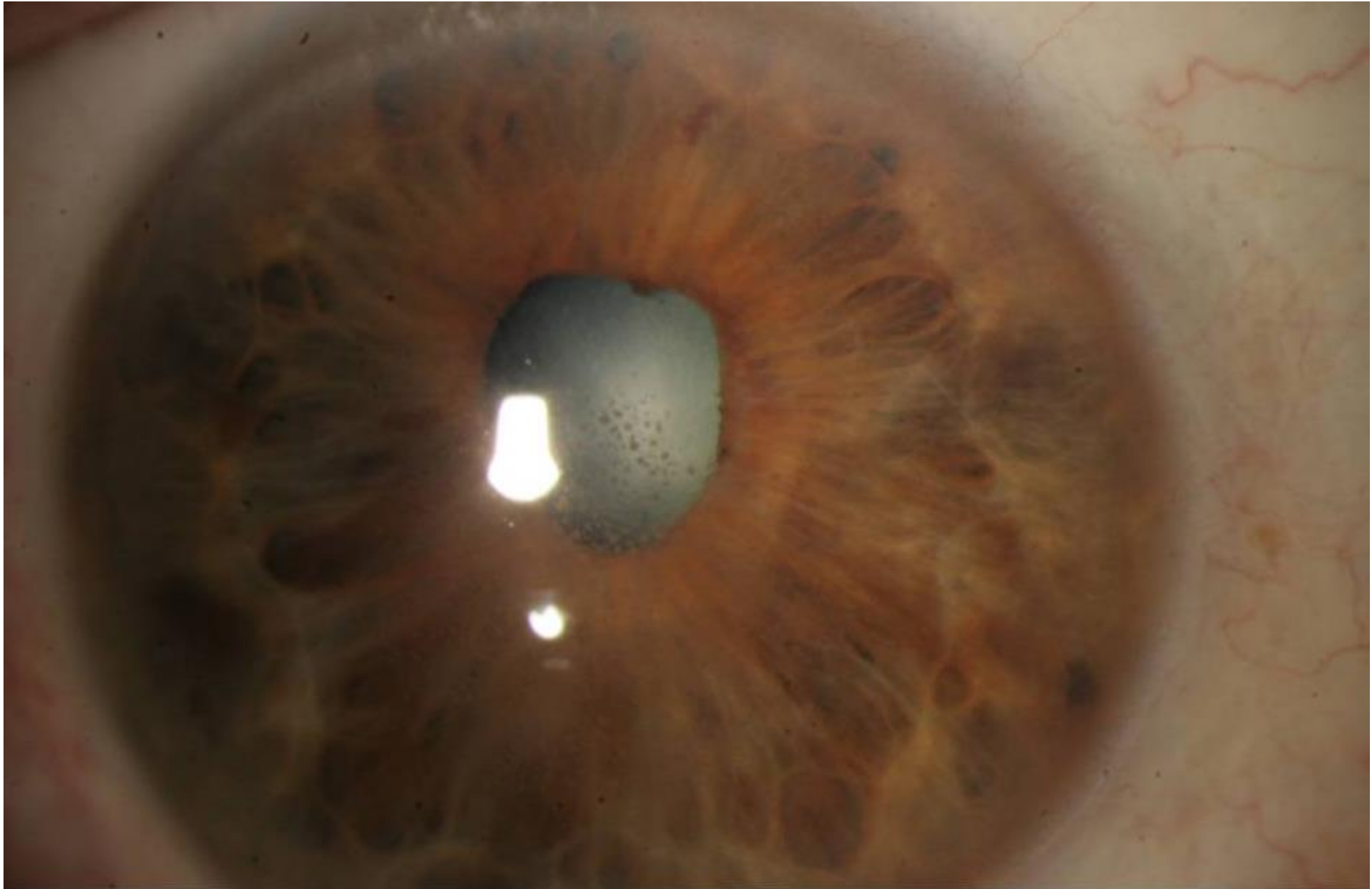
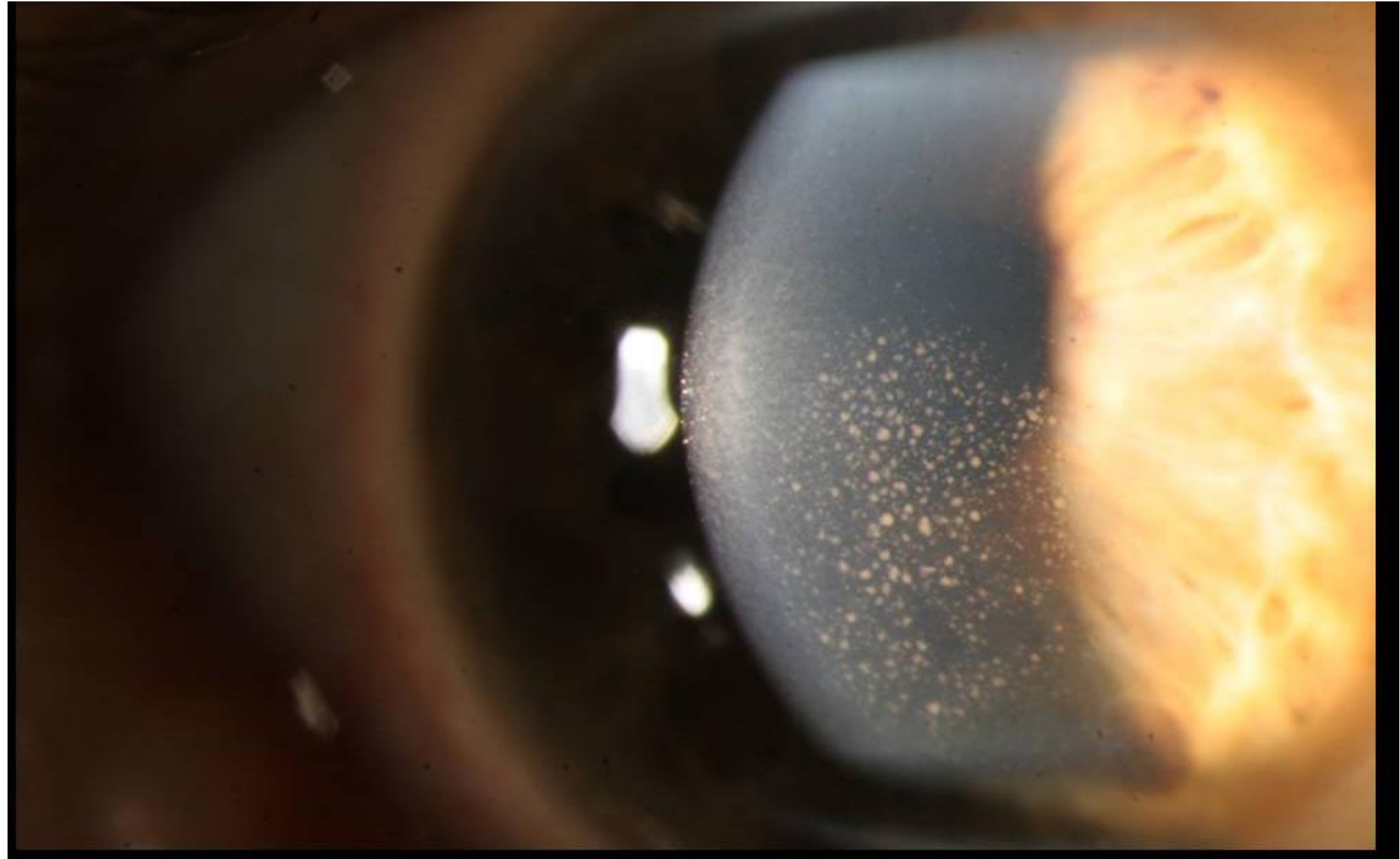
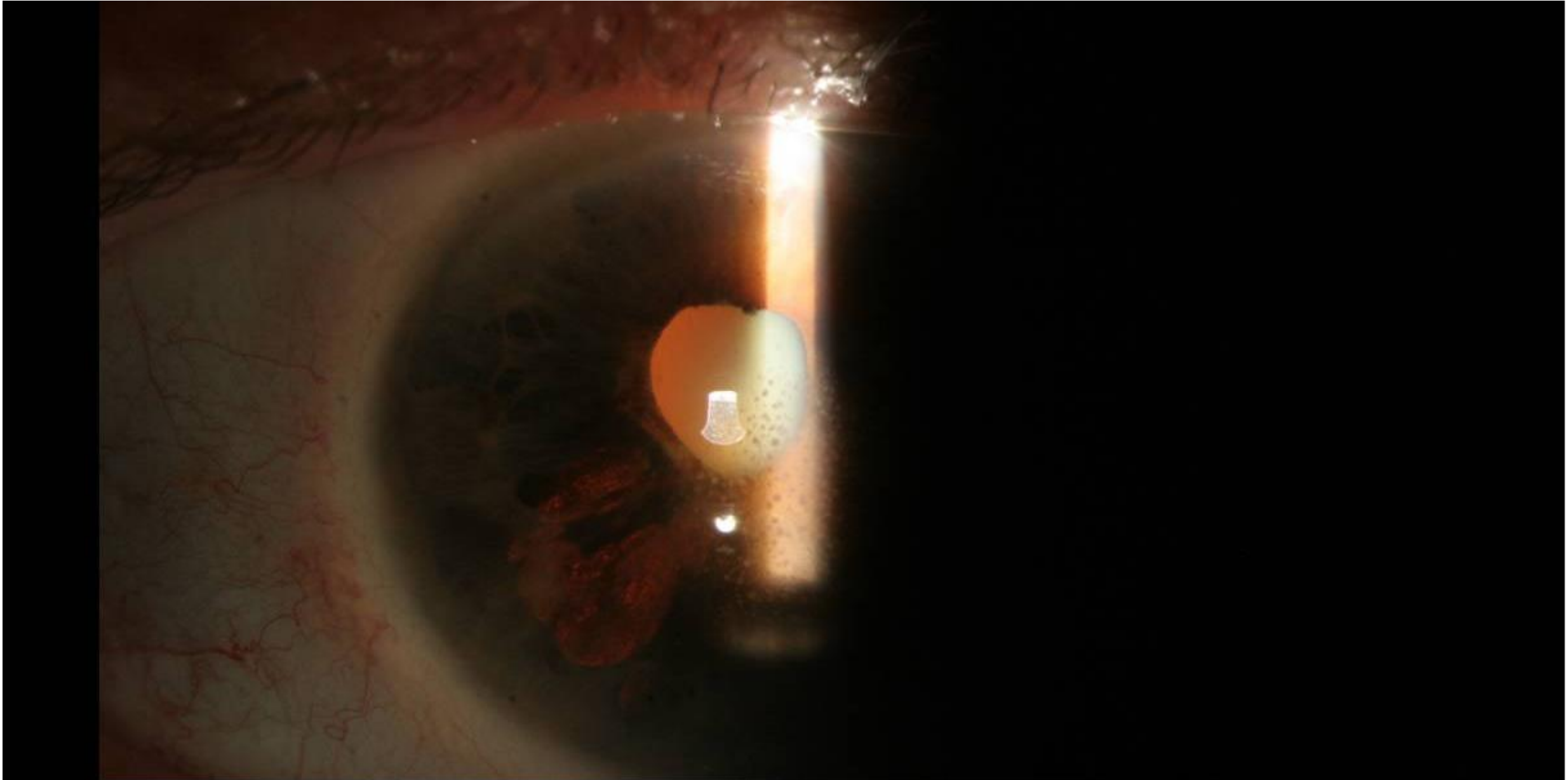
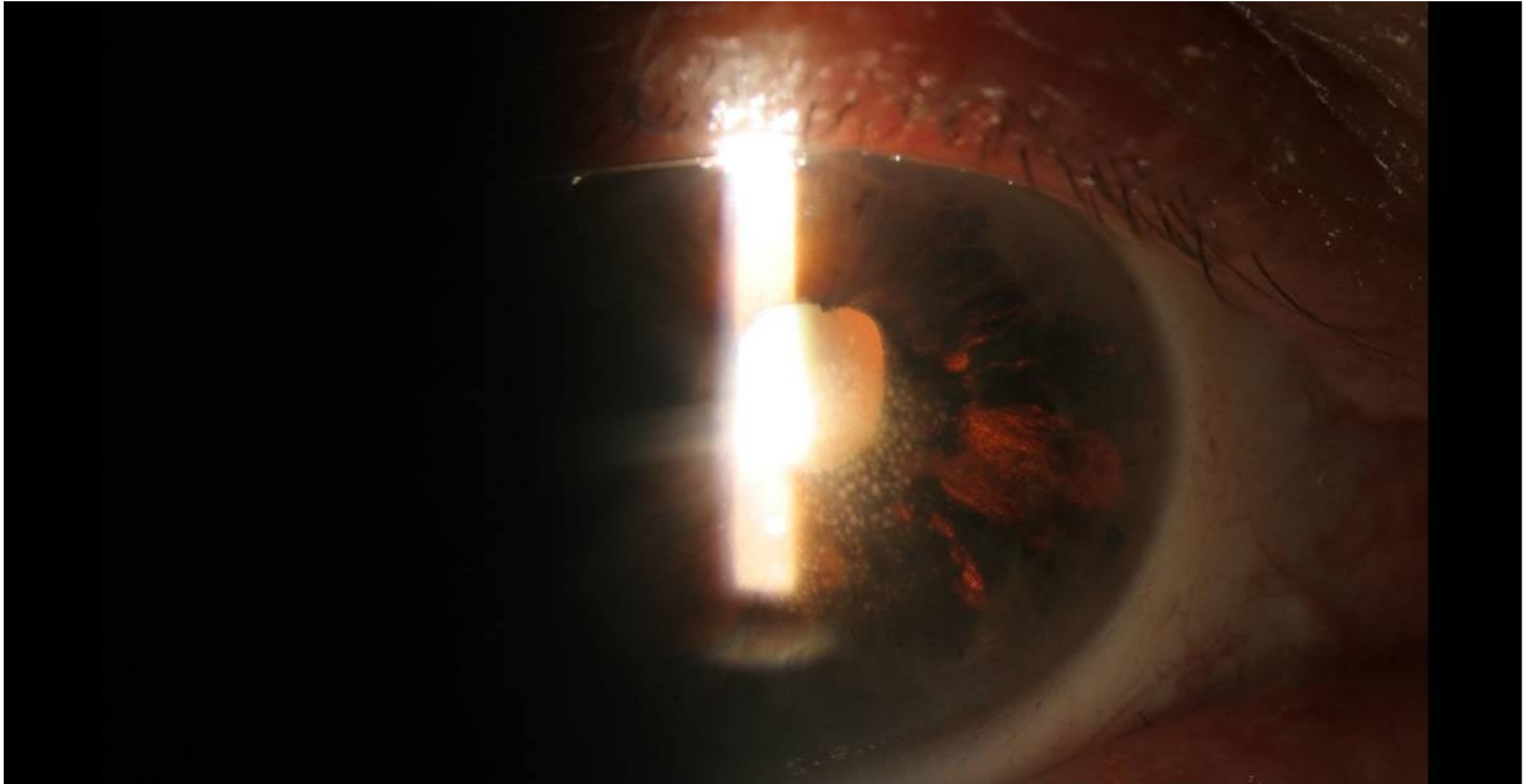


Quelques cas de cornée









Uvéite antérieure aigue granulomateuse herpétique

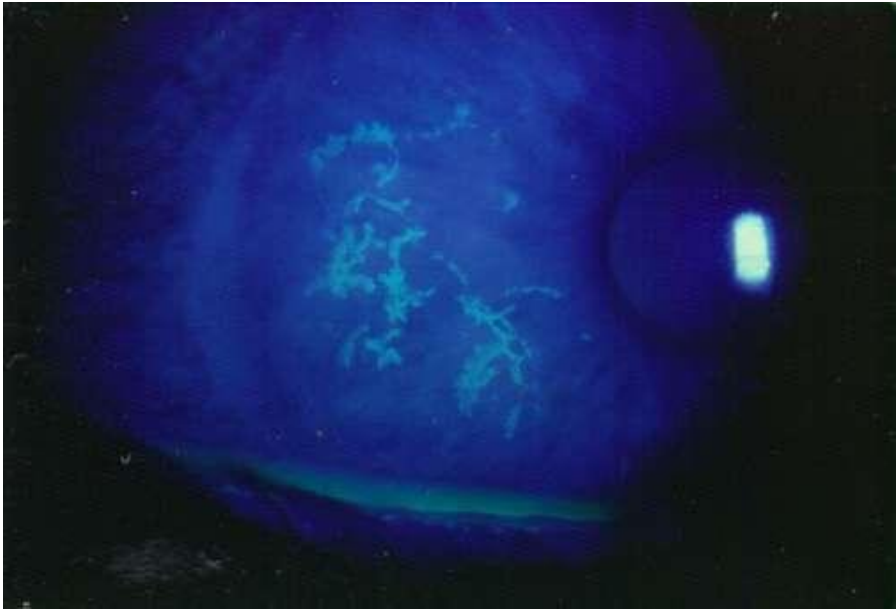
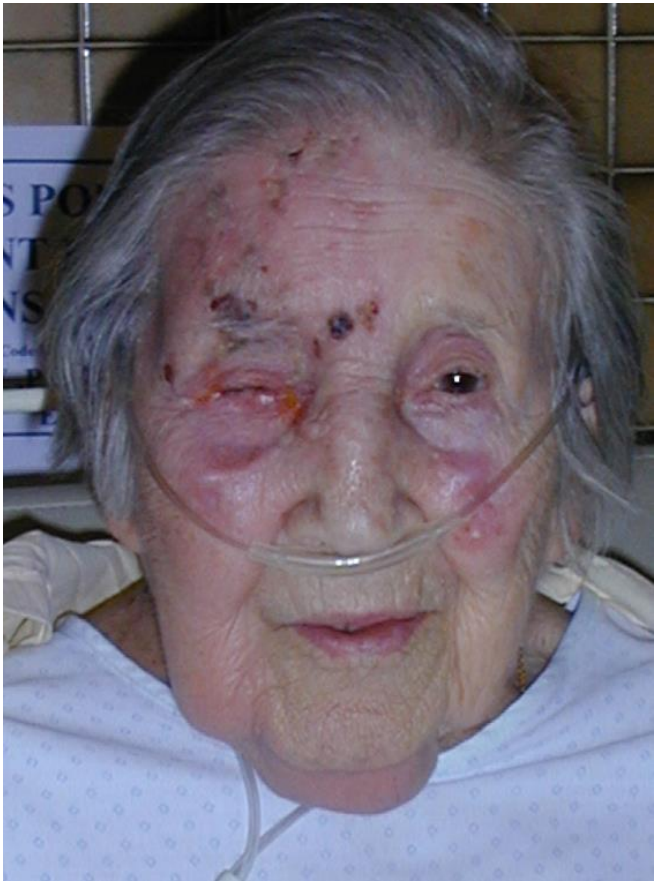Cas 2





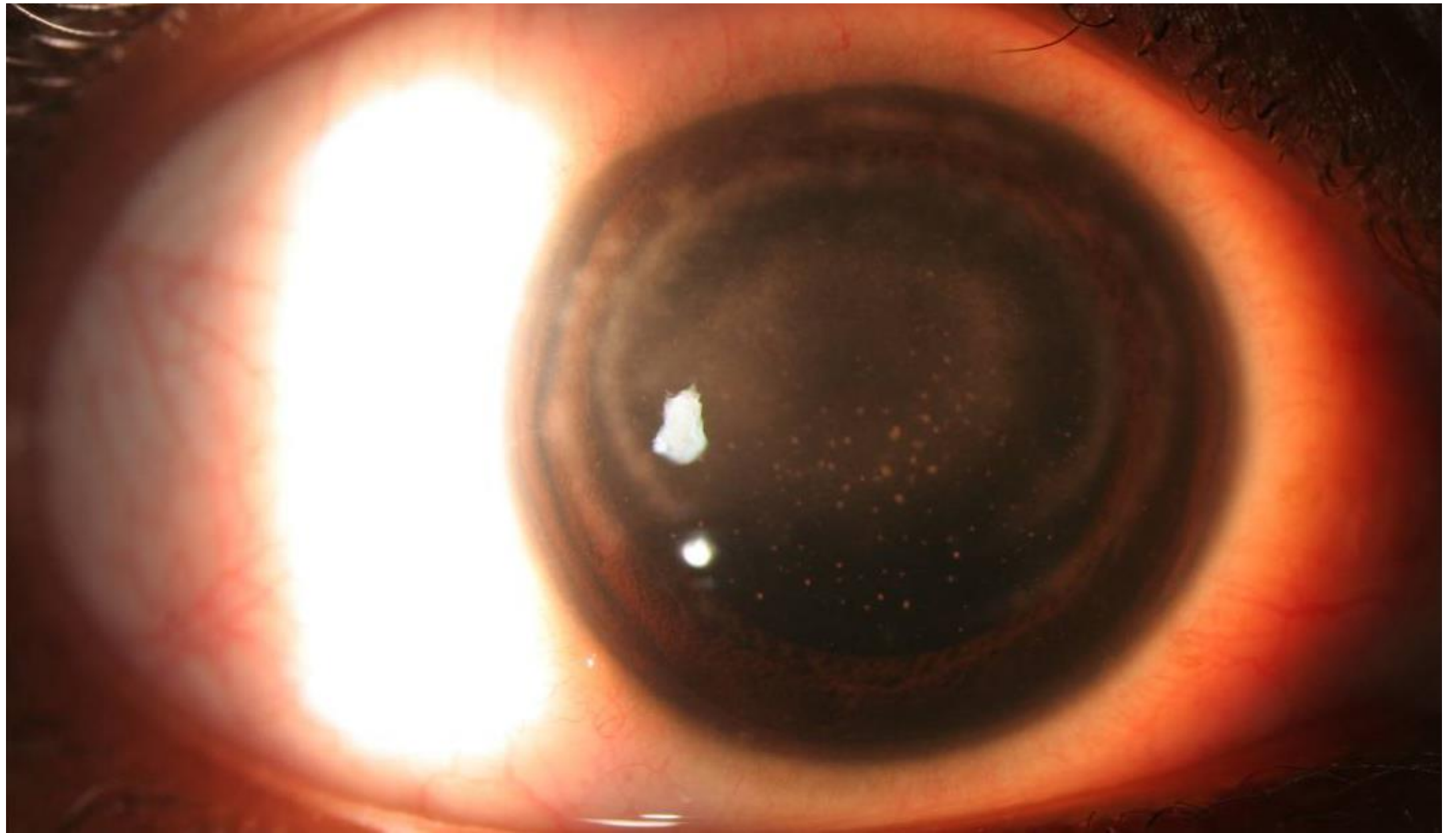
Kératopathie en bandelette et synéchies iridocristalliniennes chez un patient présentant une AJI

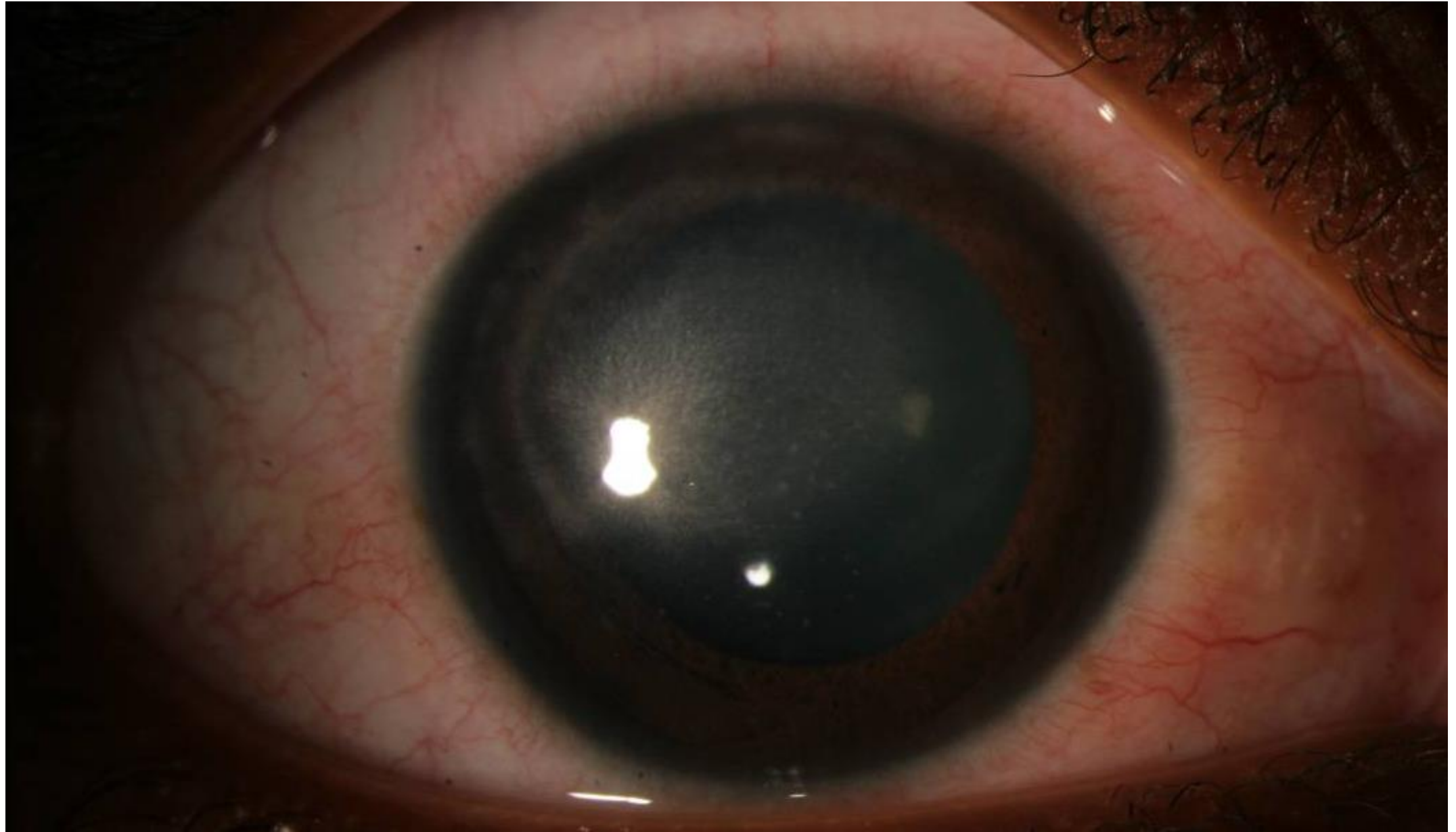
Cas 3



Kératite épithéliale dendritique à VZV sur Zona du V1

- Cas 4

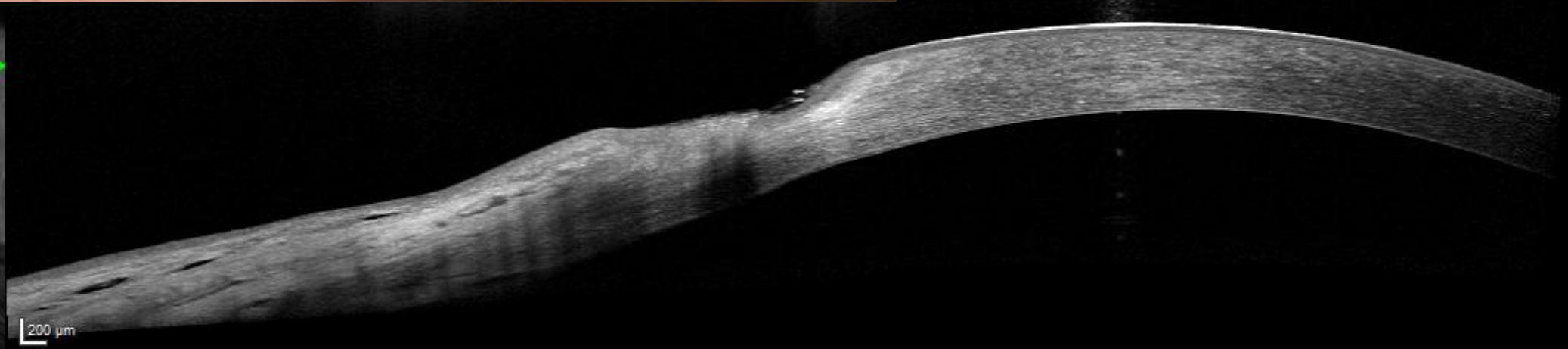
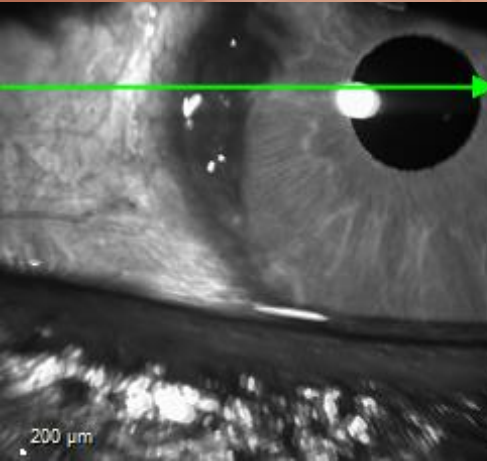
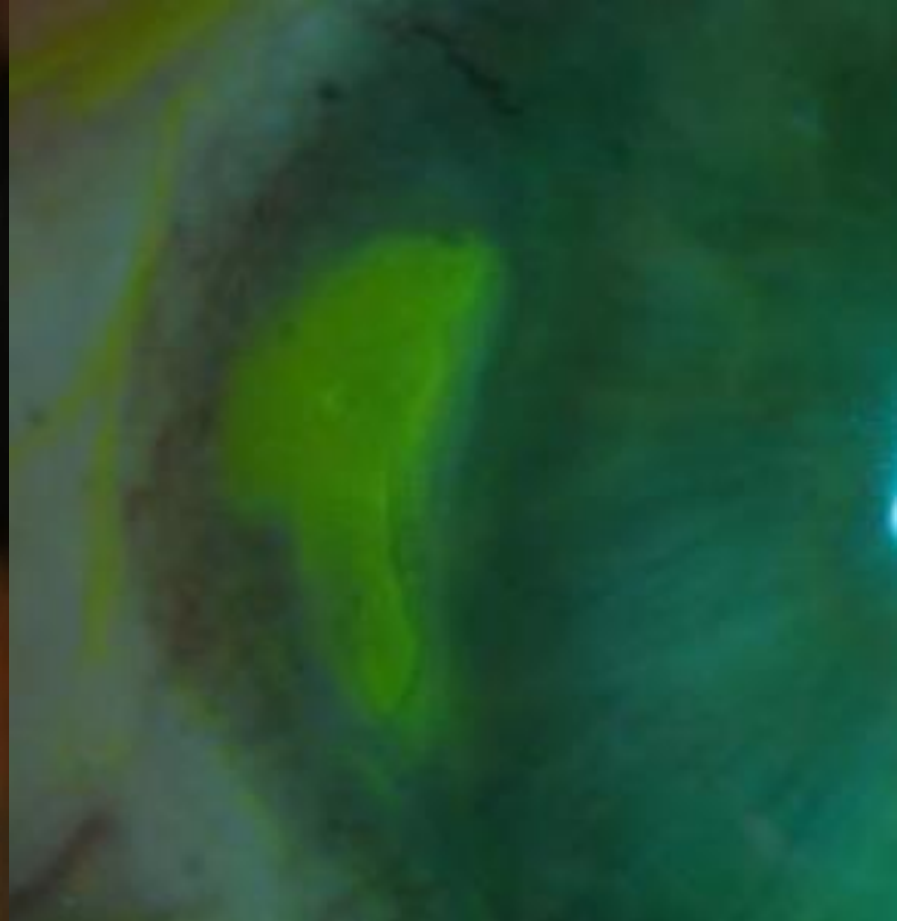
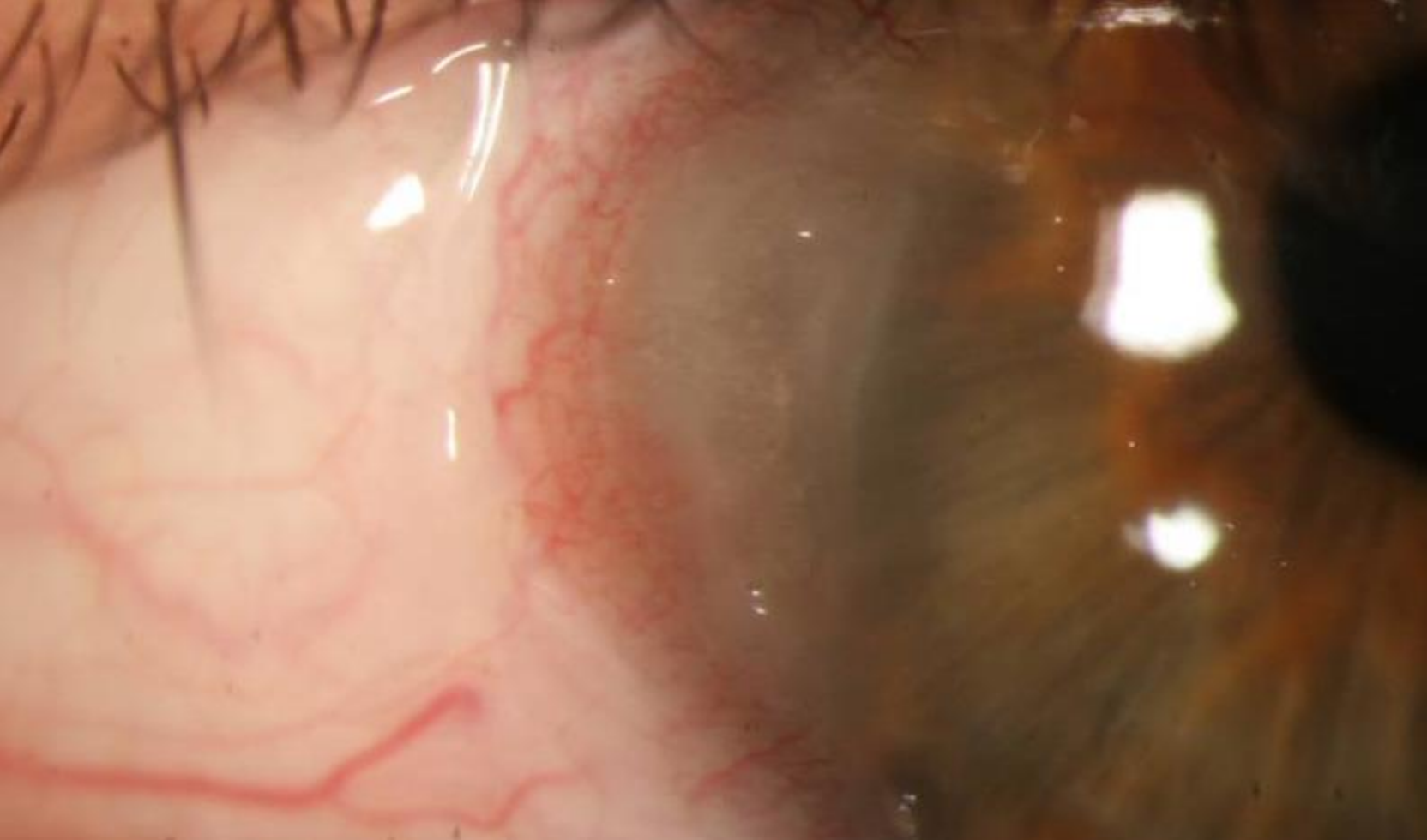


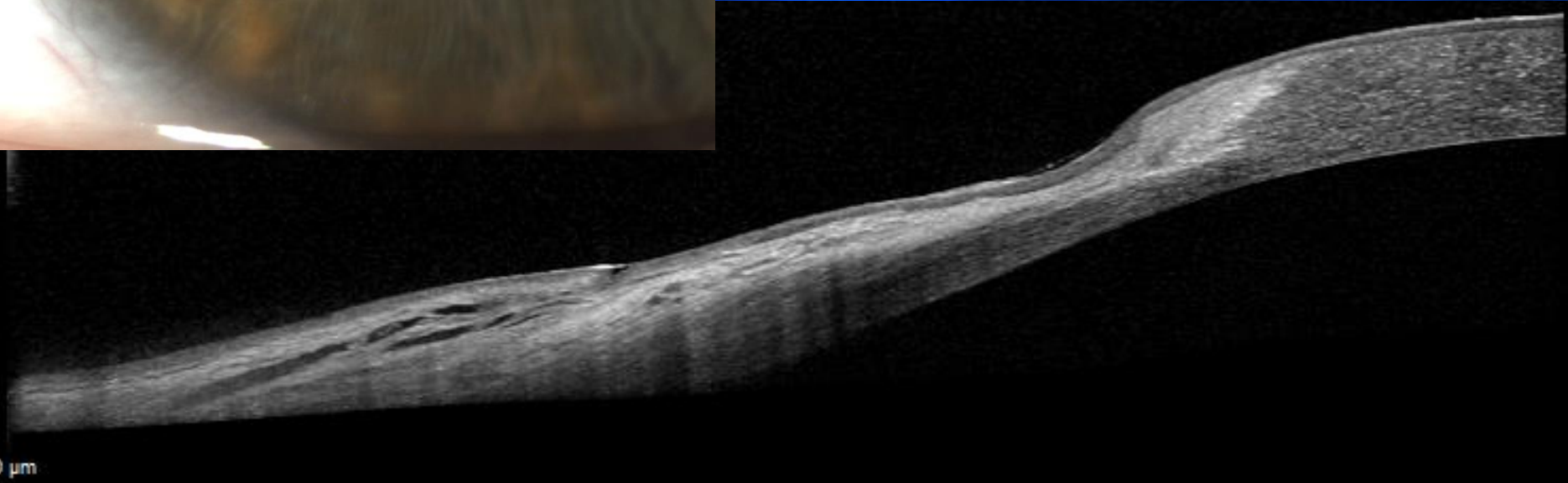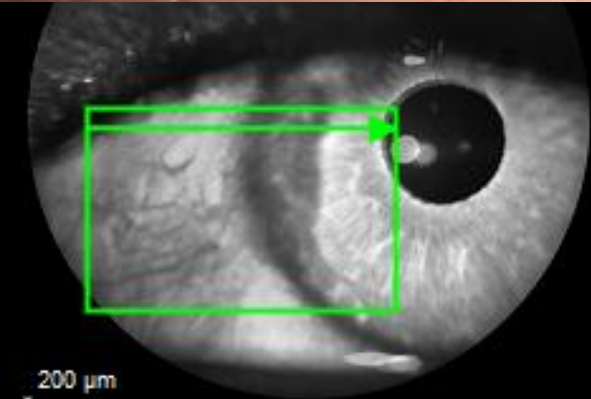
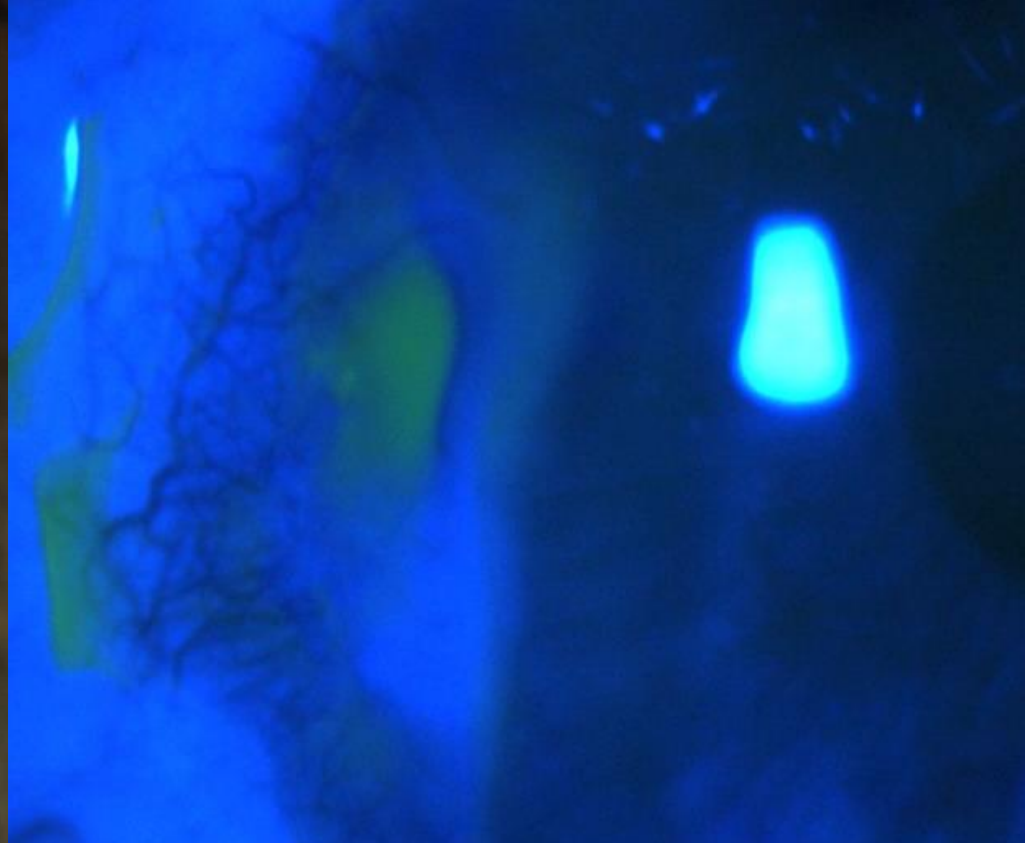
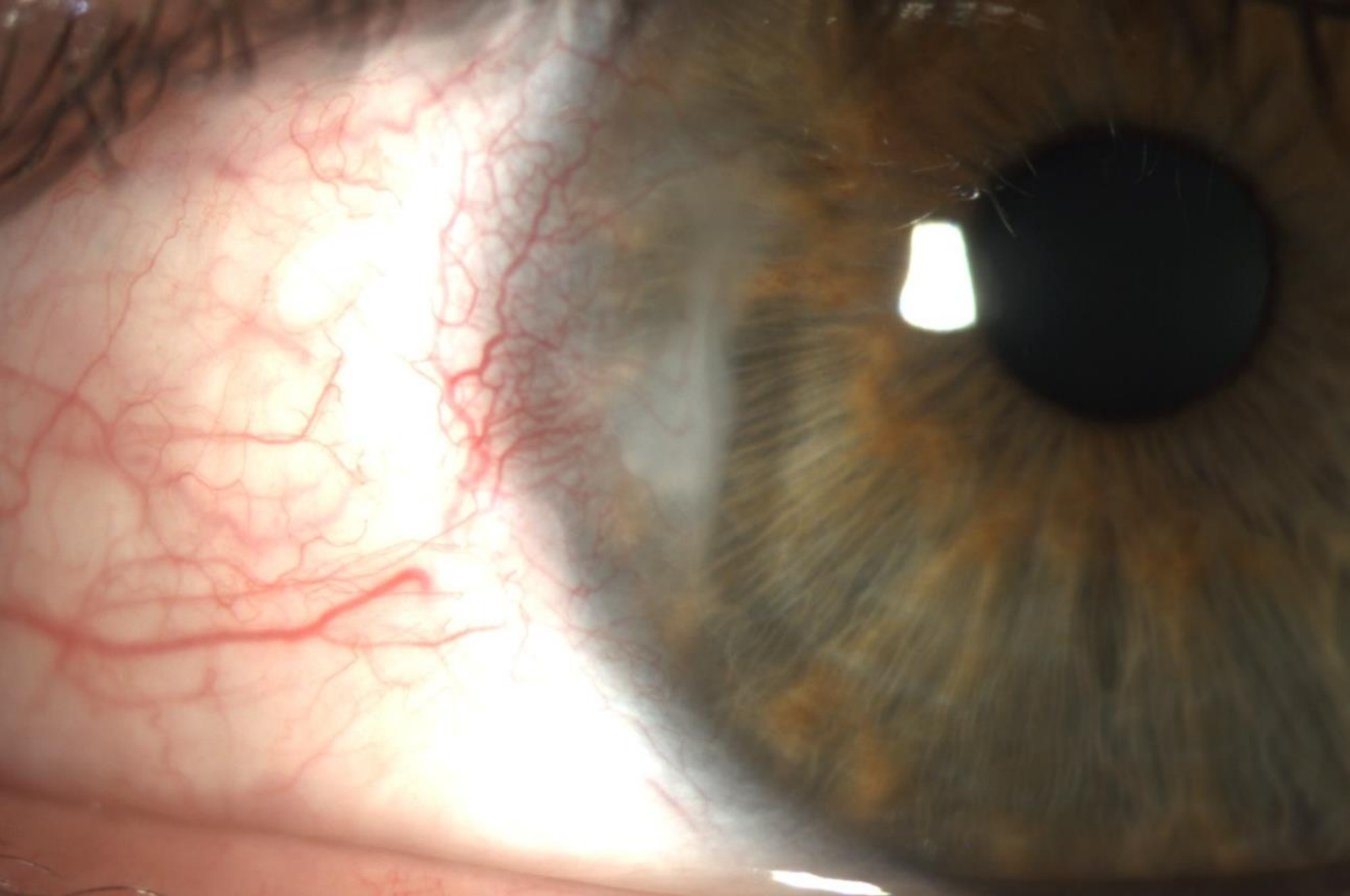


Kératite interstitielle stromale disciforme herpétique



Cas 5





Kératite ulcérate périphérique dans un contexte de polychondrite chronique atrophiante, évolution après traitement maximal :

-Bolus de Solumédrol, Perfusion d'Endoxan, Relais par Remicade.