

Staged Immediate Breast Reconstruction

Michael R. Zenn, M.D.,
M.B.A.
Durham, N.C.



Summary: With the increasing popularity and acceptance of nipple-sparing mastectomy with immediate reconstruction comes an associated higher complication rate of nipple and skin necrosis. Historically, management of this risk has been addressed by predictive technologies or staged surgery with placement of an initial tissue expander. Certain high-risk patients, such as those with large cup size, previous surgery, or previous radiation, may not even be considered for an immediate nipple-sparing mastectomy approach due to even higher rates of complications. This report details a delay technique that allows safe preservation of the nipple-sparing mastectomy tissues, even in high-risk individuals, and facilitates straight-to-implant reconstruction without the need for tissue expansion. The aesthetic benefits, time savings, and acceptable complication profile in this series are presented. (*Plast. Reconstr. Surg.* 135: 976, 2015.)

Nipple-sparing mastectomy has now become commonplace in both the treatment and the prophylaxis of breast cancer.¹⁻⁴ Patients desire to save their breast skin and natural nipple-areolar complexes, and most plastic surgeons would agree that the nipple-sparing mastectomy technique gives the best cosmetic outcomes.⁵⁻⁷ With increased use of the nipple-sparing mastectomy approach has come a steep learning curve in patient selection for the procedure and selection of general surgical colleagues who are able to perform these procedures without a high incidence of nipple and skin necrosis. The problem of nipple and skin necrosis is a real one; it has been reported to be as high as 38 percent in some series.^{8,9}

Some have dealt with this ischemia problem using laser angiography technology to discern levels of ischemia not visible to the human eye. They have reported great success in lowering their own necrosis complication rates by removing at-risk tissues before they necrose.^{10,11} Others have opted to avoid immediate use of the nipple-sparing mastectomy skin envelope for a final reconstruction by placing a tissue expander initially and staging the reconstructive procedure with a second operative procedure after expansion.¹² Both strategies can be effective. Laser angiography requires removal of any ischemic tissue, limiting the final cosmesis

or requiring the placement of a tissue expander. The staged approach effectively delays the skin envelope by not stressing it initially and by performing expansion secondarily. The patient does require office visits for expansions and a second surgical procedure.

One unintended effect of a staged approach is the loss of control over nipple position over time due to skin elasticity, contracture, and the expansion process itself. This has been noticed more and more, and some have made suggestions on how to treat these difficult problems, with nipple grafting at the extreme.¹³⁻¹⁵

The proposed technique of staged immediate breast reconstruction addresses many of the risk factors for skin and nipple necrosis and avoids the need for expansion in most cases. High-risk patients who are often not even considered for nipple-sparing mastectomy are large-breasted patients (greater than C cup), patients with breast ptosis (grade 3), smokers, patients whose breast have previously been irradiated, and patients who have had previous breast surgery (reduction, mastopexy).^{12,16-18} The staged immediate breast reconstruction technique was born out of necessity at our institution, where many of the nipple-sparing mastectomy skin flaps were too ischemic to consider any other surgery in the same setting. In these cases, a “staged-immediate” approach

From Duke University Medical Center.

Received for publication July 7, 2014; accepted September 10, 2014.

Presented in part at the North Carolina Society of Plastic Surgeons Annual Meeting, in Kiawah, S.C., October of 2013.

Copyright © 2015 by the American Society of Plastic Surgeons

DOI: 10.1097/PRS.0000000000001089

Disclosure: The author is a member of the speakers bureau of LifeCell, Bridgewater, N.J. (AlloDerm, SPY), and a consultant for Novadaq, Bonita Springs, Fla. (SPY). The author has no financial interest to declare in relation to the content of this article.

was adopted, effectively delaying the skin flaps for 2 weeks before proceeding with the final reconstruction (Fig. 1). The only unknowns were whether the delay would preserve this at-risk tissue, whether the infection rate would be limiting, and whether patients would tolerate the intervening time period with deflated breasts.

METHODS

Once a patient desiring nipple-sparing mastectomy and immediate reconstruction is identified as being at high risk for necrosis (30 percent of the author’s nipple-sparing mastectomy practice), surgery dates are coordinated with the surgical oncologist to have the mastectomy and the reconstruction 2 weeks apart. The surgical oncologist then performs the mastectomy utilizing any incision desired; the plastic surgery team is not present. I generally prefer vertical or inframammary fold approaches or a radial-lateral incision if a sentinel lymph node procedure will be performed through the same incision. A drain is placed, and the patient is placed on antibiotics for 2 weeks. The plastic surgery department follows up with

the patient at postoperative week 1 to evaluate for complications, review pathology, and remove the drain, regardless of drainage. Sterile seromas help the delay and do not hinder this technique. At 2 weeks, the patient returns to the operating room with the plastic surgeon, where the old nipple-sparing mastectomy incision is reopened and the skin is manually re-expanded. For implants, the pectoralis is elevated and acellular dermal matrix is used to create a sling for the final implant. Implant size is gauged using sizers and knowledge of the mastectomy specimen weight. Two drains are placed, one on each side of the acellular dermal matrix. The patient is sent home on the day of surgery in a soft supportive bra and prescribed antibiotics by mouth until the drains are removed, which is usually at 1 or 2 weeks postoperatively (Figs. 2 and 3).

DISCUSSION

As our oncologic colleagues have become more comfortable with nipple-sparing mastectomy and patients have demanded it, we have experienced an increase in nipple and skin necrosis and have created difficult problems with nipple

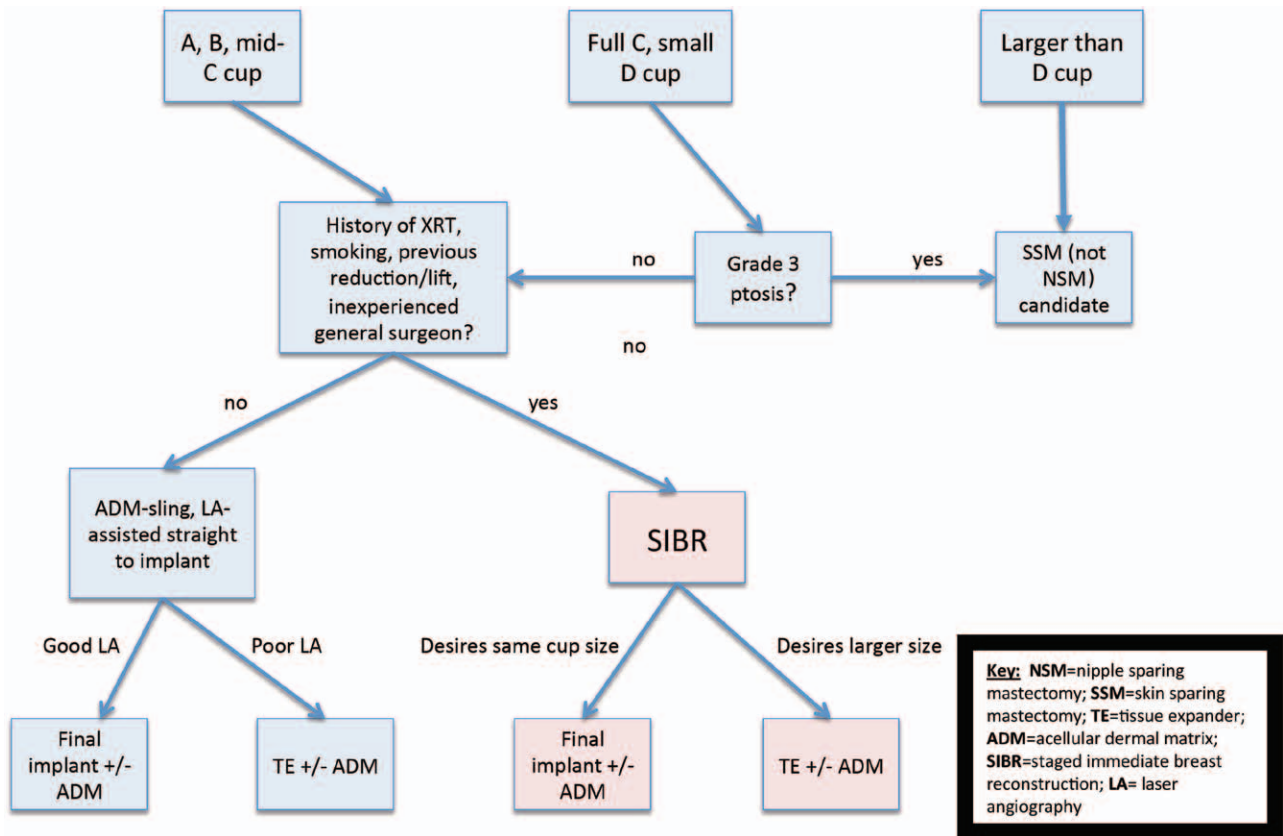


Fig. 1. Nipple-sparing mastectomy decision tree for staged immediate breast reconstruction. Thirty percent of all nipple-sparing mastectomy patients during the study period fell into the “staged-immediate” arm.

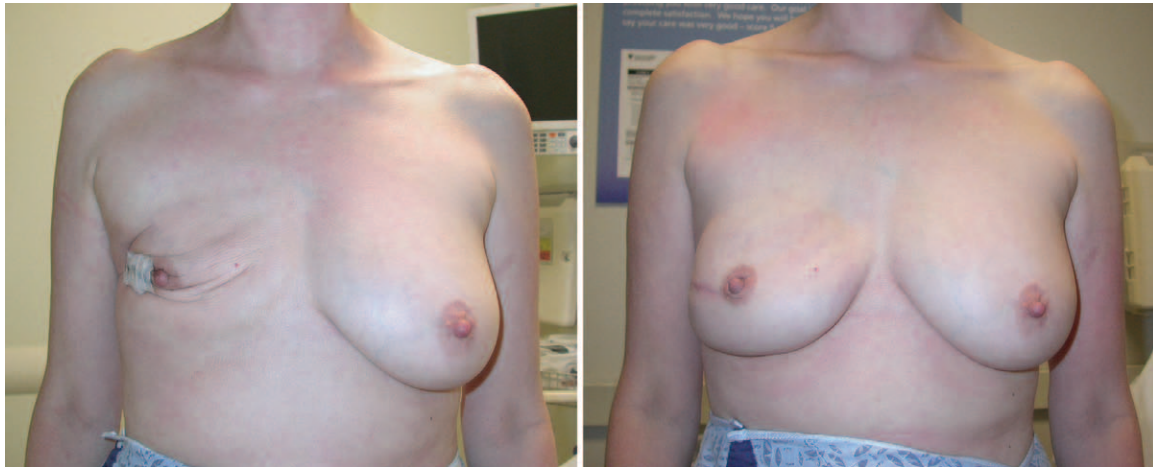


Fig. 2. (Left) A 51-year-old woman is shown 13 days after a lateral approach to nipple-sparing mastectomy. She will now undergo placement of an acellular dermal matrix sling and her final implant. (Right) At 9 months postoperatively, nipple projection and position have been maintained.

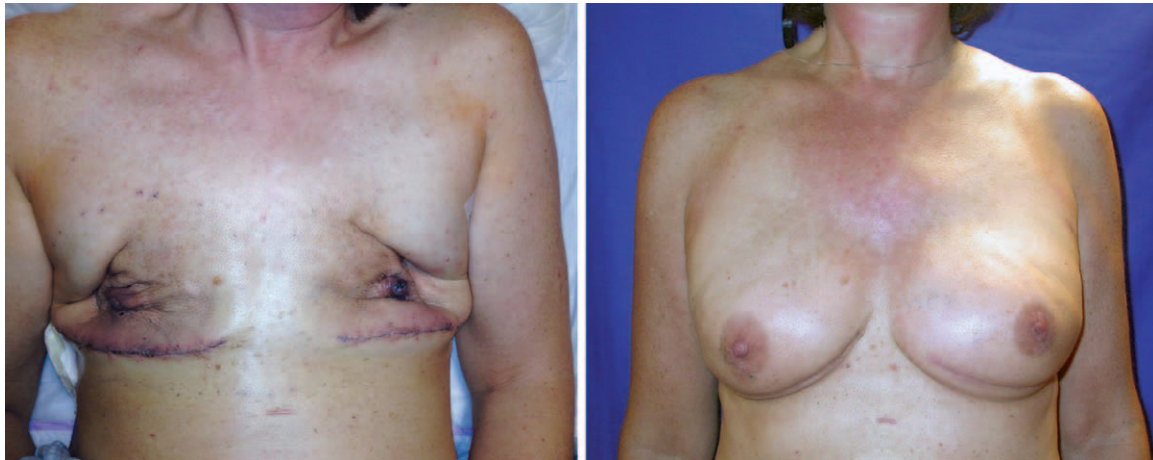

Fig. 3. (Left) A 58-year-old woman is shown on postoperative day 1 after nipple-sparing mastectomy via an inframammary fold approach. The skin flaps under laser angiography looked so poor that no implants or expanders were placed. Her ischemia is obvious even to the naked eye. She returned to the operating room on postoperative day 15 and had acellular dermal matrix slings and final implants placed. (Right) The patient is shown at her 2-month follow-up visit. Note that by using this conservative approach, no skin or nipple tissues were lost and her implants were placed without tissue expansion.

malposition. In the appropriately selected patient, I prefer to place the final implant at the time of nipple-sparing mastectomy and utilize laser angiography to guide that decision process. These patients generally are smaller breasted (C cup or less), have little ptosis (grade I or II), are not smokers, have never had radiation to the breast, and have no scars from previous surgery. Patients who do not fit into these categories are generally at higher risk for necrosis and are either not offered immediate reconstruction or are staged with expanders or other procedures.

Staged immediate breast reconstruction extends the indications for nipple-sparing mastectomy and

immediate reconstruction to patients with higher-than-normal rates of complications. This technique has been performed on 20 patients (30 breasts) over a 3½-year period with a minimum follow-up of 6 months, with final implants placed in 24 breasts and tissue expanders in six breasts. Patients with expander placement desired a larger reconstruction than their natural breasts but were considered to be at high risk for expander placement during their nipple-sparing mastectomy. No patients had bleeding or infectious complications, and only two patients had some superficial necrosis, both of whom healed without further surgery. Patients tolerated the period of deflation well and still considered



CODING PERSPECTIVE

This information provided by Dr. Raymund Janevicius is intended to provide coding guidance.

- 19342 Delayed insertion of breast prosthesis following mastopexy, mastectomy, or in reconstruction
- 15777 Implantation of biologic implant (e.g., acellular dermal matrix) for soft-tissue reinforcement (i.e., breast, trunk)

- Although the procedure is termed a “staged immediate breast reconstruction,” the technique is described with Current Procedural Terminology code 19342. The delayed breast reconstruction code, 19342, takes into account the fact that the incision must be reopened and that wound healing has been taking place.
- Acellular dermal matrix is a “biologic implant” and its placement is reported with code 15777.
- Code 15777 is an add-on code and does not take the multiple procedure modifier, 51.
- If a tissue expander, rather than a permanent prosthesis, is placed, code 19357 is reported.

their reconstructions “immediate.” Seventy-five percent of patients had placement of a final implant and avoided tissue expansion. No procedures for nipple malposition have been required for those with the final implant placed. For those with tissue expansion, all have had asymmetry and have required contralateral surgery, mastopexy, or free nipple grafts.

CONCLUSIONS

The technique of staged immediate breast reconstruction should be considered when experiencing nipple or skin necrosis during nipple-sparing mastectomy cases or when extending the use of nipple-sparing mastectomy to high-risk patients. This series shows that staged immediate breast reconstruction is well tolerated by patients and, in my opinion, leads to comparable or better results than those achieved with immediate placement of a tissue expander.

Michael R. Zenn, M.D., M.B.A.
Duke University Medical Center
136 Baker House, Trent Drive
Durham, N.C. 27710-3358
michael.zenn@duke.edu

REFERENCES

1. Wagner JL, Fearmonti R, Hunt KK, et al. Prospective evaluation of the nipple-areola complex sparing mastectomy for risk reduction and for early-stage breast cancer. *Ann Surg Oncol.* 2012;19:1137–1144.
2. Chu C, Carlson G. Techniques and outcomes of nipple sparing mastectomy in the surgical management of breast cancer. *Curr Breast Cancer Rep.* 2013;5:118–124.
3. Gerber B, Krause A, Dieterich M, Kundt G, Reimer T. The oncological safety of skin sparing mastectomy with conservation of the nipple-areola complex and autologous reconstruction: An extended follow-up study. *Ann Surg.* 2009;249:461–468.
4. Mallon P, Feron JG, Couturaud B, et al. The role of nipple-sparing mastectomy in breast cancer: A comprehensive review of the literature. *Plast Reconstr Surg.* 2013;131:969–984.
5. Salgarello M, Visconti G, Barone-Adesi L. Nipple-sparing mastectomy with immediate implant reconstruction: Cosmetic outcomes and technical refinements. *Plast Reconstr Surg.* 2010;126:1460–1471.
6. Spear SL, Hannan CM, Willey SC, Cocilovo C. Nipple-sparing mastectomy. *Plast Reconstr Surg.* 2009;123:1665–1673.
7. Djohan R, Gage E, Gatherwright J, et al. Patient satisfaction following nipple-sparing mastectomy and immediate breast reconstruction: An 8-year outcome study. *Plast Reconstr Surg.* 2010;125:818–829.
8. Endara M, Chen D, Verma K, Nahabedian MY, Spear SL. Breast reconstruction following nipple-sparing mastectomy: A systematic review of the literature with pooled analysis. *Plast Reconstr Surg.* 2013;132:1043–1054.
9. Colwell AS, Damjanovic B, Zahedi B, Medford-Davis L, Hertl C, Austen WG Jr. Retrospective review of 331 consecutive immediate single-stage implant reconstructions with acellular dermal matrix: Indications, complications, trends, and costs. *Plast Reconstr Surg.* 2011;128:1170–1178.
10. Murray JD, Jones GE, Elwood ET, Whitty LA, Garcia C. Laser angiography as a predictor of mastectomy flap necrosis after breast reconstruction. *Plast Reconstr Surg.* 2012;129:1017e–1018e.
11. Phillips BT, Lanier ST, Conkling N, et al. Intraoperative perfusion techniques can accurately predict mastectomy skin flap necrosis in breast reconstruction: Results of a prospective trial. *Plast Reconstr Surg.* 2012;129:778e–788e.
12. Spear SL, Rottman SJ, Seiboth LA, Hannan CM. Breast reconstruction using a staged nipple-sparing mastectomy following mastopexy or reduction. *Plast Reconstr Surg.* 2012;129:572–581.
13. Nahabedian MY, Tsangaris TN. Breast reconstruction following subcutaneous mastectomy for cancer: A critical appraisal of the nipple-areola complex. *Plast Reconstr Surg.* 2006;117:1083–1090.
14. Taneda H, Sakai S. Transposition technique for correction of a malpositioned nipple-areola complex after reconstruction following a nipple-sparing mastectomy: A case report. *Ann Plast Surg.* 2011;67:579–582.
15. Small K, Kelly KM, Swistel A, Dent BL, Taylor EM, Talmor M. Surgical treatment of nipple malposition in nipple-sparing mastectomy device-based reconstruction. *Plast Reconstr Surg.* 2014;133:1053–1062.
16. Salzberg CA. Focus on technique: One-stage implant-based breast reconstruction. *Plast Reconstr Surg.* 2012;130(5 Suppl 2):95S–103S.
17. Sahin I, Isik S, Alhan D, Yildiz R, Aykan A, Ozturk E. One-staged silicone implant breast reconstruction following bilateral nipple-sparing prophylactic mastectomy in patients at high-risk for breast cancer. *Aesthetic Plast Surg.* 2013;37:303–311.
18. Kronowitz SJ, Robb GL. Radiation therapy and breast reconstruction: a critical review of the literature. *Plast Reconstr Surg.* 2009;124:395–408.