

# Acellular Dermal Matrix for the Treatment and Prevention of Implant-Associated Breast Deformities

Scott L. Spear, M.D.  
Mitchel Seruya, M.D.  
Mark W. Clemens, M.D.  
Steven Teitelbaum, M.D.  
Maurice Y. Nahabedian,  
M.D.

Washington, D.C.; and Los Angeles,  
Calif.

**Background:** Acellular dermal matrix has been increasingly accepted in prosthetic breast reconstruction. Observed benefits include improved control and support of implant position, better implant coverage, and the suggestion of a decreased capsular contracture rate. Based on this positive experience, it is not surprising that acellular dermal matrix would be applied to other challenging implant-related problems. This study investigates the use of acellular dermal matrix for correction or prevention of implant-associated breast deformities.

**Methods:** Patients who underwent primary aesthetic breast surgery or secondary aesthetic or reconstructive breast surgery using acellular dermal matrix and implants between November of 2003 and October of 2009 were reviewed retrospectively. Patient demographics, indications for acellular dermal matrix, and acellular dermal matrix type and inset pattern were identified. Preoperative and postoperative photographs, success or failure of the procedure, complications, and need for related or unrelated revision surgery were recorded.

**Results:** Fifty-two patients had acellular dermal matrix placed alongside 77 breast prostheses, with a mean follow-up of 8.6 months (range, 0.4 to 30.4 months). Indications included prevention of implant bottoming-out ( $n = 6$ ), treatment of malposition ( $n = 32$ ), rippling ( $n = 20$ ), capsular contracture ( $n = 16$ ), and skin flap deficiency ( $n = 16$ ). Seventy-four breasts (96.1 percent) were managed successfully with acellular dermal matrix. Three failures consisted of one breast with bottoming-out following treatment of capsular contracture, one breast with major infection requiring device explantation, and one breast with recurrent rippling. There was a 9.1 percent total complication rate, consisting of three mild infections, one major infection necessitating explantation, one hematoma, and one seroma.

**Conclusion:** Based on this experience in 77 breasts, acellular dermal matrix has shown promise in treating and preventing capsular contracture, rippling, implant malposition, and soft-tissue thinning. (*Plast. Reconstr. Surg.* 127: 1047, 2011.)

Since 2006, an increasing number of studies have highlighted the beneficial use of acellular dermal matrix in primary prosthetic breast reconstruction.<sup>1-12</sup> Reported benefits include better control of implant position, better implant support

and coverage, and the suggestion of a decreased frequency of capsular contracture.<sup>1-6,8-11,13-15</sup> Gamboa-Bobadilla placed human acellular dermal matrix alongside 13 breast prostheses with poor pectoralis major muscle coverage and found that 92 percent of patients had a successful breast recon-

*From the Department of Plastic Surgery, Georgetown University Hospital, and the David Geffen School of Medicine at the University of California, Los Angeles.*

*Received for publication April 18, 2010; accepted August 13, 2010.*

*Presented in part at the 26th Annual Meeting of the Northeastern Society of Plastic Surgeons, in Charleston, South Carolina, September 23 through 27, 2009, and the 2010 Plastic Surgery Senior Residents Conference, in Anaheim, California, January 20 through 23, 2010.*

*Copyright ©2011 by the American Society of Plastic Surgeons*

DOI: 10.1097/PRS.0b013e31820436af

**Disclosure:** Dr. Spear is a paid consultant for LifeCell and Allergan. Dr. Teitelbaum is a consultant for LifeCell, Allergan, and Kythera Biopharmaceuticals. Dr. Nahabedian is on the speaker's bureau for LifeCell. Drs. Clemens and Seruya have no financial interest in any of the products, devices, or drugs mentioned in this article.

struction and 73 percent had an “excellent” aesthetic outcome.<sup>2</sup> In a series of 76 immediate, single-stage prosthetic breast reconstructions using human acellular dermal matrix, Salzberg reported a 0 percent contracture rate and a 0 percent “serious” complication rate over a 52-month follow-up period.<sup>3</sup> Zienowicz and Karacaoglu observed a 0 percent rate of contracture, rippling, symmastia, or bottoming-out in a study of 30 immediate implant-breast reconstructions with human acellular dermal matrix over an 18-month mean follow-up period.<sup>6</sup> Breuing and Colwell placed human acellular dermal matrix alongside 44 breast prostheses and identified a 0 percent contracture rate, a 2.3 percent extrusion rate, and a 4.5 percent infection rate over a 6-month to 3-year surveillance period.<sup>5</sup>

In addition to investigating the use of acellular dermal matrix in primary prosthetic breast reconstruction, a limited number of studies have studied the application of acellular dermal matrix in the treatment of breast implant-associated deformities.<sup>5,16–19</sup> Prosthetic breast surgery can be complicated by either capsular attenuation, manifesting as implant malposition or rippling, or capsular contracture, presenting as implant firmness or distortion. To correct breast implant rippling in 34 patients, Duncan used human acellular dermal matrix and observed an improvement in palpable rippling, an average patient satisfaction of 85 percent, a 2.9 percent rate of capsular contracture, and a 2.9 percent rate of infection.<sup>16</sup> In a series of 10 patients with breast implant-related problems, including rippling, bottoming-out, symmastia, and contracture, Baxter found that 80 percent of revisions were stable with the use of human acellular dermal matrix.<sup>17</sup> Breuing and Colwell reported a 0 percent recurrence of contracture in 23 breasts treated with capsulectomy and human acellular dermal matrix for implant-related contracture.<sup>5</sup> Most recently, Maxwell and Gabriel demonstrated decreased rates of capsular contracture and improved implant cushioning and stabilization using acellular dermal matrix in revisionary aesthetic breast surgery of 78 patients.<sup>19</sup>

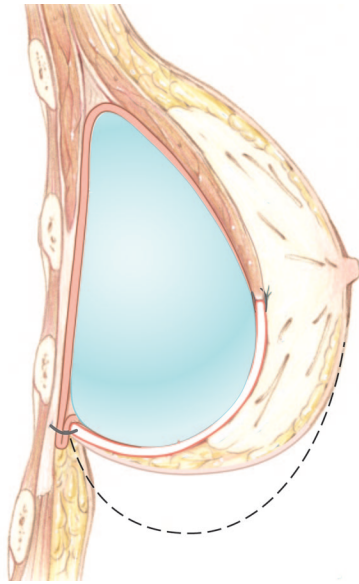
Given the safety and efficacy of acellular dermal matrix in primary prosthetic breast reconstruction<sup>1–6,9–11</sup> and the encouraging preliminary data on the use of acellular dermal matrix in select cases of secondary prosthetic breast surgery,<sup>5,16–19</sup> we hypothesize that acellular dermal matrix may be a useful adjunct in the treatment and prevention of some implant-associated deformities. The purpose of the present study is to review experience with acellular dermal matrix for correction or prevention of implant-associated

breast deformities and describe the key technical aspects. This is especially significant because many of these problems have proven extraordinarily difficult to consistently correct in the past.<sup>20–28</sup>

## PATIENTS AND METHODS

An institutional review board–approved, retrospective review was carried out on patients operated on between November of 2003 and October of 2009 at Georgetown University Hospital (S.L.S. and M.Y.N.) and in the practice of Steven Teitelbaum, M.D. Patients who underwent primary aesthetic breast surgery or secondary aesthetic/reconstructive breast surgery using acellular dermal matrix and implants were identified. Techniques to address breast implant–related deformities often included a combination of implant exchange, device position change, capsule modification, and placement of acellular dermal matrix. When warranted, devices were exchanged and/or relocated to a subglandular, prepectoral, subpectoral, or neosubpectoral pocket. When necessary, capsule modification was performed by means of capsulotomy, capsulectomy, and/or capsulorrhaphy. Depending on the breast implant–associated complication, acellular dermal matrix was placed alongside breast implants using a “reconstructive,” “gutter,” “symmastia,” or “overlay” technique.<sup>29</sup>

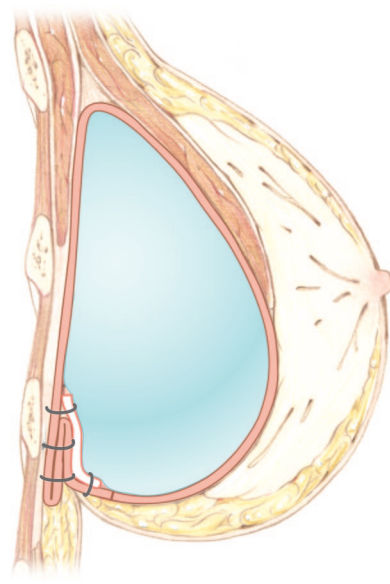
To treat difficult/recurrent capsular contracture, rippling, or implant bottoming-out, or to prevent loss of inframammary fold definition and bottoming-out, the reconstructive technique is used (Fig. 1). This involves interpositional (between the pectoralis major muscle and chest wall) placement of acellular dermal matrix, as described previously by the authors.<sup>8</sup> In the case of AlloDerm (LifeCell Corp., Branchburg, N.J.), acellular dermal matrix is oriented with the deep dermal surface facing the skin flaps and centered over the mid arc of the inframammary/lateral mammary fold, providing maximal coverage and support where most necessary. Strattice (LifeCell), in contrast, does not require such orientation. Next, the inferior border of the acellular dermal matrix is sutured to the chest wall tissue, to best control the inframammary and lateral mammary folds. The appropriate device is then placed into the pocket and seated accordingly. Care is taken to achieve a “hand-in-glove” fit between the breast device, acellular dermal matrix graft, and breast skin flaps. The superior border of the acellular dermal matrix is then sutured to the pectoralis major muscle, minimizing gap formation and thus the risk of direct exposure of the



**Fig. 1.** The “reconstructive” technique. Inset of an acellular dermal matrix interpositional graft, lying between the pectoralis major muscle and chest wall. As an inferolateral sling, the acellular dermal matrix aids in supporting the implant and defining the breast lower pole. (Reprinted with permission from LifeCell Corp.)

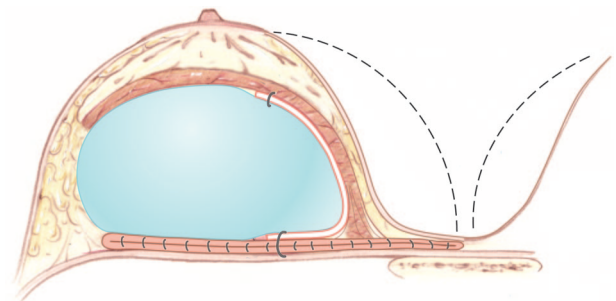
prosthesis to a mastectomy incision. To reduce the risk of fluid accumulation between the acellular dermal matrix and the breast implant or between the acellular dermal matrix and the breast skin flaps, drains are placed. Similar to a skin graft, the acellular dermal matrix should appear relatively smooth without major folds or wrinkles and should be in good contact with the breast skin flaps to ensure proper take and integration. Drains are left in place until the output is less than 30 ml over a 24-hour period.

To address inferior malposition, the gutter technique is used to reinforce the fold repair (Fig. 2). Preoperatively, the site of the newly desired inframammary fold is noted and marked on the patient. The operation begins with a skin incision and removal of the prior device. A capsulorrhaphy is then carried out in one or more rows, tacking the anterior and posterior leaflets of the capsule together and to the chest wall, thereby recreating the desired inframammary fold. An implant sizer is placed to verify that the inframammary fold is correctly set. To reinforce the fold repair, an appropriate piece of acellular dermal matrix is then selected and inset over the capsulorrhaphy suture line with 1 to 2 cm of overlap. The chosen implant is then placed in the reestablished pocket. A small drain is optional and completes the operation.



**Fig. 2.** The “gutter” technique, with placement of acellular dermal matrix over the capsulorrhaphy suture line to reinforce the fold repair in the setting of lateral or inferior malposition. (Reprinted with permission from LifeCell Corp.)

For correction of recurrent medial malposition, the symmastia technique is used (Fig. 3). Preoperatively, the site of the newly desired medial breast border is marked on the patient. Initial operative steps include the creation of a neosubpectoral pocket and/or performance of a multilayer breast capsulorrhaphy to establish the desired medial breast border, as described previously.<sup>20,30</sup> To create a neosubpectoral pocket, the pectoralis major muscle is dissected away from the anterior leaflet of the capsule. The implant is kept in the capsule as long as possible to facilitate dissection and is removed through an open capsulotomy when it is no longer helpful. Of importance, the newly es-

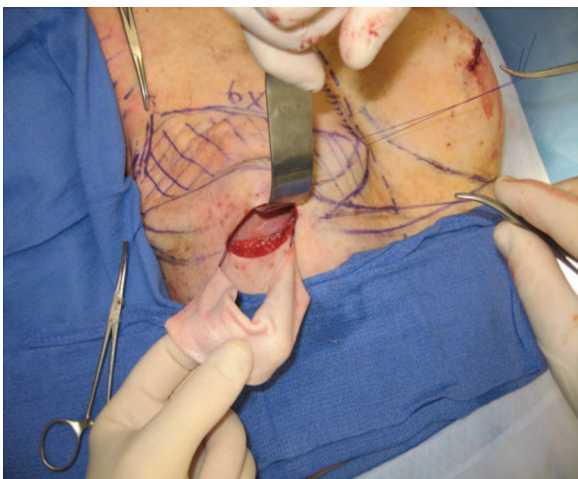


**Fig. 3.** The “symmastia” technique, with creation of a neosubpectoral pocket and inset of acellular dermal matrix along the pectoralis major muscle/capsule interface in the context of medial malposition. (Reprinted with permission from LifeCell Corp.)



tablished pocket is purposely underdissected medially. Once the neosubpectoral pocket is formed, the original pocket is closed off by tacking the anterior and posterior leaflets of the capsule together and to the chest wall. To prevent migration of the device into the old implant space, an appropriate piece of acellular dermal matrix is then placed medially over the suture line and/or pectoralis/capsule interface generally with 1 to 2 cm of overlap. If implant lower pole support is also necessary, the acellular dermal matrix inset can be extended with an inferior cuff to help cradle the device. A sizer or implant is used, sometimes in conjunction with temporary or permanent marionette (percutaneous, horizontal mattress) sutures, to ensure that the acellular dermal matrix is in appropriate position and set on appropriate tension. The desired breast implant is then placed, followed by insertion of a single small drain as necessary.

To address thin breast skin flaps, the overlay (between implant and capsule) technique is generally used (Fig. 4). Preoperatively, areas of soft-tissue deficiency are marked out on the patient. Operative steps begin with an open capsulotomy and removal of the old device. Areas of capsular thinning are noted and verified with the preoperative markings. Acellular dermal matrix is then placed inside the device pocket and draped over the thin capsular regions. With the aid of a sizer or the final implant, the acellular dermal matrix is set on appropriate stretch and free of wrinkles or folds on inset. Capsule and skin closure is carried out in routine fashion.



**Fig. 4.** The “overlay” technique. Acellular dermal matrix is parachuted into the device pocket with the use of marionette sutures and draped over thin capsular regions to address areas of soft-tissue deficiency.

Generally, patients were discharged on the day of surgery or, in rare cases, on postoperative day 1. Oral antibiotics were continued until drain removal, typically once the output was less than 30 ml/day. Marionette (percutaneous, horizontal mattress) sutures, if used, were usually discontinued 7 to 10 days postoperatively under sterile technique. This consisted of swabbing the external skin sutures with alcohol, cutting one end of the suture flush at the level of the skin, and pulling the other end of the suture out of the skin. These series of maneuvers may help prevent introduction of skin flora into the breast pocket and the risk of infection.

Office charts and hospital records were reviewed retrospectively for patient demographics, indications for acellular dermal matrix, and type of acellular dermal matrix and inset pattern. Associated demographics included patient age, body mass index, former or active tobacco use, history of chemotherapy, and exposure to radiotherapy. Indications for acellular dermal matrix use were sometimes multiple and included the prevention of implant bottoming-out and the correction of capsular contracture, rippling, implant malposition, and soft-tissue thinning. Depending on cost and availability, human-derived acellular dermal matrix, specifically AlloDerm, or porcine-derived acellular dermal matrix (Strattice) was used.

Preoperative and postoperative photographs, failure of the procedure, complications, and need for related and unrelated revision surgery were recorded. Complications assessed included infection, implant loss or exposure, hematoma, and seroma. Infections were categorized as mild, defined as warmth, swelling, cellulitis, or nonpurulent drainage that was responsive to initial antibiotic therapy; or severe, characterized as persistent or substantial warmth/erythema/swelling despite antibiotic therapy. Related revision procedures were defined as those operations performed to address an issue directly related to the performance of acellular dermal matrix placement. Unrelated revision operations were defined as those procedures performed to address an issue not associated with the performance of acellular dermal matrix placement.

For statistical analysis, the Fisher's exact test was used for evaluation of percentages or frequencies. A value of  $p < 0.05$  was considered statistically significant.

## RESULTS

Over a 6-year period, 52 patients (28 aesthetic and 24 reconstructive) had acellular dermal ma-

trix placed alongside 77 breast prostheses (43 aesthetic and 34 reconstructive). Patient demographics are summarized in Table 1. The mean age of the patients was 44.4 years, with a range of 21 to 66 years, and the average body mass index was 21.5. Among aesthetic patients, 82.1 percent were nonsmokers, 7.1 percent were former smokers, and 10.7 percent were active smokers. In reconstructive patients, 91.7 percent were nonsmokers, 0 percent were former smokers, and 8.3 percent were active smokers. Among reconstructive patients, 41.7 percent had a history of radiotherapy and 45.8 percent had a history of chemotherapy. None of the aesthetic patients had a history of radiotherapy or chemotherapy.

Indications for acellular dermal matrix are summarized in Table 2 and included prevention of implant bottoming-out ( $n = 6$ ) and treatment of malposition ( $n = 32$ ), rippling ( $n = 20$ ), cap-

sular contracture ( $n = 16$ ), and skin flap deficiency ( $n = 16$ ). Of note, 26.9 percent of patients had more than one indication for acellular dermal matrix use. Among the 77 breast prostheses, 39 had AlloDerm placement and 38 had Strattice.

Complication rates were 7.0, 11.8, and 9.1 percent for aesthetic, reconstructive, and total breast operations, respectively (Table 3). Complications consisted of three mild infections, one major infection requiring explantation, one hematoma, and one seroma. Total complications were higher in irradiated versus nonirradiated breasts, although this was not found to be statistically significant (20.0 percent and 7.4 percent, respectively;  $p = 0.223$ ). Comparison of overall complication rates between Strattice and AlloDerm was not found to be statistically significant (10.3 percent and 7.7 percent, respectively;  $p = 0.71$ ).

Five breasts underwent unrelated revision surgery. After successful correction of bilateral implant bottoming-out with interpositional acellular dermal matrix grafts, one patient underwent bilateral revision augmentation-mastopexy because of a desire for smaller implants. After successful treatment of left reconstructed breast (pedicled transverse rectus abdominis musculocutaneous flap) symmastia with acellular dermal matrix, one patient underwent transverse rectus abdominis musculocutaneous flap revision with raising of the inframammary fold. After successful correction of left implant inferior malposition with interpositional acellular dermal matrix graft, one patient underwent left implant size change and revision mastopexy to improve symmetry opposite her reconstructed right breast. Finally, after successful correction of bilateral symmastia, one patient underwent right implant size change and left breast lipoinfiltration to address a superomedial depression.

With a mean follow-up of 8.6 months (range, 0.4 to 30.4 months), 74 breasts (96.1 percent) were successfully managed with acellular dermal ma-

**Table 1. Patient Demographics**

|                                    | Value (%) |
|------------------------------------|-----------|
| No. of patients                    |           |
| Aesthetic                          | 28 (53.8) |
| Reconstructive                     | 24 (46.2) |
| Age, yr                            |           |
| Average                            | 44.4      |
| Range                              | 21–66     |
| Mean BMI, kg/m <sup>2</sup>        | 21.5      |
| No. with preoperative chemotherapy |           |
| Aesthetic                          | 0 (0.0)   |
| Reconstructive                     | 11 (45.8) |
| No. with preoperative radiotherapy |           |
| Aesthetic                          | 0 (0.0)   |
| Reconstructive                     | 10 (41.7) |
| Smoking history                    |           |
| No. of nonsmokers                  |           |
| Aesthetic                          | 23 (82.1) |
| Reconstructive                     | 22 (91.7) |
| No. of former smokers              |           |
| Aesthetic                          | 2 (7.1)   |
| Reconstructive                     | 0 (0.0)   |
| No. of active smokers              |           |
| Aesthetic                          | 3 (10.7)  |
| Reconstructive                     | 2 (8.3)   |

BMI, body mass index.

**Table 2. Indications for Acellular Dermal Matrix in the Treatment and Prevention of Implant-Related Breast Deformities**

|                             | No. |
|-----------------------------|-----|
| Patients                    | 52  |
| Operative breasts           | 77  |
| Indications*                | 90  |
| Malposition                 | 32  |
| Rippling                    | 20  |
| Capsular contracture        | 16  |
| Skin flap deficiency        | 16  |
| Prevention of bottoming-out | 6   |

\*Indications are per breast and were sometimes multiple.

**Table 3. Complications following Acellular Dermal Matrix Use in the Treatment and Prevention of Implant-Related Breast Deformities**

|              | Aesthetic Breasts<br>( $n = 43$ ) |              | Reconstructive<br>Breasts ( $n = 34$ ) |              |
|--------------|-----------------------------------|--------------|--|--------------|
|              | No.                               | % of Breasts | No.                                    | % of Breasts |
| Infection    | 1                                 | 2.3          | 3                                      | 5.9          |
| Explantation | 1                                 | 2.3          | 0                                      | 0.0          |
| Seroma       | 0                                 | 0.0          | 1                                      | 2.9          |
| Hematoma     | 1                                 | 2.3          | 0                                      | 0.0          |
| Total        | 3                                 | 7.0          | 4                                      | 11.8         |

trix. Three failures consisted of one breast with bottoming-out following treatment of capsular contracture, one breast with major infection following symmastia repair requiring device explantation and delayed replacement, and one breast with recurrent rippling necessitating repeat acellular dermal matrix placement (Table 4). Comparison of failure rates between Strattice and AlloDerm was not found to be statistically significant (5.3 percent and 2.6 percent, respectively;  $p = 0.62$ ).

The first failure consisted of a 43-year-old woman with a history of multiple breast augmentations performed at an outside hospital to address left-sided infection and capsular contracture, who presented with recurrent left capsular contracture. The patient underwent left revision augmentation with insertion of a 450-cc, moderate-profile, silicone implant in a neosubpectoral pocket and placement of acellular dermal matrix (10 × 16 cm) as an interpositional graft between the pectoralis major muscle and the chest wall (reconstructive technique). The acellular dermal matrix was found intraoperatively to be too small to adequately serve as an inferolateral sling and still be attached at both the pectoralis major muscle and the inframammary fold. Over the subsequent months, the patient presented with bottoming-out of her implant.

The second failure consisted of a 31-year-old woman with a history of multiple breast augmentations performed by an outside surgeon to correct symmastia and who presented with recurrent symmastia. The patient underwent bilateral revision breast augmentation with insertion of smooth, round silicone implants in a neosubpectoral pocket and placement of acellular dermal matrix using the above-described symmastia technique. Three weeks postoperatively, the patient presented with increasing pain, redness, and swelling of the right breast. Fluid aspiration was consistent with a methicillin-resistant *Staphylococcus aureus*-associated abscess. The patient underwent device explantation and curettage of the implant

capsule, with preservation of the acellular dermal matrix, given its good integration with the surrounding tissue. Six months later, the patient successfully underwent device replacement (smooth, round silicone) and experienced no further episodes of infection.

The third failure consisted of a 32-year-old woman with a history of bilateral immediate breast reconstruction with tissue expanders and acellular dermal matrix who presented with bilateral upper pole rippling following implant exchange. The patient underwent bilateral revision breast reconstruction with placement of acellular dermal matrix as overlay grafts (between capsule and skin flaps) and reinsertion of original devices (smooth, round silicone). One month postoperatively, the patient presented with erythema and wound drainage along the left reconstructed breast. This infection was managed by incision and drainage, débridement of 10 percent of the acellular dermal matrix that was nonadherent, and placement of a new device. Four months later, the patient presented with recurrent superolateral pole rippling of the left reconstructed breast. This was successfully managed with revision breast reconstruction, placement of acellular dermal matrix graft under tension from the lateral mammary fold to the capsule along the superolateral margin of the breast, and reinsertion of the original device.

## CASE REPORTS

### Correction of Capsular Contracture

A 44-year-old woman with a history of bilateral breast augmentation and left mastopexy performed at an outside hospital presented with recurrent right capsular contracture after four previous failed revisions (Fig. 5). To address this deformity, the patient underwent bilateral revision augmentation with right partial capsulectomy, partial subpectoral ("dual-plane") placement of smooth, round silicone implants [right, Allergan 15-265; left, Allergan 10-210 (Allergan, Inc., Irvine, Calif.)], and inseting of Strattice (8 × 16 cm, each) interpositional grafts using the reconstructive technique. Comparison of preoperative and 10-month postoperative photographs showed absence of breast distortion and preservation of a natural breast contour.

### Correction of Medial Malposition

A 39-year-old woman with a history of multiple bilateral breast augmentation-mastopexy procedures presented with symmastia (Fig. 6). To treat the deformity, neosubpectoral pockets were developed; implants were exchanged for smaller, smooth, round silicone implants (Allergan 20-350); and Strattice (8 × 8 cm, each) was placed using the symmastia technique over the pectoralis/capsule interface. Postoperative photographs demonstrated successful treatment of symmastia, which was maintained at 8-month follow-up.

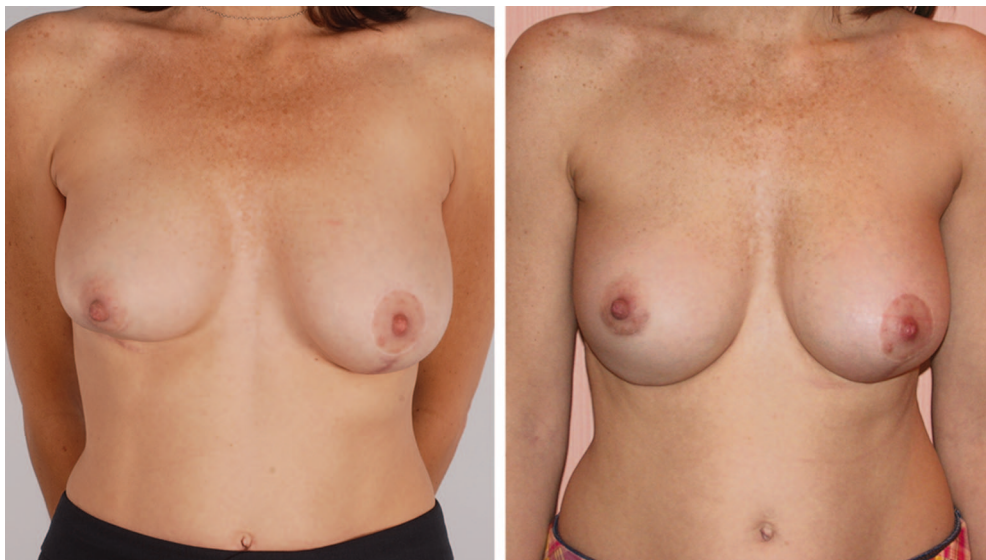### Correction of Rippling

A 21-year-old woman with a history of multiple breast augmentation procedures performed at an outside hospital

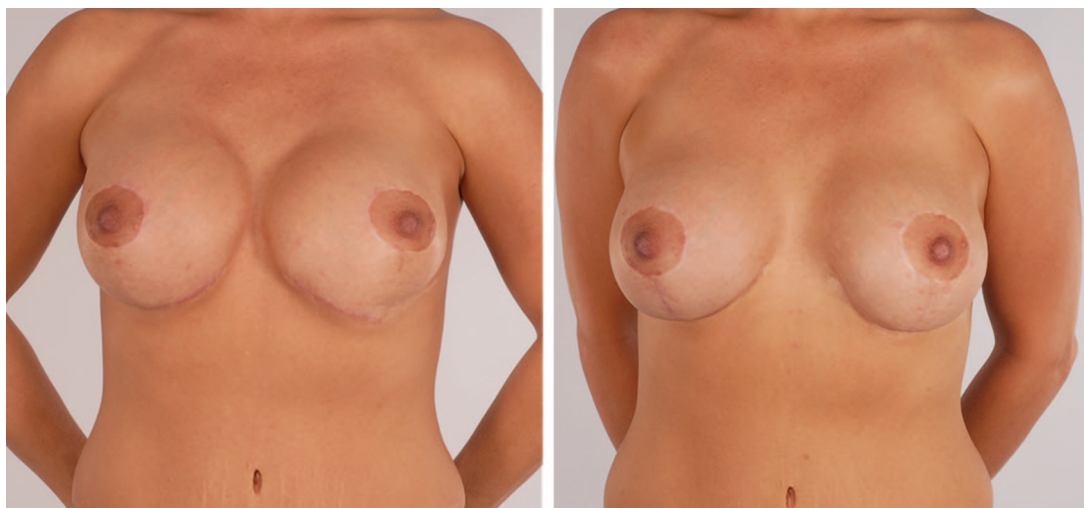**Table 4. Failure Rates following Acellular Dermal Matrix Use in the Treatment and Prevention of Implant-Related Breast Deformities**

| Indication                  | No. of Failed Breast Procedures (%) |
|-----------------------------|-------------------------------------|
| Malposition                 | 1/32 (3.1)                          |
| Rippling                    | 1/20 (5.0)                          |
| Capsular contracture        | 1/16 (6.3)                          |
| Skin flap deficiency        | 0/16 (0.0)                          |
| Prevention of bottoming-out | 0/6 (0.0)                           |
| Total                       | 3/77 (3.9)                          |





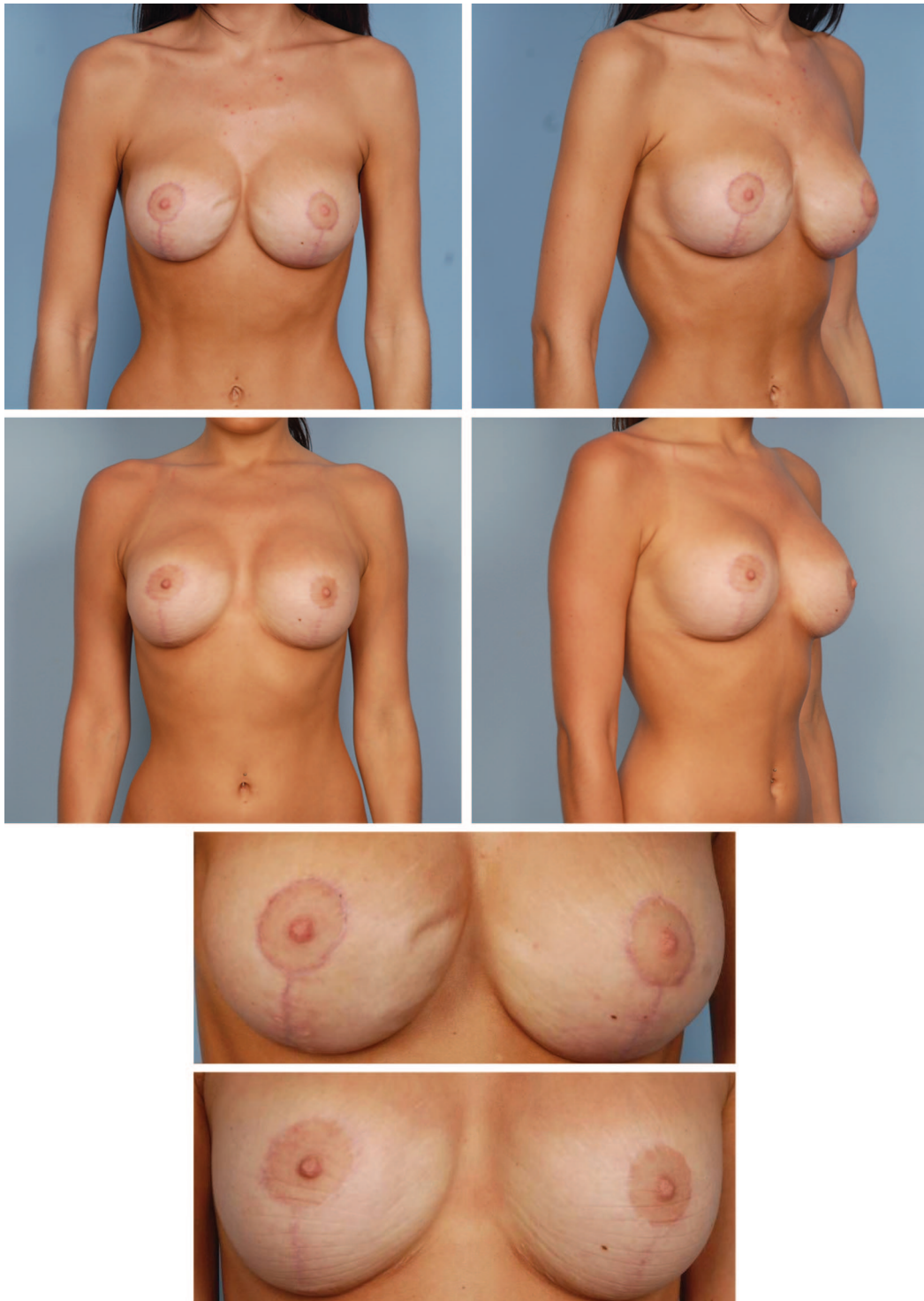
**Fig. 5.** (Left) Preoperative view of a 44-year-old patient displaying right capsular contracture following bilateral breast augmentation and left mastopexy at an outside hospital. The operative plan included bilateral revision augmentation with right partial capsulectomy; partial subpectoral (“dual-plane”) placement of smooth, round silicone implants (right, Allergan 15-265; left, Allergan 10-210); and inseting of Strattice ( $8 \times 16$  cm each) interpositional grafts using the reconstructive technique. (Right) The patient 10 months postoperatively, showing correction of capsular contracture and absence of breast distortion.



**Fig. 6.** (Left) Preoperative view of a 39-year-old female smoker with a history of multiple bilateral breast augmentation-mastopexy procedures presenting with symmastia. The operative plan included creation of neosubpectoral pockets; implant exchange for smaller, smooth, round silicone implants (Allergan 20-350); and Strattice ( $8 \times 8$  cm each) placement using the symmastia technique over the pectoralis/capsule interface. (Right) The patient at 8 months postoperatively, showing successful treatment of symmastia and stable implant location.

to address implant bottoming-out presented with bilateral breast implant rippling (Fig. 7). Operative steps to correct these deformities included medial capsulorrhaphies; replacement of the original smooth, round silicone implants (Allergan 10-300) in a new partial subpectoral pocket; and inseting of AlloDerm ( $4 \times 16$  cm each) both as an inter-

positional graft between the inferolateral edge of the pectoralis major muscle and the inframammary fold, and as an overlay graft between the capsule and the implant. Eighteen-month postoperative photographs showed no evidence of rippling or implant bottoming-out, with stable correction of implant deformities.



**Fig. 7.** Preoperative anteroposterior (*above, left*), oblique (*above, right*), and magnified (*second from below*) views of a 21-year-old patient displaying bilateral breast implant rippling after multiple subpectoral breast augmentation procedures performed at an outside hospital. Postoperative anteroposterior (*second row, left*), oblique (*second row, right*), and magnified (*below*) views obtained 18 months after bilateral revision augmentation with placement of original smooth, round silicone implants (Allergan 10-300) under a partial subpectoral pocket and inseting of AlloDerm as interpositional grafts between the inferolateral edge of the pectoralis major muscle and the inframammary fold and as overlay grafts between the capsule and implant. Note the correction of implant rippling and appropriate implant position.



### Prevention of Bottoming-Out

A 36-year-old woman with a history of active tobacco use and 100-lb weight loss following bariatric surgery presented for a bilateral breast augmentation-mastopexy procedure (Fig. 8). The patient underwent bilateral circumvertical mastopexies; partial subpectoral placement of smooth, round saline implants (Allergan 68MP, 330 cc filled); and placement of AlloDerm interpositional grafts between the pectoralis major muscle and the inframammary fold using the reconstructive technique. Comparison of preoperative and 9-month postoperative photographs demonstrates stable and appropriate device position, without signs of soft-tissue stretch or implant bottoming-out.

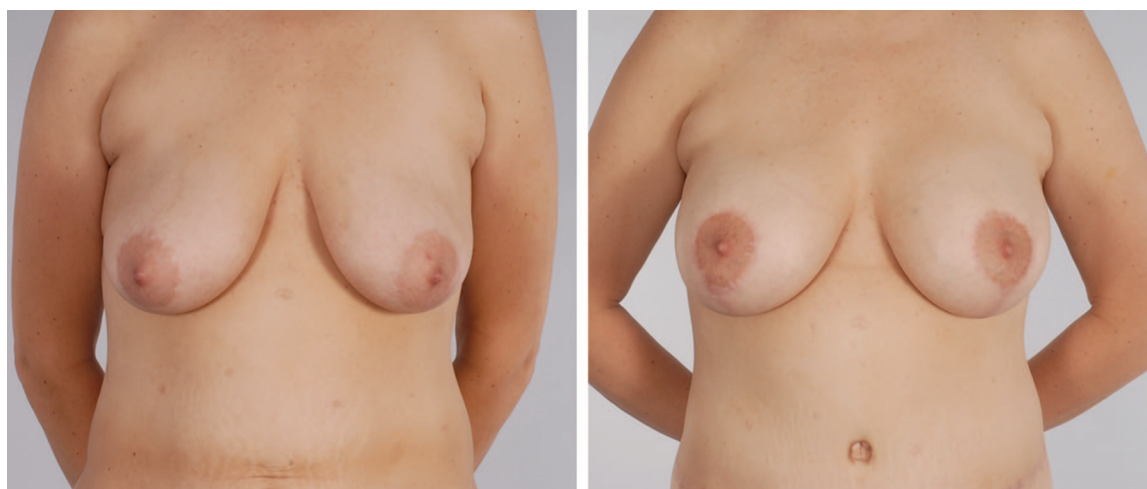### DISCUSSION

The treatment and prevention of implant-associated breast deformities, arising from capsular attenuation and contracture, remain significant challenges to the plastic surgeon. Capsular attenuation can manifest as implant malposition, bottoming-out, or rippling, whereas capsular contraction can be associated with implant firmness and/or distortion. In addition, implant placement can be complicated by surrounding soft-tissue thinning, putting the prosthesis at risk for threatened and/or actual exposure. Unfortunately, past techniques to address these various issues have not been highly predictable or durable.

Capsular contracture remains one of the most frequent complications and is the most common reason for reoperation following aesthetic and reconstructive prosthetic breast surgery.<sup>31,32</sup> Recently, the Inamed 6-year and Mentor 3-year silicone breast implant core studies

reported capsular contracture rates of 8.1 to 14.8 percent, 18.9 to 20.5 percent, 8.3 to 15.9 percent, and 16.3 percent for primary augmentation, revision augmentation, primary reconstruction, and revision reconstruction, respectively.<sup>31,32</sup> To address this problem, described techniques have included open capsulotomy,<sup>33–35</sup> partial/total capsulectomy,<sup>35–37</sup> implant exchange,<sup>38,39</sup> and implant site change.<sup>14,23,40,41</sup> Unfortunately, these techniques do not achieve 100 percent success and can produce unintended or unpredictable results, sometimes exchanging one implant deformity for another.<sup>35,36,42,43</sup> These techniques are even less effective in the setting of some more aggressive cases of capsule formation, such as early, rapid, or recurrent capsular contracture.<sup>23</sup>

Given that the cause of capsular contracture is likely multifactorial,<sup>44</sup> an interplay among subclinical infection, foreign body reaction, and local inflammation, we propose a multipronged treatment strategy. In an effort to maximize the likelihood of successfully correcting early or recurrent capsular contracture, we offer the option of executing all measures at the outset that may limit the likelihood of recurrence rather than waiting for recurrence to escalate the treatment plan. Therefore, we prefer to perform a capsulectomy, site change, implant exchange, and acellular dermal matrix interpositional placement between the pectoralis major muscle and chest wall all at the same setting. This is particularly true in patients



**Fig. 8.** (Left) Preoperative view of a 36-year-old patient with a history of active tobacco use and 100-lb weight loss following bariatric surgery who presented for bilateral breast augmentation-mastopexy. The operative plan included bilateral circumvertical mastopexies; partial subpectoral placement of smooth, round saline implants (Allergan 68MP, 330 cc filled); and placement of AlloDerm interpositional grafts between the pectoralis major muscle and the inframammary fold using the reconstructive technique. (Right) Patient's appearance 9 months postoperatively, with appropriate implant position and no sign of bottoming-out.

with recurrent contractures who have failed previous efforts. The capsulectomy, site change, and implant exchange all serve to limit the bacterial load in the operative region and maximally alter the tissue/implant milieu. Finally, interpositional placement of acellular dermal matrix between the pectoralis major muscle and chest wall serves to interrupt inflammation and capsule formation beyond the pectoralis major muscle's coverage of the implant, as confirmed by recent clinical and experimental studies.<sup>13,15,45</sup>

In our experience, the combination of these steps, including adding acellular dermal matrix, offers more predictable, consistent, and persistent results for the problem of capsular contracture that has been notoriously hard to predictably correct by other means. In our study, of 16 breasts with early/recurrent capsular contracture, there was only one failure (6.3 percent). Furthermore, we observed a low rate of unintended problems, with only one breast developing postoperative bottoming-out in the context of insufficient inferolateral support. In that one case, there was a deviation from the ideal technique because of an insufficient size of acellular dermal matrix.

Implant malposition has historically been difficult to correct with a high degree of certainty or longevity. Traditional methods have included the use of an adjustable implant<sup>25</sup>; capsulorrhaphy with or without mirror-image capsulotomy<sup>20,26,27</sup>; reinforcement with a capsular flap; site change to a subglandular, subpectoral, or neosubpectoral pocket<sup>30,40</sup>; and transcutaneous suturing.<sup>28</sup> These procedures are technically difficult and in many surgeons' hands unreliable and prone to recurrence.

In our experience, we reserve capsulorrhaphy for simple fold adjustments at the inframammary fold. For more challenging and complex malposition, we perform site change sometimes with the use of a neosubpectoral pocket. In instances of recurrent malposition with poorer quality tissues, we recommend combining acellular dermal matrix with capsulorrhaphy repair and/or a neosubpectoral pocket. In our opinion, this provides added assurance in reducing the likelihood of relapse by supporting the fold repair, offloading tension on the capsulorrhaphy suture line, and shielding the implant from entering the old space. Indeed, our study attests to the efficacy of acellular dermal matrix for this purpose, with failure in only one of 32 breasts (3.1 percent).

Rippling is another implant-related problem that has challenged plastic surgeons. Visible rippling typically affects the superomedial quadrant of the breast and is most evident in the

upright, leaning-forward position. In contrast, palpable rippling usually presents in the inferolateral or inferior aspect of the breast. To address these problems, known techniques have included changing to a smooth, silicone implant; site change to a subpectoral pocket; capsulorrhaphy to decrease the pocket size; and the use of autogenous tissues such as fat, fascia, scar tissue, capsule, or major muscle.<sup>21,22,24,46</sup> In our experience, device change from a saline or textured implant to a smooth silicone implant may help correct both visible and palpable rippling. In contrast, site change to a subpectoral pocket can help visible but not inferolateral palpable rippling. Overall, these methods are not universally successful or predictable, especially in situations with thin or poor-quality local tissue. Furthermore, we have not found our experience with lipoinfiltration for camouflaging rippling to be compelling.

We have been encouraged by our experience with acellular dermal matrix placement for the treatment of rippling instead of isolated device exchange, site change, capsulorrhaphy, or autogenous tissue placement. As an interpositional graft between the pectoralis major muscle and chest wall, acellular dermal matrix provides inferolateral support of the implant and prevents its downward descent and subsequent visible rippling. As an overlay graft, acellular dermal matrix can re-tailor the implant space to prevent descent and subsequent visible rippling and can reinforce thin capsular flaps to minimize palpable rippling. Indeed, results of this study attest to the efficacy of acellular dermal matrix, with failure occurring in only one of 20 breasts (5.0 percent).

Breast skin envelope thinning also remains difficult to correct with a high degree of certainty or longevity. Traditional methods have included the use of autogenous tissues such as fat, fascia, scar tissue, capsule, or major muscle.<sup>47-49</sup> Overall, these methods are not universally successful or predictable. In our experience, we recommend acellular dermal matrix as an overlay graft to reinforce areas of capsular thinning. In our study, there were no failures among the 16 breasts with skin flap deficiency.

There may be a role for acellular dermal matrix in primary aesthetic breast implant surgery in the massive weight loss patient, where we recommend acellular dermal matrix to prevent loss of inframammary fold definition and bottoming-out. Given that implant bottoming-out can be a difficult problem to correct, we have offered a preemptive strategy in those patients at highest risk for postoperative stretch deformities. As an interpositional graft be-

tween the pectoralis major muscle and chest wall, acellular dermal matrix may provide inferolateral support and protect the overlying tissues from the weight of the implant. In this study, we had no occurrences of implant bottoming-out in six post-bariatric surgery breasts receiving preemptive acellular dermal matrix.

In addition to supporting the efficacy of acellular dermal matrix, this study also points to the safety of acellular dermal matrix use in revisionary prosthetic breast surgery. Among the 43 aesthetic breast cases, complication rates were low, with one event each of hematoma and infection with device explantation. Equally low rates were observed for 34 reconstructed breasts, with an 11.8 percent overall complication rate that included three mild infections and one seroma.

This study provides evidence for broader applications for acellular dermal matrix, but it does have some shortcomings. The short average length of follow-up (8.6 months) may have underestimated the rate of relapse and revisions. In addition, the small study population (77 breasts) may have underpowered the analysis. This information, though early, is important for beginning to understand how the emerging technology of acellular dermal matrix works. Indeed, the senior author (S.L.S.) has placed acellular dermal matrix in an additional 37 patients with implant-related deformities since preparation of this article and has noted continued satisfactory results.

## CONCLUSIONS

The management and prevention of implant-associated breast deformities remain difficult challenges. Prior techniques have not been universally reliable or predictable. Based on experience with 77 breasts, acellular dermal matrix has shown promise in treating and preventing capsular contracture, rippling, implant malposition, and soft-tissue thinning.

**Scott L. Spear, M.D.**

Georgetown University Hospital  
3800 Reservoir Road, N.W.  
PHC Building, First Floor  
Washington, D.C. 20007  
spears@gunet.georgetown.edu

## REFERENCES

1. Breuing KH, Warren SM. Immediate bilateral breast reconstruction with implants and inferolateral AlloDerm slings. *Ann Plast Surg.* 2005;55:232–239.
2. Gamboa-Bobadilla GM. Implant breast reconstruction using acellular dermal matrix. *Ann Plast Surg.* 2006;56:22–25.
3. Salzberg CA. Nonexpansive immediate breast reconstruction using human acellular tissue matrix graft (AlloDerm). *Ann Plast Surg.* 2006;57:1–5.
4. Bindingnavale V, Gaon M, Ota KS, Kulber DA, Lee DJ. Use of acellular cadaveric dermis and tissue expansion in post-mastectomy breast reconstruction. *J Plast Reconstr Aesthet Surg.* 2007;60:1214–1218.
5. Breuing KH, Colwell AS. Inferolateral AlloDerm hammock for implant coverage in breast reconstruction. *Ann Plast Surg.* 2007;59:250–255.
6. Zienowicz RJ, Karacaoglu E. Implant-based breast reconstruction with allograft. *Plast Reconstr Surg.* 2007;120:373–381.
7. Preminger BA, McCarthy CM, Hu QY, Mehrara BJ, Disa JJ. The influence of AlloDerm on expander dynamics and complications in the setting of immediate tissue expander/implant reconstruction: A matched-cohort study. *Ann Plast Surg.* 2008;60:510–513.
8. Spear SL, Parikh PM, Reisin E, Menon NG. Acellular dermis-assisted breast reconstruction. *Aesthetic Plast Surg.* 2008;32:418–425.
9. Topol BM, Dalton EF, Ponn T, Campbell CJ. Immediate single-stage breast reconstruction using implants and human acellular dermal tissue matrix with adjustment of the lower pole of the breast to reduce unwanted lift. *Ann Plast Surg.* 2008;61:494–499.
10. Becker S, Saint-Cyr M, Wong C, et al. AlloDerm versus DermaMatrix in immediate expander-based breast reconstruction: A preliminary comparison of complication profiles and material compliance. *Plast Reconstr Surg.* 2009;123:1–6; discussion 107–108.
11. Losken A. Early results using sterilized acellular human dermis (Neoform) in post-mastectomy tissue expander breast reconstruction. *Plast Reconstr Surg.* 2009;123:1654–1658.
12. Chun YS, Verma K, Rosen H, et al. Implant-based breast reconstruction using acellular dermal matrix and the risk of postoperative complications. *Plast Reconstr Surg.* 2010;125:429–436.
13. Komorowska-Timek E, Oberg KC, Timek TA, Gridley DS, Miles DA. The effect of AlloDerm envelopes on periprosthetic capsule formation with and without radiation. *Plast Reconstr Surg.* 2009;123:807–816.
14. Mofid MM, Singh NK. Pocket conversion made easy: A simple technique using AlloDerm to convert subglandular breast implants to the dual-plane position. *Aesthet Surg J.* 2009;29:12–18.
15. Stump A, Holton LH III, Connor J, et al. The use of acellular dermal matrix to prevent capsular formation around implants in a primate model. Paper presented at: 25th Annual Meeting of the Northeastern Society of Plastic Surgeons; October 2–5, 2008; Philadelphia, Pa.
16. Duncan DI. Correction of implant rippling using allograft dermis. *Aesthet Surg J.* 2001;21:81–84.
17. Baxter RA. Intracapsular allogenic dermal grafts for breast implant-related problems. *Plast Reconstr Surg.* 2003;112:1692–1696; discussion 1697–1698.
18. Sultan M, Smith M, Samson W. The correction of significant post augmentation boundary deformities with capsulorrhaphy and AlloDerm. Paper presented at: 25th Annual Meeting of the Northeastern Society of Plastic Surgeons; October 2–5, 2008; Philadelphia, Pa.
19. Maxwell GP, Gabriel A. Use of the acellular dermal matrix in revisionary aesthetic breast surgery. *Aesthet Surg J.* 2009;29:485–493.
20. Spear SL, Little JW III. Breast capsulorrhaphy. *Plast Reconstr Surg.* 1988;81:274–279.
21. Collis N, Platt AJ, Batchelor AG. Pectoralis major “trapdoor” flap for silicone breast implant medial knuckle deformities. *Plast Reconstr Surg.* 2001;108:2133–2135; discussion 2136.



22. Massiha H. Scar tissue flaps for the correction of postimplant breast rippling. *Ann Plast Surg.* 2002;48:505–507.
23. Spear SL, Carter ME, Ganz JC. The correction of capsular contracture by conversion to “dual-plane” positioning: Technique and outcomes. *Plast Reconstr Surg.* 2003;112:456–466.
24. McGregor JC, Bahia H. A possible new way of managing breast implant rippling using an autogenous fascia lata patch. *Br J Plast Surg.* 2004;57:372–374.
25. Becker H, Shaw KE, Kara M. Correction of symmastia using an adjustable implant. *Plast Reconstr Surg.* 2005;115:2124–2126.
26. Chasan PE. Breast capsulorrhaphy revisited: A simple technique for complex problems. *Plast Reconstr Surg.* 2005;115:296–301; discussion 302–303.
27. Chasan PE, Francis CS. Capsulorrhaphy for revisionary breast surgery. *Aesthet Surg J.* 2008;28:63–69.
28. Foustanos A, Zavrides H. Surgical reconstruction of iatrogenic symmastia. *Plast Reconstr Surg.* 2008;121:143e–144e.
29. Bengtson BP, Salzberg CA, Spear SL. *Strattice Technique Guide.* Branchburg, N.J.: LifeCell Corp.; 2009.
30. Spear SL, Dayan JH, Bogue D, et al. The “neosubpectoral” pocket for the correction of symmastia. *Plast Reconstr Surg.* 2009;124:695–703.
31. Cunningham B. The Mentor Core Study on Silicone MemoryGel Breast Implants. *Plast Reconstr Surg.* 2007;120:19S–29S; discussion 30S–32S.
32. Spear SL, Murphy DK, Slicton A, Walker PS; Inamed Silicone Breast Implant U.S. Study Group. Inamed silicone breast implant core study results at 6 years. *Plast Reconstr Surg.* 2007;120(Suppl 1):8S–16S; discussion 17S–18S.
33. Burkhardt BR, Fried M, Schnur PL, Toffield JJ. Capsules, infection, and intraluminal antibiotics. *Plast Reconstr Surg.* 1981;68:43–49.
34. Freeman BS. Successful treatment of some fibrous envelope contractures around breast implants. *Plast Reconstr Surg.* 1972;50:107–113.
35. Hipps CJ, Raju R, Straith RE. Influence of some operative and postoperative factors on capsular contracture around breast prostheses. *Plast Reconstr Surg.* 1978;61:384–389.
36. Collis N, Sharpe DT. Recurrence of subglandular breast implant capsular contracture: Anterior versus total capsulectomy. *Plast Reconstr Surg.* 2000;106:792–797.
37. Young VL. Guidelines and indications for breast implant capsulectomy. *Plast Reconstr Surg.* 1998;102:884–891; discussion 892–894.
38. Melmed EP. Treatment of breast contractures with open capsulotomy and replacement of gel prostheses with polyurethane-covered implants. *Plast Reconstr Surg.* 1990;86:270–274.
39. Mladick RA. Treatment of the firm augmented breast by capsular stripping and inflatable implant exchange. *Plast Reconstr Surg.* 1977;60:720–724.
40. Maxwell GP, Birchenough SA, Gabriel A. Efficacy of neospectoral pocket in revisionary breast surgery. *Aesthet Surg J.* 2009;29:379–385.
41. Tebbetts JB. Dual plane breast augmentation: Optimizing implant-soft-tissue relationships in a wide range of breast types. *Plast Reconstr Surg.* 2001;107:1255–1272.
42. Burkhardt BR. Capsular contracture: Hard breasts, soft data. *Clin Plast Surg.* 1988;15:521–532.
43. Embrey M, Adams EE, Cunningham B, Peters W, Young VL, Carlo GL. A review of the literature on the etiology of capsular contracture and a pilot study to determine the outcome of capsular contracture interventions. *Aesthetic Plast Surg.* 1999;23:197–206.
44. Adams WP Jr. Capsular contracture: What is it? What causes it? How can it be prevented and managed? *Clin Plast Surg.* 2009;36:119–126, vii.
45. Basu CB, Leong M, Hicks MJ. Does acellular cadaveric dermis (ACD) affect breast implant capsule formation in reconstructive breast surgery? A histopathologic comparison of breast capsule and ACD. *Plast Reconstr Surg.* 2009;124:62–63.
46. Spear SL, Wilson HB, Lockwood MD. Fat injection to correct contour deformities in the reconstructed breast. *Plast Reconstr Surg.* 2005;116:1300–1305.
47. Panettiè P, Marchetti L, Accorsi D. The serial free fat transfer in irradiated prosthetic breast reconstructions. *Aesthetic Plast Surg.* 2009;33:695–700.
48. Codner MA, Cohen AT, Hester TR. Complications in breast augmentation: Prevention and correction. *Clin Plast Surg.* 2001;28:587–595; discussion 596.
49. Brandstetter M, Schoeller T, Püzl P, Schubert H, Wechselberger G. Capsular flap for coverage of an exposed implant after skin-sparing mastectomy and immediate breast reconstruction. *J Plast Reconstr Aesthet Surg.* 2010;63:1388–1390.